

# The American Association of Endocrine Surgeons Guidelines for the Definitive Surgical Management of Thyroid Disease in Adults

Kepal N. Patel, MD,\*✉ Linwah Yip, MD,† Carrie C. Lubitz, MD, MPH,‡ Elizabeth G. Grubbs, MD,§  
Barbra S. Miller, MD,¶|| Wen Shen, MD,|| Peter Angelos, MD,\*\* Herbert Chen, MD,††  
Gerard M. Doherty, MD,‡‡ Thomas J. Fahey III, MD,§§ Electron Kebebew, MD,¶¶ Virginia A. Livolsi, MD,|||  
Nancy D. Perrier, MD,§ Jennifer A. Sipos, MD,\*\*\* Julie A. Sosa, MD,|| David Steward, MD,†††  
Ralph P. Tufano, MD,‡‡‡ Christopher R. McHenry, MD,§§§ and Sally E. Carty, MD†

**Objective:** To develop evidence-based recommendations for safe, effective, and appropriate thyroidectomy.

**Background:** Surgical management of thyroid disease has evolved considerably over several decades leading to variability in rendered care. Over 100,000 thyroid operations are performed annually in the US.

**Methods:** The medical literature from 1/1/1985 to 11/9/2018 was reviewed by a panel of 19 experts in thyroid disorders representing multiple disciplines. The authors used the best available evidence to construct surgical management recommendations. Levels of evidence were determined using the American College of Physicians grading system, and management recommendations were discussed to consensus. Members of the American Association of Endocrine Surgeons reviewed and commented on preliminary drafts of the content.

**Results:** These clinical guidelines analyze the indications for thyroidectomy as well as its definitions, technique, morbidity, and outcomes. Specific topics include Pathogenesis and Epidemiology, Initial Evaluation, Imaging, Fine Needle Aspiration Biopsy Diagnosis, Molecular Testing, Indications, Extent and Outcomes of Surgery, Preoperative Care, Initial Thyroidectomy, Perioperative Tissue Diagnosis, Nodal Dissection, Concurrent Parathyroidectomy, Hyperthyroid Conditions, Goiter, Adjuncts and Approaches to Thyroidectomy, Laryngology, Familial Thyroid Cancer, Postoperative Care and Complications, Cancer Management, and Reoperation.

**Conclusions:** Evidence-based guidelines were created to assist clinicians in the optimal surgical management of thyroid disease.

**Keywords:** biopsy, cancer, carcinoma, concurrent parathyroidectomy, diagnosis, endocrine, extent of resection, goiter, hyperthyroidism, imaging, lymph nodes, management and complications, molecular markers, nodules, pathogenesis, poorly differentiated thyroid carcinoma, postoperative care, preoperative care, staging, surgery, thyroid, thyroidectomy indications, ultrasound

(*Ann Surg* 2020;271:e21–e93)

TABLE OF CONTENTS	PAGES
1. Introduction	e23
2. Methods	e23–e24
a. Literature Evidence	
b. Conflict of Interest (COI)	
c. Grading of Practice Recommendations	
d. AAES Member Input and Sister Society Endorsement	
e. Cautions to Implementation	
3. Pathogenesis and Epidemiology	e24–e26
a. Thyroid Dysfunction	
b. Benign Thyroid Nodules	
c. Lesions of Indeterminate Malignant Potential	
d. Thyroid Cancer	
e. Primary Thyroid Lymphoma	
4. Initial Evaluation	e26–e30

From the \*Division of Endocrine Surgery, NYU Langone Health, New York, NY; †Department of Surgery, University of Pittsburgh School of Medicine, Pittsburgh, PA; ‡Department of Surgery, Massachusetts General Hospital, Boston, MA; §Department of Surgical Oncology, University of Texas MD Anderson Cancer Center, Houston, TX; ¶Division of Endocrine Surgery, University of Michigan, Ann Arbor, MI; ||Department of Surgery, University of California San Francisco, San Francisco, CA; \*\*Department of Surgery and MacLean Center for Clinical Medical Ethics, The University of Chicago, Chicago, IL; ††Department of Surgery, University of Alabama at Birmingham, Birmingham, AL; ‡‡Department of Surgery, Brigham and Women's Hospital, Boston, MA; §§Department of Surgery, The New York Presbyterian Hospital-Weill Cornell Medical Center, New York, NY; ¶¶Department of Surgery and Stanford Cancer Institute, Stanford University, Stanford, CA; |||Department of Pathology and Laboratory Medicine, Perelman School of Medicine of University of Pennsylvania, Philadelphia, PA; \*\*\*Division of Endocrinology and Metabolism, The Ohio State University, Columbus, OH; †††Department of Otolaryngology, University of Cincinnati College of Medicine, Cincinnati, OH; ‡‡‡Division of Head and Neck Endocrine Surgery, Department of Otolaryngology-Head and Neck Surgery, The Johns Hopkins School of Medicine, Baltimore, MD; and §§§MetroHealth Medical Center, Case Western Reserve University School of Medicine, Cleveland, OH.

✉kepal.patel@nyumc.org

The Executive Summary of these guidelines can be found here: 10.1097/SLA.0000000000003735.

S.E.C. and C.R.M. directed the project and coordinated the authors and topics. S.E.C., C.R.M., and K.N.P. developed the methodology, managed disclosures, and prepared the work for publication. C.C.L., E.G.G., B.S.M., K.N.P., W.T.S., and L.Y. carried out the systematic topic reviews and were the primary authors of text. All authors participated directly in editing the text and recommendations. AAES legal counsel approved the language in the section, *Cautions to Implementation*.

All authors received no funding for this work and declare that neither they nor their institutions received payment or support in kind for any aspect of this work (including grants, data monitoring board, study design, manuscript preparation, statistical analysis).

As defined in Appendix A, relevant COI is listed for all authors:

D.S. has received research support from Astra Zeneca, Veracyte and Gene-ProDx.

K.N.P. has received honoraria for educational programming from Veracyte.

J.A. Sipos has received research support and honoraria from UPMC/Thyrosseq and Genzyme/Sanofi.

P.A. has received research funding from Olympus-Gyrus.

R.P.T. has served as a consultant for Medtronic and Hemostatix.

V.A.L. has served as a consultant for Veracyte.

The authors report no conflicts of interest.

Copyright © 2020 Wolters Kluwer Health, Inc. All rights reserved.

ISSN: 0003-4932/20/27103-0e21

DOI: 10.1097/SLA.0000000000003580

- a. History
  - i. Ionizing radiation
  - ii. Syndromic TC
  - iii. Clinical Characteristics
- b. Physical Examination
- c. Voice Assessment
- d. Laboratory Evaluation
- 5. Imaging e30–e32
  - a. Preoperative
    - i. Ultrasonography
      - 1. Thyroid nodule US
      - 2. Parathyroid incidentaloma US
      - 3. Cervical lymph node US
      - 4. LN mapping
      - 5. Surgical planning
      - 6. Translaryngeal US
      - 7. US limitations
    - ii. Cross-sectional imaging
    - iii. Elastography
    - iv. PET/CT
    - v. Imaging for hyperthyroid conditions
  - b. Postoperative
    - i. Functional Imaging for TC metastases
- 6. Fine Needle Aspiration Biopsy (FNAB) Diagnosis e32–e35
  - a. FNAB Indications
  - b. Indications for FNAB of Cervical Lymph Nodes
  - c. Pre-FNAB Considerations
  - d. FNAB Technique
  - e. FNAB Result Categories
- 7. Molecular Testing e35–e38
  - a. MT to Guide Need for Surgery
  - b. MT to Guide Thyroid Nodule Management
  - c. MT to Guide Extent of Surgery
  - d. Practical Aspects of MT
  - e. Concerns with MT
- 8. Indications, Extent, and Outcomes of Surgery e38–e40
  - a. Extent of Initial Thyroidectomy
  - b. Cytologically Benign Nodules
  - c. Goiter and Thyroiditis
  - d. Hyperthyroidism
  - e. Cytologically Malignant Nodules
  - f. Cytologically Indeterminate Nodules
  - g. Other Situations
  - h. Outcomes of Thyroidectomy
- 9. Preoperative Care e40–e42
  - a. Antibiotics
  - b. Steroids
  - c. Surgical Preparation for Graves' Disease and Hyperthyroidism
  - d. Vitamin D and Calcium
  - e. Universal/Standard Consent and Counseling
  - f. Venous Thromboembolism (VTE) Prophylaxis
  - g. Interdisciplinary Communication
- 10. Initial Thyroidectomy e42–e44
  - a. Nomenclature
  - b. Surgical Planning
  - c. Positioning, Incision, and Exposure
  - d. Critical Steps of Thyroid Dissection
  - e. Additional Considerations in Thyroidectomy for Cancer
- 11. Perioperative Tissue Diagnosis e44–e47
  - a. Core Needle Biopsy of the Thyroid and Cervical Lymph Nodes
  - b. Incisional Biopsy of the Thyroid and Incisional/Excisional Biopsy of Cervical Lymph Nodes
  - c. Intraoperative Pathologic Evaluation of the Thyroid
  - d. Intraoperative Pathologic Evaluation of CLN and Parathyroid Tissue
  - e. Final Histopathologic Diagnosis
  - f. Benign Lesions of the Thyroid
  - g. Differentiated Thyroid Carcinoma
  - h. Neoplasms of Uncertain Malignant Potential
  - i. Poorly Differentiated Thyroid Carcinoma
  - j. Anaplastic Thyroid Carcinoma
  - k. Medullary Thyroid Carcinoma
  - l. Thyroid Paraganglioma
  - 12. Nodal Dissection e47–e50
    - a. Central Compartment ND
    - b. Lateral Compartment ND
    - c. Prognostic Implications of LNM
  - 13. Concurrent Parathyroidectomy e50–e51
    - a. Epidemiology and Evaluation
    - b. Indications for Concurrent Parathyroidectomy
    - c. Special Situations
  - 14. Hyperthyroid Conditions e51–e54
    - a. Medical Treatment
    - b. Surgical Treatment
    - c. Graves' Ophthalmopathy
    - d. When to Start Thyroid Hormone
    - e. Surgical Complications in Hyperthyroidism
    - f. The Hyperthyroid Pregnant Patient
  - 15. Goiter e54–e56
    - a. Indications for Resection
    - b. Nonsurgical Treatment
    - c. Extent and Conduct of Resection
    - d. Diagnosis and Preoperative Management
    - e. Intraoperative Management
  - 16. Adjuncts and Approaches e56–e58
    - a. Energy-based Vessel-sealing Devices
    - b. Intraoperative Assessment of Nerve Function
    - c. Rapid Parathyroid Hormone Testing
    - d. Intraoperative Tissue Analysis
    - e. Remote-Access Approaches
    - f. Hemostatic Agents
  - 17. Laryngology e58–e60
    - a. Preoperative Evaluation
    - b. Intraoperative Events
    - c. Postoperative VFD Care
  - 18. Familial Thyroid Cancer e60–e62
    - a. Genetic Testing
    - b. Hereditary Nonmedullary TC
      - i. Nonsyndromic Familial Nonmedullary TC (NFMNMTTC)
      - ii. Syndromic FNMTC
        - 1. Familial Adenomatous Polyposis
        - 2. Cowden Syndrome
        - 3. Carney Complex
        - 4. Werner Syndrome
        - 5. DICER1 Syndrome
        - 6. Papillary Renal Neoplasia
        - 7. McCune-Albright Syndrome
        - 8. CHEK2
    - c. Hereditary MTC
  - 19. Postoperative Care and Complications e62–e66
    - a. Routine Management
      - i. Documentation/Communication
      - ii. Incision Care
      - iii. Medications
      - iv. Pain Management
    - b. Immediate Complications

i. Hematoma	
ii. Recurrent Laryngeal Nerve Dysfunction	
iii. Calcium Supplementation, Hypocalcemia, and Hypoparathyroidism	
c. Rare Complications	
20. Cancer Management	e66–e69
a. Active Surveillance	
b. Postoperative Risk Assessment	
c. Prognostic Variables	
d. Completion Thyroidectomy	
e. Postoperative Treatment	
21. Reoperation	e69–e71
a. Indications	
b. Preoperative Management	
c. Risks	
i. Operative Approach	
22. Concluding Remarks/Acknowledgements	e71

Thyroidectomy, a term used herein to include any type of thyroid surgery, is a common procedure in the US, with >100,000 thyroidectomies performed every year.<sup>1,2</sup> Recent advances in the diagnosis and management of benign and malignant thyroid disease have emphasized algorithmic, personalized, and evidence-based care. Surgical indications and treatment paradigms also have undergone extensive change, particularly with the addition of new cytologic and pathologic diagnostic criteria, molecular profiling tests, operative techniques, and adjuncts. However, such transformations have propagated differences in clinical interpretation and management, and as a result, clinical uncertainty and even controversy have emerged.

Recognizing the importance of these changes, the American Association of Endocrine Surgeons (AAES) determined that evidence-based clinical guidelines were necessary to enhance the safe and effective surgical treatment of benign and malignant thyroid disease, and convened a multidisciplinary panel with representation from the disciplines of endocrinology, pathology, and surgery to supply a broad update for all involved clinicians. The guidelines specifically aim to:

1. Help surgical caregivers and their team members understand relevant aspects of the epidemiology and pathogenesis of thyroid disease.
2. Describe the succinct diagnosis of thyroid disease using laboratory studies, molecular profiling, and clinical findings (both subjective and objective).
3. Define the indications for surgical intervention and the appropriate extent and conduct of surgery.
4. Detail methods for safe and effective perioperative management, including complications.
5. Analyze the optimal management of thyroid cancer based on a personalized approach.

The presentation, diagnosis, and management of thyroid nodules and thyroid cancer have been addressed by several national and international organizations.<sup>3–5</sup> The guidelines presented here focus on surgical management in adults (age >18 yrs) and include the most current information with the goal of achieving definitive surgical treatment of thyroid disease as safely and efficiently as possible.

## METHODS

In August 2016, AAES leadership approved the development of clinical practice guidelines for optimal adult thyroid surgery. A

multidisciplinary writing group was assembled with broad-based expertise in endocrinology, pathology, and surgery, and the major topics and questions were identified.

Using methods similar to those of the recent AAES Parathyroidectomy Guidelines,<sup>6</sup> the authors applied a systematic process of assessing the quality of evidence, drafting the text and recommendations supported by that evidence, and amending the material in discussion to reach consensus. In brief, a 4 to 8-person topic subcommittee was appointed for each section based on relevant expertise, was led by a primary author (C.C.L., E.G.G., B.J.M., K.N.P., W.T.S., or L.Y.), and included multiple authors. The subcommittees reviewed the evidence to prepare draft text that was then discussed in detail by the entire group during monthly teleconferences and via email from September 2016 to March 2019. Editing for organization and to eliminate redundancy was performed by all authors and particularly by K.N.P., C.R.M., C.C.L., and S.E.C. Commonly used abbreviations appear in Table 1.

## Literature Evidence

Search parameters for the medical literature were set from January 1, 1985 to November 9, 2018. At the authors' discretion, this time frame was extended back to allow for inclusion of landmark articles that offered historical perspective or to illustrate time-tested principles. For each topic, the primary coauthor conducted a PubMed Medical Subject Heading search using Boolean logic for relevant search terms. Limitations were applied to select publications containing an abstract (English Language) and appearing in abridged index medicus (AIM), otherwise known as core clinical journals in PubMed.

## Conflict of Interest (COI)

The cochairs (S.E.C., C.R.M.) were required to have no COI. Working with the AAES President, the cochairs developed and instituted a detailed COI policy that was applied before and throughout the writing process (Appendix A). Standard definitions were utilized, and in policy development we also gratefully acknowledge the leadership of the American Thyroid Association (ATA).<sup>7</sup> Authors were required to declare COI at the project's inception and every 6 months thereafter, which was reviewed for relevance by the senior authors. When COI was present, that author was recused from participation in all writing, discussion, and editing of the topic. Topic subcommittee members were required to have zero COI. COI was otherwise present for 6/19 authors (32%) (4 for FNA Diagnosis, 2 for Adjuncts and Approaches, 2 for Cancer Management.)

## Grading of Practice Recommendations

The 2010 American College of Physicians (ACP) grading system, which employs a validated scale to critically interpret and evaluate the strength and quality of the evidence and provide guidance on how to best apply the recommendation to individual patients,<sup>8</sup> was utilized in manuscript preparation. The American College of Physicians system applies the terms “Strong” when benefits clearly outweigh risks and/or the recommendation should be applied to all or most patients without reservation, “Weak” when benefits are finely balanced with risks or appreciable uncertainty exists, and “Insufficient” when the evidence to support a recommendation is conflicting, lacking, or of poor quality; in these circumstances, the authors provided opinion based on expert interpretation of the available data. The quality of the evidence was graded “High” for well-done randomized controlled trials or overwhelming evidence, “Moderate” for randomized controlled trials with important limitations, well-designed cohort or case-control studies, or large observational studies, and “Low” for potentially biased, small observational, or case studies.<sup>8</sup>

**TABLE 1. Abbreviations**

AAES	American Association of Endocrine Surgeons
ACP	American College of Physicians
ACR	American College of Radiology
AS	active surveillance
ATA	American Thyroid Association
BII	Bethesda 2
BIII	Bethesda 3
BIV	Bethesda 4
BV	Bethesda 5
CHRPE	Congenital hypertrophy of the retinal pigment epithelium
CLN	Cervical lymph node
CLNM	Cervical lymph node metastasis
CNC	Carney complex
CND	Central compartment nodal dissection
CS	Cowden syndrome
CXR	Chest x-ray
DS	DICER1 syndrome
DTC	Differentiated thyroid cancer
EBRT	External beam radiation therapy
EBSLN	External branch of the superior laryngeal nerve
ETE	Extrathyroidal extension
FA	Follicular adenoma
FAP	Familial adenomatous polyposis
FDA	Food and Drug Administration
FFPE	Formalin fixed paraffin embedded
FNAB	Fine needle aspiration biopsy
FNMTCT	Familial non-medullary thyroid cancer
FTC	Follicular thyroid cancer
FVPTC	Follicular variant of papillary thyroid cancer
GD	Graves' disease
HCTC	Hürthle cell carcinoma
IOPE	Intraoperative pathologic examination
IPM	Intraoperative parathyroid hormone monitoring
LND	Lateral neck dissection
LT	Laryngeal twitch
MNG	Multinodular goiter
MTC	Medullary thyroid cancer
ND	Neck dissection
NIFTP	Noninvasive follicular thyroid neoplasm with papillary-like features
NISQIP	National surgical quality improvement program
NPV	Negative predictive value
PDTC/ATC	Poorly differentiated/anaplastic thyroid cancer
pHPT	Primary hyperparathyroidism
PPV	Positive predictive value
PTC	Papillary thyroid cancer
PTH	Parathyroid hormone
PTL	Primary thyroid lymphoma
PTMC	Papillary thyroid microcarcinoma
PTU	Propylthiouracil
RAI	Radioactive iodine
RCT	Randomized controlled trial
RLN	Recurrent laryngeal nerve
RLNM	Recurrent laryngeal nerve monitoring
SLN	Superior laryngeal nerve
T3	Triiodothyronine
TA	Toxic Adenoma
TC	Thyroid cancer
Tg	Thyroglobulin
TI-RADS	Thyroid imaging reporting and data system
TMNG	Toxic multinodular goiter
TSH	Thyroid stimulating hormone
TSH-R	TSH receptor
U.S.	United States
US	Ultrasound
VFD	Vocal fold dysfunction
WDT-UMP	Well differentiated thyroid cancer of unknown malignant potential
WHO	World health organization
WS	Werner syndrome

AMP indicates antimicrobial prophylaxis. BMI, body mass index; CNB, core needle biopsy; FL, fiberoptic laryngoscopy; FSA, frozen section analysis; FVPTC, follicular variant PTC; GO, Graves ophthalmopathy; HA, Hürthle cell adenoma; IOPE, intraoperative pathologic evaluation; MT, molecular testing; PONV, postoperative nausea and vomiting; PTC, papillary thyroid cancer; TT, total thyroidectomy; XRT, ionizing radiation.

## AAES Member Input and Sister Society Endorsement

Productive feedback and suggestions from all sources were discussed in detail, and consensus revisions were made as required, including comments received after oral presentation of progress at the 2018 national AAES meeting, and after solicitation of feedback from AAES membership in November 2018. The document was reviewed and endorsed by the Society of Surgical Oncology, the International Association of Endocrine Surgeons, the American Thyroid Association, and the Graves' Disease and Thyroid Foundation.

## Cautions to Implementation

These recommendations are meant to enhance clinician decision-making by describing and evaluating the evidence and reasoning (eg, likely benefits and harms) behind clinical recommendations, and should not be interpreted as setting the medical standard of care.<sup>9</sup> The guidelines present the authors' view of when and how thyroid surgery is best performed based on evidence available at the time of writing. We emphasize that it is the responsibility of treating physicians to maintain a current working knowledge of the management of patients who require thyroid surgery as it pertains to their practice, especially since current evidence is likely to change in the future. The guidelines are not intended for use as a basis to approve or deny financial coverage for any therapeutic or diagnostic modality; cannot account for individual patient characteristics; may not address all relevant comorbidities, subpopulations, effects on patient quality of life, or other factors; cannot be considered inclusive of all proper methods of care; and may omit other treatments reasonably directed at obtaining the same results. We recommend that users confirm that the information presented is correct by way of independent sources. The authors accept no responsibility for inaccuracies, information perceived as misleading, or the success of any treatment regimen detailed within. The guidelines do not represent the only approach to treating thyroid patients, are intended to be flexible, are not meant to replace individual physician judgment, should not be relied on as a substitute for proper patient assessment, and may require significant adaptation in practice settings. The guidelines are intended for the perioperative management of adult patients and should not be applied to the surgical management of children (<18 yrs).

The guidelines content was subject to external peer review. The authors were completely independent from AAES in its production. Nothing in these guidelines is intended to endorse a drug or product; any mention of trade names is intended for identification only. No funding was received by the authors or AAES to support this work.

## PATHOGENESIS AND EPIDEMIOLOGY

Thyroidectomy in the US is most commonly performed for symptomatic benign disease, concern for malignancy, and hyperthyroid conditions.<sup>1,2</sup>

## Thyroid Dysfunction

Thyroid dysfunction (hyper- or hypothyroidism) is present in approximately 6% of the US population, making assessment of thyroid function an essential part of evaluation for all patients with thyroid disease<sup>10,11</sup> (see "Initial Evaluation").

Hyperthyroidism (see "Hyperthyroid Conditions") is due to excess secretion of thyroid hormone from the thyroid gland. Approximately 1.2% of the US population has hyperthyroidism, which can be characterized as nodular (Plummer disease) or diffuse.<sup>12</sup> The most common etiology is Graves disease (GD), followed by toxic multinodular goiter (TMNG) and toxic adenoma (TA).<sup>13</sup> Thyrotoxicosis

**TABLE 2.** Thyroid Tumor Phenotype and Associated Genetic Alterations

Phenotype	Known Somatic Genetic Mutation/Alterations
Toxic adenoma	<i>TSH-R, GNAS</i>
Benign thyroid nodules	<i>N-, H-, and K-RAS, EIF1AX</i>
Noninvasive follicular tumor with papillary like features (NIFTP)	<i>N-, H-, and K-RAS, BRAF K601E</i>
Infiltrative Follicular Variant Papillary Thyroid Carcinoma (FVPTC)	<i>N-, H-, and K-RAS, BRAF V600E</i>
PTC	<i>RET/PTC, BRAF V600E, N-, H-, and K-RAS, TERT</i>
Columnar cell, tall cell, hobnail variant PTC	<i>BRAF V600E</i>
Diffuse-sclerosing variant PTC	<i>RET/PTC</i>
Follicular thyroid carcinoma (FTC)	<i>N-, H-, and K-RAS, PAX8/PPAR, PTEN</i>
Hürthle cell carcinoma	<i>NRAS, genes in the PI3K-Akt pathway</i>
PDTC	<i>NRAS (Insular), BRAF V600E, PIK3CA, RET/PTC, TERT</i>
ATC	<i>NRAS, BRAF V600E, PIK3CA, TP53, βcatenin, EIF1AX</i>
MTC	<i>RET (germ line mutation in inherited MTC, somatic mutation), N-, H-, and K-RAS (somatic mutations)</i>

can be autoimmune (GD, Hashimoto's thyroiditis), drug-induced (amiodarone, lithium, cytokine, tyrosine-kinase inhibitors, immunotherapy), or postpartum. GD is the most common form of hyperthyroidism in the US, with an incidence of 20 to 50 cases per 100,000 persons. It affects a younger population, women 5 times more often than men, and is more common in Caucasians.<sup>14</sup> TMNG prevalence increases with age, making this etiology more common among older patients.<sup>15</sup> TA has been associated with somatic activating mutations (Table 2).<sup>16</sup> Practice patterns for the treatment of GD vary geographically, between disciplines and over time,<sup>17</sup> with surgery as the first-line therapy in 75% of patients with TA and 50% with TMNG.<sup>12,18</sup>

Hypothyroidism is found in 4.6% of the US population, and 4.3% is subclinical (elevated TSH only).<sup>18</sup> Hypothyroidism can be caused by autoimmune disease (Hashimoto thyroiditis, Reidel thyroiditis), thyroidectomy, radioactive iodine treatment, congenital disorders, and medications (eg, amiodarone and lithium). Immunoglobulin G4-related systemic disease can manifest as Reidel thyroiditis or the fibrous variant of Hashimoto thyroiditis;<sup>19–22</sup> such patients frequently present with compressive symptoms. Patients with Hashimoto thyroiditis are at increased risk for the development of papillary thyroid carcinoma (PTC) on pooled systemic-analysis<sup>23</sup> and rarely, for primary thyroid lymphoma.

Although most are treated medically, hypothyroid, or hyperthyroid patients with Hashimoto thyroiditis who are poorly controlled with medication or have symptoms of local compression may need thyroidectomy (see “Indications, Extent and Outcomes of Surgery” and “Hyperthyroid Conditions”).<sup>24</sup>

### Benign Thyroid Nodules

Nonfunctioning thyroid nodules (also referred to as nodular goiter or nodular hyperplasia) are very common.<sup>3</sup> They can occur in up to 19% to 68% of randomly selected individuals, with prevalence increasing linearly with age and higher in women.<sup>25</sup> While the exact ratio of benign to malignant thyroid nodules is unknown, as not all patients undergo surgery, estimates are from 7 to 13:1 based on cytology and 2 to 5:1 based on surgical pathology.<sup>26</sup> Nodule size is not consistently associated with PTC in large cohort studies, multiple systematic reviews, and meta-analyses.<sup>26–32</sup> However, in 2 large clinical studies, an association was observed between larger nodule size and higher risk of follicular or Hürthle cell malignancy.<sup>26,33</sup>

Follicular neoplasms (either adenoma or carcinoma) make up approximately 20% of nodules undergoing fine-needle aspiration biopsy (FNAB).<sup>34</sup> Follicular adenoma (FA) maintains a microfollicular cytoarchitecture without invasion of the capsule or microvasculature and does not have nuclear features of PTC. FA are typically solitary and may contain papillary hyperplasia (papillary cytoarchitecture without nuclear features of PTC).<sup>35,36</sup> Post-FNAB pseudo-

invasion can be distinguished from true capsular invasion by identifying evidence of inflammatory/fibrotic reaction along the needle track. Some FA have pleomorphism, mitoses, and necrosis but not invasion and are considered precursor lesions to poorly differentiated or anaplastic thyroid carcinoma.<sup>37</sup>

Hürthle cell neoplasms, including Hürthle cell adenomas (HA) and carcinomas (HCTC), are now considered a distinct entity/type of well-differentiated thyroid cancer by the World Health Organization (WHO). The distinction between HA and HCTC is based on evidence of capsular or vascular invasion.<sup>38</sup>

### Lesions of Indeterminate Malignant Potential

Although thyroid histopathologic diagnostic categories were previously limited to benign and malignant, in 2017, the WHO introduced a category for borderline thyroid tumors which includes: 1) noninvasive follicular thyroid neoplasm with papillary-like features (NIFTP); 2) well-differentiated tumor of uncertain malignant potential (WDT-UMP), and 3) follicular tumor of uncertain malignant potential (FT-UMP)<sup>38</sup> (See “Perioperative Tissue Diagnosis”). With each of these relatively new diagnoses, future studies are needed to elucidate the diagnostic accuracy, clinical course, and molecular distinctions (Table 2).<sup>39</sup>

### Thyroid Cancer

Thyroid cancer (TC) incidence has been increasing over the past few decades, predominately ascribed to the detection of small PTC.<sup>40,41</sup> Over 2 decades, the proportion of PTC < 1 cm (papillary thyroid microcarcinoma, PTMC) increased from 25% to 39% over 2 decades.<sup>40</sup> The increase has been observed irrespective of sex and across race and ethnicities, with the greatest rise in white females.<sup>42</sup> Ionizing radiation is a known risk factor for PTC (see “Initial Evaluation”). Although the US Preventive Services Task Force concluded from a systematic review that screening for thyroid cancer would likely identify indolent tumors and may increase the risk of harm,<sup>43</sup> recent evidence indicates that there is also an increasing incidence of larger, more aggressive PTC and, contrary to prior reports, an increase in incidence-based mortality (annual percent change of 1%).<sup>44</sup>

The several different types of thyroid cancer are categorized by cell of origin.<sup>38</sup> Those derived from follicular cells are the well-differentiated thyroid carcinomas (DTC, broadly categorized as PTC, follicular cancer (FTC), and HCTC), poorly differentiated carcinoma (PDTC), and anaplastic thyroid carcinoma (ATC). DTC make up >95% of the TC diagnosed each year<sup>13</sup> and the most common subtype (>88%) is PTC, of which 75% to 80% are the classical variant. Aggressive PTC variants include the tall cell, columnar cell,

**TABLE 3.** Histopathological Features of Thyroid Tumors Derived From Follicular Cells

Diagnosis	Cytoarchitectural Pattern	Nuclear Features of PTC	Capsular Invasion
PTC	Papillary	Yes	N/A
WDT-UMP	Papillary	Yes*	Into but not through†
FVPTC	Follicular	Yes	Yes
NIFTP	Follicular	Yes	No
FT-UMP	Follicular	No	Into but not through
MIFTC	Follicular	No	Minimal
MIFTC w/angioinvasion	Follicular	No	Yes
WIFTC	Follicular	No	Gross

\*Well-developed or partially developed PTC-like nuclear changes.

†Questionable capsular or vascular invasion.

hobnail, and diffuse sclerosing types, while clinically less aggressive variants include most FVPTC and Warthin-like tumors.

Recent nomenclature changes are essential to review. The distinction between FVPTC and either WDT-UMP or NIFTP is largely based on penetration of the tumor capsule (Table 3). The diagnosis of classical PTC requires papillary cytoarchitectural pattern as well as nuclear features of PTC.<sup>38</sup> FTC, comprising approximately 8% of DTC cases, is divided into widely invasive (ie, gross invasion) and minimally invasive. Minimally invasive FTC is further risk-stratified by the degree of microscopic capsular and vascular invasion. FTC with capsular invasion alone or with vascular invasion limited to less than 4 vessels is considered lower risk by some; others consider any vascular invasion as high risk.<sup>45</sup> The 2017 WHO Classification groups FTC into minimally invasive (capsular invasion only), grossly encapsulated angioinvasive FTC, and widely-invasive FTC.<sup>38</sup>

Hürthle cell carcinoma (HCTC, 2.3%), has characteristic mitochondrial-rich, plump follicular cells that stain pink with eosin, and have a distinct molecular signature from FTC.<sup>46–48</sup>

PDTC has a worse prognosis (mortality of ~50%) than all DTC variants, and exhibits high grade features; prognosis is associated with the degree of poor differentiation.<sup>49,50</sup> Turin consensus diagnostic criteria include 1) 1 of 3 typical growth patterns (insular, trabecular, or solid), 2) absence of conventional nuclear features of PTC, and 3) presence of one convoluted nuclei; >3 mitoses per HPF, or tumor necrosis.<sup>51</sup> ATC is found in <1% of cases but accounts for 40% of thyroid cancer deaths. Observations of foci of PDTC and ATC within lower-grade tumors, as well as stepwise molecular pathogenesis using varying platforms, lend support for progression from DTC to PDTC to ATC<sup>52</sup> with an increasing mutation burden, particularly involving *TERT* promoter, *TP53*, *EIF1AX*, genes involved in the PIK3CA-AKT-mTOR pathway, SWI/SNF complex, and mismatch repair genes<sup>53–55</sup> (see “Molecular Testing”).

Medullary thyroid cancer (MTC), which today makes up approximately 2% of incident TC cases, originates in the calcitonin producing parafollicular C-cells predominately found in the upper thyroid poles. Sporadic MTC is 3 times as common as hereditary MTC. While nearly all cases of familial MTC, MEN2A, and MEN2B have germ line mutations in the *RET* proto-oncogene, only 50% of sporadic cases include somatic mutations of this gene.<sup>56</sup> Depending on the specific *RET* mutation, C-cell hyperplasia is seen as early as birth in MEN2B patients. As C-cell hyperplasia can also be present in a number of benign diseases, the distinction between it and medullary thyroid microcarcinoma is challenging; the entity is defined by some as invasion through the follicular basement membrane and others by high density of C-cells per high-power field.<sup>57</sup> Regardless of the setting, parafollicular cells are not iodine-avid, making extirpative surgical treatment of MTC critical (See “Initial Thyroidectomy,” “Nodal Dissection,” “Familial TC”).

### Primary Thyroid Lymphoma

Primary thyroid lymphoma (PTL) is rare, and the main treatment is chemotherapy and/or EBRT; however, given that 90% of patients present with rapidly enlarging goiter and some with acute airway compromise, surgeons are frequently involved in management (see “Perioperative Tissue Diagnosis”). PTL can be misdiagnosed as ATC. Lymphocytic thyroiditis is found histologically in over 50% of cases,<sup>58</sup> with a majority of patients having a history of Hashimoto thyroiditis.<sup>30,58–60</sup> Knowledge of its pathognomonic pseudocystic ultrasound (US) pattern (asymmetrical hypoechoic areas) and of the need to obtain an adequate biopsy specimen (by FNAB, core tissue biopsy, and/or open operative biopsy) for flow cytometry are essential for making a PTL diagnosis and determining the subtype of lymphoma.<sup>61</sup>

### INITIAL EVALUATION

The initial surgical evaluation of a patient with thyroid disease provides pivotal information about malignancy risk, symptomatology, and possible thyroid hormonal dysfunction. Findings also can guide laboratory and imaging evaluation and may influence the conduct and extent of thyroidectomy (see “Indications, Extent, and Outcomes of Surgery”).

### History

#### Ionizing Radiation

The initial evaluation should query for a history of ionizing radiation (XRT) exposure, which is a risk factor for PTC.<sup>62</sup> Especially during the 1950s, XRT was administered for many pediatric conditions such as skin angiomas, acne, facial hirsutism, enlarged adenoids, tinea capitis, or tuberculous cervical adenitis, and was also given widely to infants who supposedly had “thymic enlargement” in studies of respiratory distress and sudden infant distress syndrome.<sup>63</sup> Currently, cervical XRT is used therapeutically for Hodgkin disease but even when delivered predominantly to the abdomen and/or chest can have effects on the thyroid in pediatric patients.<sup>63</sup>

Increased risk of TC was observed after nuclear exposure at Hiroshima and Nagasaki (1945), the Bikini Atoll (1954), Chernobyl (1986), and Fukushima (2011).<sup>64</sup> The accident at Chernobyl resulted in atmospheric release of radioactive iodine which affected the thyroid preferentially.<sup>65,66</sup> In contrast, the recent incident in Fukushima yielded radiation exposure at lower doses than originally predicted, and other studies suggest that the risk of TC may not be increased.<sup>67,68</sup> In the US, TC incidence has increased at a rate greater than predicted in the counties surrounding Three Mile Island, but it is not known if the rise was caused by the 1979 nuclear accident.<sup>69</sup>

The radiation-related factors that increase TC risk are: dose, age at exposure, latency period, female gender, and degree of iodine deficiency at exposure.<sup>64,70–72</sup> In a pooled analysis, risk increased

**TABLE 4.** Inherited Predisposition Syndromes for Thyroid Cancer

	Familial Adenomatous Polyposis	<i>PTEN</i> -Hamartoma Tumor (Cowden)	Carney Complex Type 1	<i>RET</i> -Associated	<i>DICER1</i>
Gene	<i>APC</i>	<i>PTEN</i>	<i>PRKARIA</i>	<i>RET</i>	<i>DICER1</i>
Pathognomonic criteria	>100 colorectal adenomatous polyps	Mucocutaneous lesions, cerebellar tumors (Lhermitte-Duclos disease)	Multiple pigmented skin lesions (eg, nevi, blue nevi, lentiginos)	Medullary thyroid cancer	Pleuropulmonary blastoma
Other major manifestations	–	Breast, endometrial, thyroid cancer, macrocephaly	Blue nevi, pigmented nodular adrenals, cardiac myxomas	Primary hyperparathyroidism, pheochromocytoma, mucosal neuromas	Ovarian sex cord-stromal tumors, cystic nephroma, and multinodular goiter
Minor manifestations	Extracolonic polyps, congenital hypertrophy of retinal pigment epithelium, thyroid nodules/cancer, soft tissue tumors, desmoids, osteomas	Fibrocystic breast disease, gastrointestinal hamartomas, lipomas, fibromas, renal cell carcinomas uterine fibromas	Thyroid nodules, melanotic schwannomas, adrenal or pituitary adenomas, hepatocellular carcinoma, pancreatic cancer	Hirschsprung's disease, cutaneous lichen amyloidosis	Wilms tumor, rhabdomyosarcoma, ciliary body medulloepithelioma, pineoblastoma, pituitary blastoma, nasal chondromesenchymal hamartoma
Thyroid disease prevalence:					
Benign	40%	75%	Up to 75%	–	Up to 30%
Cancer	0.4-12%	35%	<5%	100%	–
Cancer	CMV-PTC 63%	PTC 50%	PTC	MTC	FTC
Subtypes	FV-PTC 25% PTC 12%	FV-PTC 28% FTC 14%	FTC		FV-PTC

CMV indicates cribriform-morular variant. FV, follicular variant.

with doses of 0.05 to 0.1 Gy but decreased when the dose exceeded 30 Gy.<sup>73</sup> Younger age increased the risk, which appeared to peak at 25 to 30 years post exposure but remained elevated more than 50 years later. Exact determination of cancer latency periods is likely affected by surveillance intensity.<sup>73</sup> In meta-analysis, the incidence of TC following XRT for breast cancer was ~3-fold higher than in the general population, although a lesser degree of association was also observed in women with breast cancer who did not receive XRT, likely implicating other factors.<sup>74</sup>

### Syndromic TC

A number of inherited predisposition syndromes can increase the risks of thyroid nodular disease and TC (Table 4; see “Familial TC”). In general, patients with syndromic TC either have a known history of inherited predisposition syndrome or a family history of the associated manifestations.

Distinctive thyroid histologic findings should lead to syndromic evaluation. For example, cribriform-morular variant of PTC can be a manifestation of familial adenomatous polyposis (FAP), while the presence of multiple oncocytic follicular nodules and neoplasms is concerning for *PTEN*-hamartoma syndrome.<sup>75</sup> With the exception of *RET*-associated syndromes, it is controversial whether a preoperative diagnosis of inherited predisposition should alter the initial diagnostic approach for a thyroid nodule. However, the preoperatively known presence of a familial *RET* mutation is valuable, as it may impact the extent of initial thyroidectomy, the decision to perform prophylactic thyroidectomy, the management of other disease-related manifestations, and the evaluation of at-risk family members<sup>76,77</sup> (see “Familial TC”).

### Clinical Characteristics

Ascertaining the history is important, including how and when the presenting problem was identified, whether there were prior biopsies or evaluations, and whether growth or change has been perceived by the patient or providers. A history of chronically stable thyromegaly that has recently transitioned to rapid growth is

concerning for an aggressive malignancy. A history of autoimmune thyroiditis, hypothyroidism, or GD also should be obtained, as it can alter recommendations for the extent of initial thyroidectomy (see “Indications, Extent, and Outcomes of Surgery”).

The evaluation should be consistent for all patients with thyroid nodules, but a personal history of nonthyroid malignancy raises concern for metastasis to the thyroid, which is rare but has been reported with renal cell, lung, colon, breast, melanoma, and ovarian primaries.<sup>78</sup> Most such lesions are metachronous, and presentation is often similar to primary nodular disease. Although the thyroid can be the sole metastatic site for ~10% of nonthyroid cancers, prior to thyroidectomy a concern for secondary spread should prompt consideration of oncologic reassessment of time to recurrence, and feasibility of complete resection.<sup>79</sup>

The patient should be asked about presence/absence of compressive symptoms (Table 5).<sup>80</sup> Classically, dysphagia to solids suggests a mechanical obstruction (such as thyromegaly), while dysphagia to liquids alone (or first) is more likely related to esophageal dysmotility.<sup>81</sup> Swallowing symptoms are reported in up to 50% of thyroid patients, often associated with reflux,<sup>82</sup> and may improve after thyroidectomy.<sup>83</sup> In a prospective study of 200 consecutive thyroid nodule patients, globus sensation was routinely assessed by a visual analogue scale pre- and post-thyroidectomy and was reported in up to 60% of subjects, with improvement following thyroidectomy in 80% to 90%.<sup>84</sup> Globus sensation is associated with nodules >3 cm, anterior nodule location, thyromegaly, and thyroiditis.<sup>85</sup> Other causes of globus or dysphagia should be considered before attributing them to thyroid disease.

Dyspnea has been described in thyroid nodular disease, most commonly in association with goiter; it can also result from cardiac dysfunction or pulmonary hypertension secondary to untreated hyperthyroidism, or even hypothyroid-related diaphragmatic dysfunction. Shortness of breath is reported in ~40% to 50% of patients with goiter.<sup>86</sup> Positional dyspnea is seen in up to 3 quarters of patients with substernal goiter, may be associated with a diagnosis of obstructive sleep apnea,<sup>84</sup> and may improve with thyroidectomy

**TABLE 5.** Compressive Symptoms That May Be Associated With Thyroid Nodules/Cancer

	Definition	Nonthyroid Related Etiologies
Dysphagia	Difficulty in transitioning food from the mouth to stomach	Benign and malignant esophageal lesions, Zenker's diverticulum, esophageal stricture, esophageal dysmotility, sensory or motor deficits of the esophagus, RLN or SLN dysfunction, aberrant right subclavian artery (associated with nonrecurrent laryngeal nerve)
Globus sensation	Feeling of lump or other foreign body in the throat	Reflux, lingual tonsil hypertrophy, laryngeal or pharyngeal neoplasm, esophageal dysmotility
Positional dyspnea	Shortness of breath that is relieved with change of position	Platypnea-orthodeoxia syndrome (symptoms improve with lying flat), other cardiac shunting abnormalities, mediastinal or abdominal mass
Orthopnea	Shortness of breath when lying flat that improves when sitting or standing	Cardiopulmonary disease, obstructive sleep apnea, diaphragmatic dysfunction
Hoarseness	Abnormal voice	Reflux, sinus-related, sarcoidosis, idiopathic, muscle tension, age-related atrophy, prior intubation, viral, vocal fold neoplasm

particularly if objective parameters of mass effect are present including tracheal compression of >35% on preoperative cross-sectional imaging, a resected gland weight of >100 g, and/or a unilateral resected lobe weight of >75 g<sup>86,87</sup> (see "Goiter"). An assessment for rapid progression of dyspnea is important, since this can be associated with an aggressive malignancy.

Obtaining a history to evaluate the patient for thyroid hormone dysfunction is important.<sup>3</sup> Symptoms of hyperthyroidism include fatigue, palpitations, anxiety, insomnia, unexplained weight fluctuations, visual changes, and heat intolerance.<sup>13</sup> Symptoms of severe hypothyroidism may overlap, however; such symptoms include cold intolerance, constipation, dry skin, slowed thinking, and edema.<sup>88</sup> Assessing thyroid function by symptomatology alone lacks both sensitivity and specificity, and diagnosis must include biochemical evaluation.

The history also should identify patient-specific characteristics that may increase operative risk, require preoperative management, and/or alter the operative approach (Table 6). For example, prior thyroid or parathyroid surgery could have resulted in morbidity related to hypoparathyroidism and nerve injury, thereby elevating remedial surgery risk (see "Reoperation").

**Recommendation 1: Evaluation of thyroid disease should include specific inquiry about personal history, family history, clinical characteristics, and symptoms. (Strong recommendation, low quality of evidence)**

Several preoperative risk assessment tools intended to optimize patient selection and anticipate operative morbidity have been investigated (including the ACS NSQIP surgical risk calculator and indicators of frailty) but have not yet been validated for thyroidectomy patients. In a recent NSQIP study of total thyroidectomy, factors associated with postoperative morbidity included age  $\geq 70$  years, non-Caucasian race, dependent functional status, history of CHF, smoking history, hypertension, steroid use, wound infection, history of preoperative sepsis, bleeding disorder, and ASA class  $\geq 3$ .<sup>89</sup> In a NSQIP study that included all types of thyroidectomy, risk factors for morbidity included age  $\geq 70$  years, steroid use, diabetes, hypertension, COPD, and dialysis.<sup>90</sup> Both studies were inherently limited as the NSQIP database captures only 30 day and nonprocedure-specific outcomes (see "Postoperative Care and Complications"). In high-risk or frail patients with significant comorbidities, the goals of thyroidectomy should be carefully assessed and nonoperative approaches considered.

**TABLE 6.** Personal History or Physical Examination Findings Which Modify Operative Risk

	Preoperative Intervention
Personal or family history of anesthetic complications	Screening for malignant hyperthermia Anesthesia evaluation
History of difficult intubation or small recessed jaw	Anesthesiology Evaluation with possible awake intubation, be prepared for rigid bronchoscopy Assess neck access on exam CT imaging as required
Prior thyroid/parathyroid, Carotid, or other pertinent surgery	Review of operative and pathology reports Query for postoperative complications (voice changes or hypocalcemia) Voice assessment/laryngeal evaluation
Prior cervical discectomy	Assess extent of neck extension Assess for presence of radiculopathy Possible CT/MRI of cervical spine if indicated by neurologic symptoms if prior anterior approach, Voice assessment /laryngeal evaluation
Possible or diagnosed bleeding or clotting disorder	Screen for need for hematologic evaluation
Currently taking antithrombotic or antiplatelet medications	Document indication for medication (atrial fibrillation, clotting disorder, high risk for CVA, prior revascularization procedure, etc) Discussion with prescribing MD to balance perioperative medical management with risk of postoperative cervical hematoma
Celiac sprue, IBD, Roux en Y gastric bypass, or any condition of chronic diarrhea	Check vitamin D 25-OH level and if low, replete preoperatively If chronically on calcitriol, check vit D 1,25 OH level Counsel patient regarding implications of malabsorption in postoperative management



**TABLE 7.** ATA Ultrasound Features and Size Guide the Need for FNAB for Thyroid Nodules and Cervical Lymph Nodes

Risk Category	Features	Risk of Malignancy, %	Nodule Size to Biopsy, cm
High	Solid or solid/cystic AND $\geq 1$ of the following concerning features: Irregular margin Microcalcifications Taller-than-wide Rim calcifications with soft tissue extrusion Extrathyroidal extension	70–90	$\geq 1$
Intermediate	Hypoechoic solid w. no concerning features	10–20	$\geq 1$
Low	Isoechoic or hyperechoic solid or partially cystic w. no concerning features	5–10	$\geq 1.5$
Very low	Spongiform or partially cystic without any of the above features	$< 3$	$\geq 2$
Benign	Purely cystic	$< 1$	–
–	Malignant lymph nodes (microcalcifications, cystic component, peripheral vascularity, hyperechogenicity, round shape, loss of echogenic fatty hilum)	50–100	–

### Physical Examination

Examination findings that can suggest hyperthyroidism include elevated heart rate, hypertension, and exophthalmos. A slow heart rate and slowed Achilles heel reflex time may signal hypothyroidism. In meta-analysis, overweight and obese patients have significant higher risks of PTC, FTC, and ATC, but no increased risk of MTC.<sup>91,92</sup> Taller height also has been associated with increased DTC risk.<sup>92</sup> Demographic and anthropometric factors are not reliable indicators of histology.

The physical assessment is also a key step in operative planning (Tables 6, 7). Palpable nodules are typically at least 1 cm in size.<sup>93</sup> Immobile nodules, especially with associated lymphadenopathy, are concerning for malignancy. Thyromegaly is often evident preoperatively, but its extent may be apparent only with supine positioning (see “Goiter”). When the inferior extent of a nodule or enlarged thyroid lobe is not accessible on exam (ie, goes below the clavicle), CT imaging should be obtained for evaluation of the extent of substernal projection.<sup>84–86</sup> Pemberton sign is the presence of vascular engorgement and facial congestion occurring when a patient with a large substernal goiter raises their arms over their head, further narrowing the thoracic inlet.<sup>94</sup> Limited neck extension can herald difficulty in intraoperative positioning or access. If associated with neurologic symptoms, limited neck mobility also can suggest underlying cervical disc disease requiring further preoperative evaluation and even pre-emptive or simultaneous management.

### Voice Assessment

A careful voice assessment should be performed in the evaluation of thyroid disease. Subjective voice impairment was reported preoperatively in 30% to 80% of thyroidectomy patients, and the incidence varies by type of voice quality assessment used.<sup>82,95</sup> Voice changes and hoarseness can have numerous causes but are frequently idiopathic. Further evaluation should be performed for patients who have had prior surgery that put the RLN at risk, including anterior cervical dissection, prior thyroid/parathyroidectomy, carotid endarterectomy, tracheostomy, cardio/thoracic procedures, and esophagectomy (Table 6).<sup>3</sup> Such a history should be specifically investigated and sites of prior incisions should be noted on examination. Documented vocal fold immobility can impact the decision for surgery and the extent of thyroidectomy (see “Indications, Extent, and Outcomes of Surgery,” “Laryngology”).

Laryngeal examination can be performed using several different techniques. Both current guidelines and the cost-to-benefit ratio of routine preoperative laryngeal examination on all thyroid patients recommend a selective approach.<sup>3,96</sup> (see “Laryngology”).

**Recommendation 2:** *The preoperative physical examination should include voice assessment. (Strong recommendation, moderate-quality evidence)*

### Laboratory Evaluation

The initial laboratory evaluation for all patients with thyroid disease should include a serum TSH level. If the TSH is suppressed, then a free T4 and total T3 should be obtained, and management of hyperthyroidism should be the initial clinical focus.<sup>13</sup> In addition, a thyroid uptake scan should be obtained to assess if the index nodule is hyperfunctioning; such nodules have a low risk of malignancy and do not require FNAB<sup>97,98</sup> (see “Hyperthyroid Conditions”). In most cases an elevated TSH level should be normalized prior to further management.<sup>3</sup> Thyroiditis may be further assessed if the information will help determine surgical management (see “Indications, Extent, and Outcomes of Surgery”). Nodules identified in the setting of euthyroidism should be assessed with US and FNAB (see “Imaging,” “FNAB Diagnosis”).

In the absence of known MEN2A, the incidence of concomitant parathyroid disease in patients with thyroid nodules is 3% to 5%<sup>99–101</sup> and is higher (~35%) with prior XRT<sup>102</sup> among other factors.<sup>6</sup> Because of the cost and potential morbidity of missed parathyroid disease, preoperative assessment of serum calcium should be considered, and measurement of parathyroid hormone also may be indicated (see “Concurrent Parathyroidectomy” and “Preoperative Care”).

Routine screening for MTC using preoperative calcitonin levels is controversial. In a study of >10,000 patients with thyroid nodules, an elevated basal calcitonin level was more sensitive than FNAB in diagnosing MTC, and such patients presented with earlier stage disease and had longer disease-specific survival.<sup>103</sup> However, these calcitonin elevations were all confirmed by pentagastrin stimulation, which is no longer available in the US. False-positive rates of nonstimulated calcitonin vary widely, and a number of benign conditions can contribute to spurious elevation, including chronic renal failure, proton pump inhibitors, chronic lymphocytic thyroiditis, DTC, and non-thyroidal malignancies.<sup>104</sup> Current ATA and NCCN guidelines do not recommend screening basal serum calcitonin levels in the evaluation of thyroid nodules.<sup>3,105</sup> Targeted screening for at-risk individuals should be considered.

When MTC is diagnosed by FNAB or is suspected on history, measurement of serum calcitonin and CEA levels is useful as they can be accurate indicators of disease extent. A basal calcitonin level  $< 20$  pg/mL is associated with a low risk of nodal metastasis, while a preoperative level  $\geq 500$  pg/mL raises concern

for distant metastasis.<sup>106,107</sup> *RET*-gene testing should inform the risk of associated manifestations (see “Familial TC”).

**Recommendation 3: TSH should be measured in patients with nodular thyroid disease. Additional laboratory studies may help in specific circumstances. (Strong recommendation, low-quality evidence)**

### IMAGING

Successful thyroid surgery is contingent on thorough and accurate imaging, which also impacts preoperative planning, extent of surgery, and postoperative management. Inadequate preoperative imaging may be a root cause of incomplete initial surgery.<sup>108,109</sup>

#### Preoperative

##### Ultrasonography

The initial and most critical thyroid imaging study is cervical US. Current adult guidelines recommend a thyroid US with survey of the cervical lymph nodes (CLN) in patients with a known or suspected thyroid nodule, and for all patients undergoing thyroidectomy for malignant or suspicious cytologic or molecular findings.<sup>3</sup> The objectives of diagnostic US are to assess the nodule or tumor (size, location, suspicious features) and to identify and characterize abnormal lymph nodes in the central and lateral neck which may be involved with thyroid cancer.

**Thyroid Nodule US.** Multiple studies have characterized the sonographic features associated with TC, including microcalcifications, hypoechogenicity, irregular margins and a shape taller than wide measured on transverse view.<sup>110–119</sup> Features predictive of TC are microcalcifications, irregular margins, and tall shape (Table 7). Up to 58% of benign nodules are hypoechoic compared to thyroid parenchyma, making nodule hypoechogenicity less specific.<sup>116</sup>

High, intermediate, low, very low, and benign thyroid nodule characteristics and malignancy rates appear in Table 7.<sup>120–125</sup>

The US features of FTC differ from those of PTC. Intranodular vascularity correlates with malignancy in follicular lesions, but not PTC. Furthermore, compared to conventional PTC, FVPTC is more likely to have the same US appearance as FTC, and both FTC and FVPTC are more likely to be iso- or hyperechoic.<sup>115,116,126–129</sup> However, a recent meta-analysis concluded that vascular flow on color Doppler sonography may not accurately predict TC.<sup>130</sup>

Several groups, including the ATA,<sup>3</sup> have proposed methods to guide practitioners in recommending FNAB based on observed US features.<sup>120,131–133</sup> From the American College of Radiology, the recent Thyroid Imaging, Reporting and Data System (TI-RADS) uses nodule composition, echogenicity, shape, margin, and echogenic foci to assign a predictive score from TR1 to TR5; TR1 nodules are likely benign and FNAB is not advised, whereas TR5 nodules are highly suspicious for cancer. The system was validated in a prospective study where the TI-RADS predictive score correlated with histologic malignancy rate<sup>134</sup> but its performance efficacy has not yet been studied in cohorts with long-term nonoperative surveillance. Figure 1 compares the ATA and TI-RADS classification systems for recommending FNAB.

**Parathyroid Incidentaloma US.** Fastidious neck US has led to the unexpected detection of enlarged parathyroid glands, sometimes termed parathyroid incidentalomas,<sup>135,136</sup> with a detection rate of about 1.5%.<sup>136</sup> Normal parathyroids are too small to be seen on US, but enlarged glands often have characteristic US features that differentiate them from lymph nodes (LN), such as shape, location, hypoechogenicity, and a hilar or polar feeding vessel.<sup>6</sup> FNAB with PTH washout<sup>137</sup> and/or molecular analysis can confirm their presence, but the diagnosis of hyperparathyroidism is rendered biochemically. Because parathyroid FNAB can cause hemorrhage producing surrounding fibrosis which results in alteration of surgical dissection

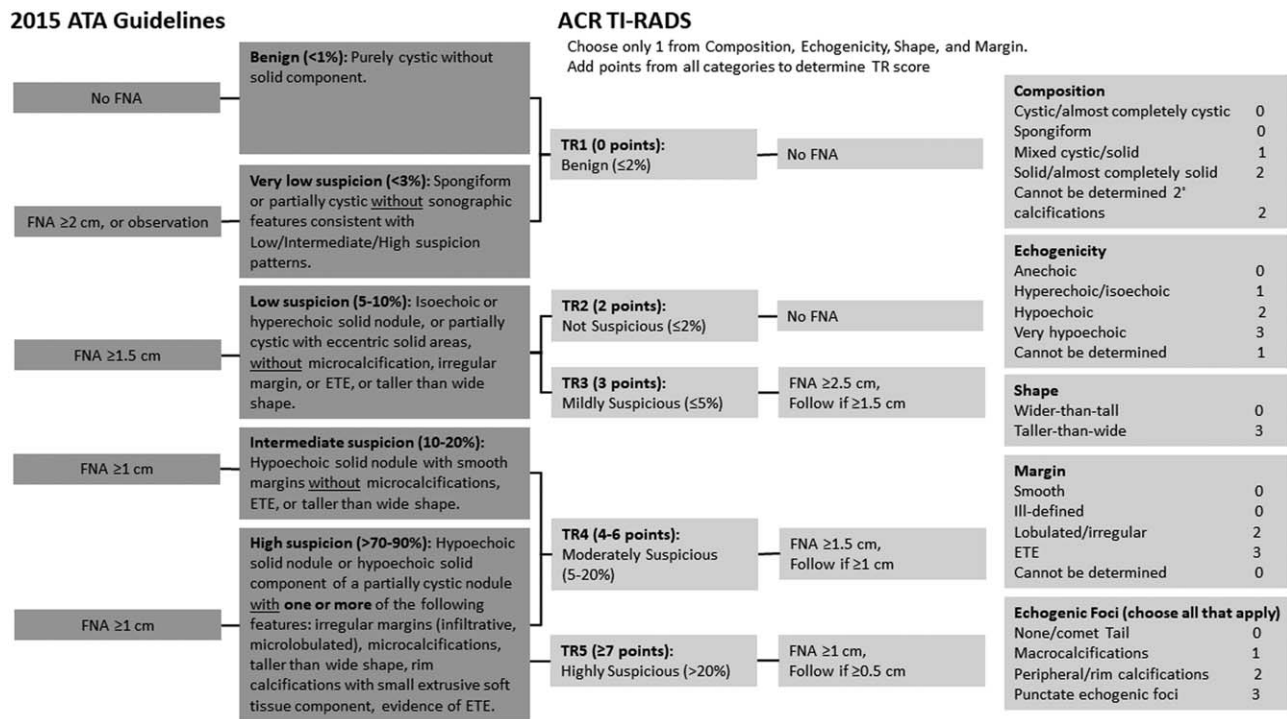


FIGURE 1. Comparison of the ATA 2015 Guidelines and ACR TI-RADS classification systems for recommending FNAB.

planes and can cause histologic changes mimicking parathyroid carcinoma, FNAB of parathyroid glands is to be avoided when possible<sup>6</sup> (see “Concurrent Parathyroidectomy”).

**Cervical Lymph Node US.** US is the first-line imaging modality for assessment of cervical lymph node metastasis (CLNM).<sup>138,139</sup> Many experts routinely perform US evaluation of the central and lateral neck whenever thyroid nodules are detected. Central and lateral LN are affected by metastatic PTC in up to 70% of cases,<sup>140</sup> either at presentation or during surveillance. The sensitivity of US in detecting abnormal LN varies from 25% to 60% for the central neck and 70% to 95% for the lateral neck.<sup>141,142</sup> One of the main factors influencing sensitivity is practitioner expertise.

Benign CLN are typically oval with a hyperechoic central stripe and vascular flow in the center (ie, hilum).<sup>143</sup> Loss of a visible hilum is felt to represent interruption of lymphatic flow by tumor invasion. In a benign LN, the hilar stripe may not always be easily seen, thus lack of a hilum is only 29% specific for CLNM.<sup>139</sup>

Lymph node location, size, and shape are also important features of US assessment for potential metastatic involvement. Evidence generally supports a stepwise progression of PTC metastases, starting in ipsilateral level VI (prevalence 50–70%) and proceeding laterally to levels III and IV (prevalence 30–45%), and then to level II with some studies reporting equivalent prevalence as for III and IV.<sup>140,144–147</sup> Therefore, if one level is involved, a compartment-oriented selective lymph node dissection is recommended (see “Nodal Dissection”). This progression is not always reliable and should not preclude evaluation of any suspicious LN in the neck. Though LN >1 cm in maximum diameter are conventionally considered more likely to harbor malignancy, many benign or reactive nodes will exceed 1 cm while remaining fusiform in shape, especially near the submandibular glands and in patients with lymphocytic thyroiditis. In a study of DTC that carefully matched the US and histologic findings, size >1 cm was associated with only 68% sensitivity and 75% specificity for CLNM.<sup>148</sup> Smallest nodal diameter >5 mm also has been proposed as a predictor of malignancy, with a reported specificity of 96% and sensitivity of 61%.<sup>139</sup> Shape is more reliably associated with LNM than size. Benign lymph nodes typically are oval or fusiform even with hypertrophy or enlargement from nonmalignant causes, but malignant LN often will appear rounded<sup>139,148,149</sup> because the neoplastic infiltration typically occurs in the cortex, at the site of lymphatic influx.<sup>143</sup> The Solbiati index provides an objective measure of roundness by coding the ratio of longest to shortest nodal diameter. A ratio >2 is highly suggestive of benign character, whereas <2 is concerning for LNM.<sup>143</sup> Other US features predictive of malignant LN involvement include microcalcifications, hyperechoic or cystic character, and peripheral hypervascularity.<sup>149–153</sup>

If US identifies a suspicious LN, FNAB of the lymph node should be performed for cytology, with washout for thyroglobulin measurement when possible.<sup>3</sup>

**LN Mapping.** Bilateral US evaluation of LN compartments II–VI (ie, mapping) should be performed routinely in the preoperative evaluation of patients with cytologic evidence of thyroid carcinoma, and considered for levels I–VII in patients identified to have metastatic nodal disease.<sup>2,154</sup> LN mapping should carefully diagram where suspicious lymph nodes are located and assess for features of aggressive behavior, such as strap muscle invasion, internal jugular vein thrombus, and posterior tumor location. Ideally, this should be performed preoperatively by an experienced sonographer to guide complete resection of the primary tumor as well as a compartment-oriented dissection of affected LN basins, if LNM are present.<sup>108</sup>

**Surgical Planning.** Prior to thyroidectomy, US is often performed by the surgical team to facilitate both operative planning and patient counseling regarding surgical risks. In recent multidisciplinary literature, surgeon-performed US is more accurate, helpful for preoperative planning, and associated with lower local recurrence rates compared to radiologist-performed US.<sup>155–157</sup> As patient positioning is optimized under general anesthesia, surgeons may elect to repeat US just prior to incision to keep an anatomic “roadmap” fresh in their minds and ensure that US abnormalities are adequately addressed at operation and are present in the surgical specimen.<sup>108</sup>

**Recommendation 4: A diagnostic US should be performed in all patients with a suspected thyroid nodule. (Strong recommendation, high-quality evidence)**

**Recommendation 5:**

- US assessment of bilateral central and lateral LN compartments should be performed in the preoperative evaluation of patients with cytologic evidence of thyroid carcinoma. (Strong recommendation, low quality of evidence).**
- US assessment of bilateral central and lateral LN compartments may be performed in the preoperative evaluation of patients with indeterminate cytologic evidence of thyroid carcinoma. (Strong recommendation, insufficient evidence).**

**Translaryngeal US.** Vocal cord ultrasonography (VCUS) is a new modality that can be simple and accurate in diagnosing true vocal fold (TVF) paralysis preoperatively, with a sensitivity of 62–93%.<sup>158,159</sup> In patients with abnormal mobility or inadequate vocal fold visualization, such VCUS results trigger further evaluation with fiberoptic laryngoscopy (FL, see “Laryngology”).<sup>160–162</sup> VCUS can be a sensitive, noninvasive, convenient, and inexpensive method of evaluation and can be performed during the initial surgical visit. However, when the clinical scenario suggests substantial operative risk contingent on the optimal documentation of the degree of vocal cord dysfunction, FL is advised.

**US Limitations.** US is the first-line imaging modality for assessing thyroid nodules and CLN because it is widely available, inexpensive, provides detailed high-resolution anatomic data, avoids ionizing radiation, and facilitates FNAB of suspicious lesions. However, the results are operator dependent.<sup>163,164</sup> US utility is also limited for deep structures and those acoustically shielded by air or bone. Patients with substernal goiter, morbid obesity, poor neck extension, remote cervical adenopathy (high level II, VI or VII, substernal, infraclavicular or retro/parapharyngeal LN) or apparent locally advanced disease may benefit from cross-sectional imaging.

### Cross-sectional Imaging

Cross-sectional imaging, namely, computerized tomography (CT) or magnetic resonance imaging (MRI), has a supplemental role in the preoperative evaluation of thyroid disease, and is recommended with intravenous contrast as an adjunct to US for patients with clinical suspicion of advanced disease, including invasive primary tumor, or clinically apparent multiple or bulky LN.<sup>108</sup> Cross sectional imaging may also be of value with clinical findings such as vocal cord paresis/paralysis, progressive overt dysphagia or odynophagia, mass fixation to surrounding structures, hemoptysis, stridor or positional dyspnea, rapid enlargement, and large size or mediastinal extension (see “Goiter”). US features that prompt CT or MRI include incomplete thyroid or LN imaging, suspicion for significant extrathyroidal invasion (including irregular or indistinct margin between tumor and strap muscles, airway, esophagus or major vessels), bulky, posteriorly located, or inferiorly located LN, and

unavailable US expertise. Both CT and MRI provide axial imaging from skull base to mediastinum in a standardized, reproducible fashion that is user independent. The sensitivities of MRI and PET for detection of CLNM are relatively low (30–40%).<sup>165</sup>

The accuracy of neck CT is optimized by use of intravenous iodinated contrast. Noncontrast CT lacks definition, and its utility is thus limited to gross evaluation of mediastinal disease. MRI with gadolinium is an alternative modality that avoids iodinated contrast. Although MRI resolution can be limited in the central compartment due to motion artifact from swallowing and respiration (169), it is generally preferable to noncontrast CT in preoperative imaging for thyroid cancer.

When CT/MR imaging is required preoperatively, the benefit gained from improved anatomic resolution generally outweighs any potential risk from postponement of subsequent radioactive iodine (RAI) imaging or therapy. Preoperative communication between the surgeon and endocrinologist is important. When there is concern, the urinary iodine-to-creatinine ratio can be measured at an interval of at least 1 month to allow urinary iodine levels to return to baseline levels before moving forward with RAI.<sup>166</sup> At present, there is no evidence to suggest delays of this minor scale adversely affect thyroid cancer outcomes.

**Recommendation 6: CT or MRI with intravenous contrast should be used preoperatively as an adjunct to US in selected patients with clinical suspicion for advanced locoregional thyroid cancer (Strong recommendation, low quality of evidence)**

### Elastography

Ultrasound elastography has been investigated for its ability to modify thyroid nodule cancer risk assessment. Elastography is a measurement of tissue stiffness. US elastography requires an US machine and a computational module, which often must be purchased separately. To allow the required direct determination of tissue strain, the index nodule must not overlap with other nodules in the anteroposterior plane making the test unsuited for patients with multinodular goiter, coalescent nodules, posterior/inferior nodules, or obesity. Although an initial prospective study suggested near 100% PPV and NPV,<sup>167</sup> more recent, larger studies report US elastography performance that was substantially inferior to US.<sup>168</sup> In the largest prospective study, PPV was 36% (comparable to that for US detection of microcalcifications), and NPV was 97% in a population with a low cancer prevalence of 9%.<sup>169</sup> Thus, while US elastography may hold promise as a noninvasive tool, its performance is variable, operator-dependent, and limited to solid nodules of specific shape and accessibility.

### PET/CT

Routine preoperative positron emission tomography (18FDG-PET) scanning is not recommended for the initial evaluation of a thyroid nodule<sup>3</sup> but may be useful in highly selected cases when evaluation suggests aggressive histology such as PDTC or ATC. Studies have shown that 30 to 40% of 18FDG-PET positive thyroid nodules may harbor a malignancy<sup>170–172</sup> thus such nodules should be evaluated by US and FNAB accordingly. PET sensitivity for CLNM is even lower than that of CT/MRI, since PET also can detect inflammatory lymph nodes.

### Imaging for Hyperthyroid Conditions

Thyroid scintigraphy is not indicated in an euthyroid patient.<sup>3</sup> For hyperthyroid patients, US and thyroid uptake testing or scintigraphy are not the primary testing modalities, but their findings can be critical in the differential diagnosis and in selecting treatment after hyperthyroidism is established with serologic test results (see “Hyperthyroid Conditions”).<sup>173,174</sup>

### Postoperative

US is an important tool for TC surveillance, and also aids in the detection, localization, and planning of revision surgery for recurrent/persistent disease<sup>3</sup> (see “Reoperation”). Prior inflammation, scarring, and reactive adenopathy constitute known limiting factors of US and other imaging modalities, thus it is generally advisable to allow approximately 6 months to elapse for imaging of recently manipulated compartments. By contrast, US LN visualization in the central compartment is often improved after total thyroidectomy because there is now little intervening tissue between the trachea and the common carotid arteries. CT or MRI should be considered in previously operated patients with rising and significantly elevated thyroglobulin or calcitonin levels plus negative US (see “Cancer Management”).

### Functional Imaging for TC Metastases

Radioiodine whole body scanning has traditionally been the primary functional imaging modality for patients suspected to have persistent/recurrent DTC.<sup>3</sup> In patients who have undergone remnant ablation, these scans have a high specificity but low sensitivity; moreover, their low resolution is insufficient for surgical planning. Newer technology utilizing radioiodine with SPECT/CT fusion significantly improves anatomic localization of radioiodine avid disease and may be used to guide reoperation with or without radioguidance.<sup>108,175–177</sup>

18FDG-PET is widely accepted as a method for detecting recurrence of DTC, particularly in patients who are thyroglobulin-positive and radioiodine whole body scan negative.<sup>178–180</sup> 18FDG-PET avidity inversely correlates with iodine avidity, and the former has been shown to be a strong predictor of poor outcome in patients with metastases.<sup>180</sup> A number of studies have shown that 18FDG-PET is effective in localizing resectable recurrence(s) in DTC patients, thus facilitating revision surgery.<sup>181–184</sup> The sensitivity of 18FDG-PET-CT appears to be enhanced with thyrotropin stimulation;<sup>185,186</sup> however, some recent studies have refuted the finding.<sup>187</sup>

### FINE NEEDLE ASPIRATION BIOPSY (FNAB) DIAGNOSIS

FNAB is used for evaluation of suspicious thyroid nodules, and the results guide management. Occasionally, core needle biopsy may be indicated (see “Perioperative Tissue Diagnosis”). Soon after introduction in the 1970s, the use of routine preoperative FNAB decreased by 50% the number of patients who required thyroidectomy and doubled the surgical yield of TC.<sup>188,189</sup> Enthusiastic use then led to refinements in technique and indications.<sup>3</sup> In a population level study, >90% were performed using US guidance, and although the rate of thyroid FNAB doubled from 2006 to 2011, the rate of thyroidectomy increased more slowly.<sup>190</sup>

### FNAB Indications

The most recent ATA Guidelines classify a nodule as having high, intermediate, low, or very low suspicion for malignancy based on various US features (see Fig. 1).<sup>3</sup> In addition to these features, size on US can be used to select nodules for FNAB (Table 7), although it remains controversial whether nodule size as an isolated variable is associated with malignancy. In 366 patients with PTC or FTC, distant metastasis did not occur until the primary tumor was >2 cm in size;<sup>191</sup> however, among 1003 thyroid nodules, those <2 cm had the highest risk of malignancy.<sup>192</sup> In a meta-analysis which utilized only studies that included histology, larger nodules (3–5.9 cm) had the highest risk of malignancy.<sup>28</sup> In a study in which not all nodules had histologic correlation, the risk of malignancy was higher in larger

nodules and plateaued at 2 cm, although the risk of FTC and other rare malignancies continued to increase with nodule size.<sup>26</sup> Because of the generally indolent behavior associated with TC <1 cm, subcentimeter nodules are not usually biopsied unless associated with metastatic disease, or if there is suspicion for local invasion (such as a posterior nodule).<sup>3</sup>

Independent of size or US features, other indications for FNAB include nodules in patients with risk factors for malignancy (see “Initial Evaluation,” “Familial TC”) or associated with clinically concerning findings such as fixation, immobility, hoarseness, or RLN dysfunction. Simple cysts are often therapeutically aspirated if symptomatic on presentation.<sup>3</sup> Evidence-based guidelines for deciding which thyroid nodules need to be biopsied have been well described (see Figure 1).<sup>3,131</sup>

### Indications for FNAB of Cervical Lymph Nodes

Suspicious US features of cervical LN include loss of fatty hilum, location, size, shape, microcalcifications, hyperechoic or cystic character, and peripheral hypervascularity<sup>3</sup> (see “Imaging”). Preoperative LN FNAB should be considered if the results will change the planned operative approach. If a total thyroidectomy is already planned, then the central compartment (level VI) LN can be assessed intraoperatively and preoperative biopsy of any suspicious nodes in this compartment may be deferred (see “Nodal Dissection”).

#### Recommendation 7:

- FNAB is a standard component of thyroid nodule evaluation, and its indications should follow established guidelines based on US characteristics, size, and clinical findings. (Strong recommendation, moderate-quality evidence)**
- FNAB of a sonographically suspicious cervical LN should be performed when the results will alter the treatment plan. (Strong recommendation, low-quality evidence)**

### Pre-FNAB Considerations

Complications of FNAB are usually minor, including mild bruising, soreness, swelling, or discomfort. Neck hematoma with airway obstruction, referred pain, and transient RLN paresis are extremely rare events.<sup>193</sup> Studies have demonstrated no effect of antithrombotic or anticoagulant medications on FNAB hematoma or adequacy rates, and these medications do not need to be stopped prior to FNAB.<sup>194,195</sup> The risk of postprocedural hematoma may be reduced by using smaller gauge needles, US guidance to avoid hypervascular areas, and a minimized number of passes. Contraindications to FNAB include being unable to cooperate with the procedure and a history of severe bleeding disorder.<sup>196</sup> Nodules that are not accessible by US (eg, posterior, retroesophageal or anterior mediastinum) may require surgical resection for diagnosis (see “Indications, Extent and Outcomes of Surgery”).

Although the decision to biopsy relies on US criteria and a preprocedure US is typically obtained, in detailed discussion the authors could not reach consensus on whether US guidance is obligatory for thyroid FNAB. At a minimum, US guidance should be used for nonpalpable nodules, those with >25% cystic component, and when an initial FNAB result is inadequate.<sup>196</sup> Nodules that meet imaging criteria for biopsy and are readily palpable may be biopsied with palpation guidance, particularly if US guidance is logistically difficult to acquire.<sup>196</sup> In a recent single institution study of 489 nodules, there was no difference in inadequacy rates or accuracy when nodules were biopsied by palpation compared to US guidance.<sup>197</sup> However, other studies have demonstrated that adequacy rates are higher using US guidance.<sup>198–201</sup>

### FNAB Technique

Standard materials needed for onsite processing of FNAB specimens include long bevel fine needles, syringes, glass slides, 95% alcohol fixative, and liquid-based preservative for cell block preparation. After cleansing the skin, the needle is introduced into the nodule using 6–15 rapid back and forth movements over 2 to 5 seconds. Up to 4 additional passes to sample different regions of the nodule may reduce the likelihood of sampling error, especially for larger nodules. Using US guidance, the 2 commonly used methods are parallel (long axis) or perpendicular (short axis) techniques.<sup>196,202</sup> US gel should be wiped off the skin prior to performing FNAB as it can cause artifacts that interfere in cytologic interpretation.<sup>203</sup> Upon completion, mild pressure is applied to the site (by the patient or an assistant), and a small adhesive dressing is placed.

Slides are made immediately. In conventional smear preparations, the needle contents are extruded as droplets onto glass slides, smeared, and then fixed in 95% ethanol for Papanicolaou staining (valuable in evaluating nuclear detail) and/or air-dried for Diff-Quik staining (which allows for onsite adequacy assessment). If molecular testing is considered, the residual material in the needle hub can be expelled into nucleic acid preservative and stored under appropriate conditions until the test is ordered (see “Molecular Testing”).

Other adjunctive analyses include washout testing for thyroglobulin (Tg) if the biopsied lesion is a LN<sup>3</sup> or for parathyroid hormone (PTH) if there is significant concern for an intrathyroidal parathyroid;<sup>6</sup> the residual material in the hub is collected into ≤1 mL normal saline (or other Tg/PTH-free solution) and compared to serum levels. Reported cutoff Tg levels indicative of CLNM vary widely, and are influenced by factors including whether the thyroid is in situ to provide a source of serum Tg, the presence of anti TgAb, and possible unintended biopsy of adjacent thyroid tissue, particularly in the central compartment.<sup>204–206</sup> Although false-positive results have been reported in the presence of detectable Tg levels, a LN aspiration Tg level <1 ng/mL is likely to signal a benign LN.<sup>204</sup>

Onsite assessment may improve the FNAB adequacy rate,<sup>207</sup> although specimen adequacy also depends on the type of nodule and on operator experience.<sup>196</sup> An adequacy threshold of >85% to 90% has been proposed for achieving proficiency but has not been validated.<sup>202,208</sup> Cystic nodules have little to no follicular cells, while colloid nodules are characterized by abundant, thick colloid. For adequacy, solid nodule cytology requires a minimum of 6 groups of 10 or more well-preserved follicular cells, preferably on a single slide.<sup>196</sup> If the FNAB yield is inadequate, additional aspirations can be repeated immediately as long as the patient is tolerating the procedure. In a study of 1381 thyroid FNABs, onsite assessment improved the adequacy rate (75% vs 60%) and reduced the necessary number of needle passes,<sup>209</sup> and this finding was confirmed in a meta-analysis that also observed the benefit to be more pronounced in centers with lower baseline adequacy rates.<sup>207</sup> Adequacy is also limited by anatomic features such as a high proportion of cystic component, macrocalcifications, and small nodule. Cell block preparation and immediate slide preparation improve the accuracy of FNAB.<sup>210,211</sup>

**Recommendation 8: In most circumstances, FNAB yield and adequacy may be optimized using US-guidance, with or without onsite cytologic assessment. (Strong recommendation, moderate-quality evidence)**

### FNAB Result Categories

Since 2008, cytology is conventionally classified using the Bethesda System for Reporting Thyroid Cytopathology which was updated in 2017 (Table 8).<sup>212,213</sup> Standardization of cytology classification has led to less ambiguous diagnoses and decreased surgery rates without diminishing the accuracy of biopsy results.<sup>212</sup> The

**TABLE 8.** The Bethesda System for Reporting Thyroid Cytopathology

	Category	Proportion of FNAB	Proposed Risk of NIFTP or Malignancy	Proposed Risk of Malignancy (Excludes NIFTP)	Clinical Management
I.	Nondiagnostic	10%–15%	5%–10%	5%–10%	Correlate with clinical/radiologic findings Consider repeat FNAB
II.	Benign	60%	0%–3%	0%–3%	Periodic US exam Consider repeat FNAB if size increases or change in US feature
III.	Follicular lesion of undetermined significance/atypia of undetermined significance	10%	6%–18%	10%–30%	Correlate with clinical/radiologic findings Consider repeat FNAB ± molecular testing Surgery*
IV.	Follicular neoplasm/suspicious for follicular neoplasm	10%	10%–40%	25%–40%	Consider molecular testing Surgery*
V.	Suspicious for malignancy	3%	45%–60%	50%–75%	Surgery*
VI.	Malignant	5%–6%	94%–96%	97%–99%	Surgery*

\*When surgery is needed, thyroid lobectomy or total thyroidectomy is indicated by clinical and cancer-related variables including molecular testing results and patient preference.

recent reclassification of some neoplasms as NIFTP has altered the risk of malignancy for all cytology categories.<sup>214,215</sup> However, since NIFTP requires surgical excision for diagnosis, malignancy risk can be reported separately either with and without NIFTP<sup>213,216</sup> (see “Pathogenesis and Epidemiology,” “Perioperative Tissue Diagnosis”).

The majority of FNAB results will be benign, with a risk of cancer <4%.<sup>217</sup> Although a higher-than-expected false-negative cytology result has not been observed in all studies, 1 study of routine resection for large size reports a malignancy rate of 12.9% in nodules >4 cm with benign cytology.<sup>38,218–220</sup> It remains controversial if there is a nodule size above which nodules should be definitively assessed by histology rather than cytology.

Cytology that is positive for malignancy is seen in up to 5% of FNAB (see “Pathogenesis and Epidemiology”) and corresponds to histologic PTC, MTC, or ATC.<sup>217</sup> Although cytologic morphology can help differentiate between these cancer types, helpful ancillary studies include immunohistochemical staining for calcitonin or Tg.<sup>3,221</sup> ATC lacks Tg expression and is often clinically distinguishable from DTC. Flow cytometry immunophenotyping is often needed for lesions that are suspicious for PTL but requires a core or surgical tissue biopsy (see “Perioperative Tissue Diagnosis”). Patients should be counseled preoperatively that false-positive malignant FNAB results can occur (<2%).<sup>217</sup>

Nodules that are categorized as follicular lesion of undetermined significance/atypia of undetermined significance (Bethesda III; FLUS/AUS), follicular neoplasm/suspicious for follicular neoplasm/oncocytic neoplasm (Bethesda IV; FN), or suspicious for malignancy (Bethesda V; SFM) comprise at least 20% of FNAB results and are considered cytologically indeterminate (Table 8). The proportion of biopsies classified in 1 of the 3 indeterminate categories increased 4-fold in 2015 compared with ~10 years earlier, which was attributed to the adoption of the Bethesda system along with more stringent recommendations for which nodules should undergo FNAB.<sup>222</sup>

For results in the Bethesda III category, nodules may undergo repeat FNAB, which leads to a more definitive reclassification in 60% to 65%, and thus is recommended as the next clinical management step.<sup>3,223</sup> Diagnostic lobectomy or thyroidectomy is indicated for Bethesda III lesions with suspicious US features,<sup>224,225</sup> cytologic

nuclear atypia,<sup>226,227</sup> and repeat Bethesda III cytology<sup>3</sup> (see “Indications, Extent, and Outcomes of Surgery”). Nodules that are classified as Bethesda IV on cytology are associated with HCC, FTC, or FVPTC, but can also be benign (FA, hyperplastic nodules, etc) (Table 8). MTC can present as FN on cytology.<sup>56,228</sup> To obtain a definitive diagnosis for nodules classified as Bethesda IV requires histologic evaluation to assess for capsular or vascular invasion. The Bethesda V category has the highest risk of malignancy among the cytologically indeterminate categories and is less commonly diagnosed (Table 8). The adjunctive role of molecular testing for nodules categorized as Bethesda IV and V is discussed below (see “Molecular Testing,” “Indications, Extent, and Outcomes of Surgery”).

Before thyroidectomy, review of prior thyroid cytology can be helpful as both inter- and intraobserver variability can be significant.<sup>229</sup> In a review of 7154 thyroid FNABs, discordance between initial interpretation and review was 30%, and the rate was even higher (63%) within the indeterminate categories.<sup>230</sup> In a single institution study of 3885 thyroid cytology specimens, rereview led to a decreased rate of indeterminate results from 38% to 28%. Discordant cytology is associated with low cellularity, an initial indeterminate category, thyroiditis, and low consult volume at the initial institution.<sup>231</sup>

The cytologic features of MTC are variable and overlap with other thyroid pathologies; in fact only ~50% of histologic MTC are diagnosed correctly by preoperative FNAB.<sup>232</sup> The most common variants of MTC are spindle cell and oncocytic, which can be variously interpreted preoperatively as ATC, Hürthle cell neoplasm, or even PTC. In a multicenter study, measuring the FNAB aspiration fluid for calcitonin improved sensitivity of MTC detection.<sup>233</sup>

The preoperative prediction of TC aggressiveness is of increasing interest as this can help guide the extent of initial thyroidectomy. The 2015 ATA guidelines<sup>3</sup> recommend either lobectomy or total thyroidectomy as definitive treatment for TC, but the extent of thyroidectomy depends on estimation of recurrence risk, which is defined predominantly by histologic features that are only available postoperatively. The Bethesda category appears to provide some prognostic information. In a prospective cohort analysis of 1291 patients with histologic TC, higher risk cancers were seen more commonly with a preoperative FNAB result that was positive for malignancy, while lower risk cancers were associated with

FLUS/AUS or SFM;<sup>234</sup> an unfavorable outcome (including local recurrence, distant metastasis, or death) was uncommon but was most likely with malignant FNAB results. In 371 patients with thyroid cancer and an initial FLUS/AUS result, recurrence was rare (3%) albeit with mean follow-up of only 3 years.<sup>235</sup> However, in another single institution study of 360 thyroid cancers, Bethesda category was not predictive of worse outcome within tumor subtypes.<sup>236</sup> Additional studies are needed to better define the potential prognostic implications of the Bethesda system.

**Recommendation 9: The Bethesda System for Reporting Thyroid Cytopathology should be used to report and stratify the risk of malignancy in a thyroid nodule. (Strong recommendation, high-quality evidence)**

## MOLECULAR TESTING

Molecular testing (MT) to examine somatic changes has become an important adjunct in the diagnosis and treatment of many cancers, and is primarily utilized in thyroid disease as a preoperative method to refine the cancer risk of cytologically indeterminate thyroid nodules.<sup>3,237</sup> In development, such testing requires defining the molecular profile of nodules that are benign, malignant, and even nonthyroidal, developing reliable analytic assays to detect these profiles in Clinical Laboratory Improvement Amendments-approved laboratories, and further levels of assessment (below). Molecular profiling includes genomic alterations (such as point mutations, insertions, and deletions), gene fusions resulting in rearrangements or translocations, copy number variations, RNA-based gene expression, and/or micro-RNA (miRNA) expression.<sup>238</sup>

### MT to Guide Need for Surgery

Avoiding surgery for a cytologically indeterminate nodule can be considered if an informed patient wishes and it is clinically appropriate (see “Indications, Extent and Outcomes of Surgery”). Negative MT results can reduce the risk of cancer to one that is approximately equivalent to that for a benign FNAB result ( $\leq 5\%$ ).<sup>239</sup> The type, indication for, and interpretation of MT should consider nodule and clinical variables, and whether the results will change planned recommendations.<sup>240</sup> US and cytology results may help classify risk and determine if surgery is warranted. In addition, if thyroidectomy is indicated regardless of cancer risk ie due to symptoms, imaging features, nodule size etc, then ordering MT for the purpose of avoiding surgery would not be indicated. In some settings, if multidisciplinary management of cytologically indeterminate nodules leads often to observation based on locally available radiographic and cytologic expertise, then the clinical utility of MT may be diminished.

**Recommendation 10: If thyroidectomy is preferred for clinical reasons, then MT is unnecessary. (Strong recommendation, moderate-quality evidence)**

### MT to Guide Thyroid Nodule Management

There have been several versions and types of MT, but currently 3 tests are commercially available. MTs should be evaluated in a systematic framework to ensure that each has analytical validity (how accurately can the test detect if the variant is present or absent), clinical validity (how well does the genetic variant being analyzed relate to the risk of disease), and clinical utility (does the test provide clinically helpful information about diagnosis and treatment).<sup>241</sup> An ideal clinical validation study is multi-institutional, includes histologic correlation for all nodules regardless of MT result, has histology interpreted by a pathologist who is blinded to the MT results, and avoids post hoc exclusions. Sensitivity and specificity are inherent test properties, but clinical use is typically

directed by negative and positive predictive values (NPV, PPV) which are dependent on both test performance and cancer prevalence which is institutionally and geographically variable<sup>242</sup> (see “Pathogenesis and Epidemiology”). The benign call rate, that is, the proportion of FNAB which are MT negative, is a predictor of the number of avoidable diagnostic surgeries and has implications for a test’s real-time clinical utility.

An early form of MT was the 7-gene panel (7GP) designed to evaluate point mutations in *BRAF* (V600E and K601E), *H*-, *K*-, and *N-RAS*, and the *RET/PTC* 1/3 and *PAX8/PPAR $\gamma$*  rearrangements.<sup>243,244</sup> The 7GP included genetic alterations for  $\sim 70\%$  of all thyroid cancers, and in clinical validation studies improved diagnostic specificity and cost savings.<sup>245–251</sup> Under the 2009 ATAG, which advised total thyroidectomy for all DTC, FNAB testing for 7GP was associated with increased rates of correct initial extent of thyroidectomy (lobectomy vs total thyroidectomy).<sup>252</sup> The 7GP is now incorporated into 2 commercially available tests: ThyGenX + ThyraMIR (which combines 7GP with a 10 miRNA panel) and ThyroSeq, which is an expanded multigene panel.

The initial ThyGenX + ThyraMIR clinical validation report was a multisite study inclusive of 109 Bethesda III and Bethesda IV nodules with histopathologic correlation.<sup>253</sup> Cytology and histology were interpreted at the local institution, and pathologists were blinded to the MT results. The cancer prevalence was 32%, and 61% of the cohort had benign MT. Sensitivity and specificity were 89% (73–97) and 85% (76–92), respectively. Two small single institution studies have provided additional clinical validation for the ThyGenX + ThyraMIR test, with one (n=60) reporting a lower sensitivity of 48% (range 27–69)<sup>254</sup> and the other (n=10) reporting a lower specificity of 71%.<sup>255</sup> Clinical utility is not described. The current version has expanded the DNA and RNA panel, and is now called ThyGenNEXT + ThyraMIR; no performance data is available for this iteration.

Two iterations of ThyroSeq have been described in analytic validation studies and both utilize next generation sequencing to identify a panel of molecular alterations. ThyroSeq v2 tested for 56 thyroid-related genes including point mutations, gene fusions, and gene expression, while ThyroSeq v3 expanded the number of tested genes to 112, inclusive of copy number alterations in 10 genomic regions.<sup>256</sup> The benign call rate for ThyroSeq v2 was similar to that for ThyGenX + ThyraMIR and ranges from 65% to 93%.<sup>253,257–259</sup> A multicenter prospective study of ThyroSeq v3 including 247 Bethesda III and Bethesda IV nodules in which both pathologist and clinicians were blinded to MT results reported sensitivity of 94%, specificity of 82% with a cancer prevalence of 28% inclusive of NIFTP, and a benign call rate of 61%.<sup>260</sup>

Using a different MT strategy, the Afirma Gene Expression Classifier (GEC) was an RNA-based panel which was specifically selected to associate with benign nodules.<sup>261</sup> In essence, a negative result ideally obviates the need for surgery. Since the initial analytical validation studies, additional expression markers for MTC, Hürthle cell lesions, *BRAF*, and *RET/PTC* fusions have been added and the newest iteration is now called the Genomic Sequencing Classifier (GSC).<sup>262–264</sup> Clinical validation studies of GEC have been numerous and heterogeneous in design and outcome. The first report was a multi-institution study inclusive of 265 Bethesda III, IV, and V nodules in analysis of GEC test performance.<sup>265</sup> Because the NPV was 85% for Bethesda V nodules due to high cancer prevalence (62%), GEC was no longer performed for this cytologic category.<sup>265</sup> GSC validation used this same cohort of samples, of which 190 Bethesda III and IV nodules had adequate RNA for retesting. Sensitivity was 91% (79–98) and specificity was higher than for GEC at 68% (60%–76%, 95% CI). Follow-up clinical validation

studies of GEC reported relatively consistent sensitivities of 83% to 100%<sup>266–272</sup> but unlike the initial study,<sup>265</sup> the majority of subsequent analyses included only a small proportion of MT negative nodules with histologic correlation or long-term follow-up.<sup>273</sup>

Not all studies limited GEC use to only Bethesda III and IV nodules, and in others, utilization was inconsistent. Both factors may have led to the observed range of GEC specificity (15%–40%) and PPV (14%–58%),<sup>266–269,274–280</sup> Clinical utilization studies of GEC have included cost analyses and reports of observed reductions in necessary diagnostic thyroidectomies.<sup>281–286</sup> Management of positive GEC results is typically diagnostic surgery with varying rates of malignancy expected, depending on the local pretest probability of cancer.

Molecular alterations characteristic of Hürthle cell carcinoma (HCC)s are different than follicular-patterned lesions,<sup>47,287</sup> and MT performance in Hürthle cell neoplasms has been variable to date.<sup>288</sup> Changes incorporated into both GSC and ThyroSeq v3 may improve MT performance in this nodule subset.<sup>260,264</sup>

Few studies have compared performance of >1 MT on either the same set of nodules or within the same institution. In a study that retrospectively obtained multiple MTs (GEC, ThyGenX+ThyraThyraMIR, and RosettaGX which was a 24 miRNA expression classifier that is no longer available) on 10 cytologically indeterminate (Bethesda III–V) nodules with histology, all 3 MT had 100% sensitivity and NPV.<sup>255</sup> In an analysis to determine if clinical management of all biopsied nodules (Bethesda I–VI) was altered by the use of MT (inclusive of GEC, ThyGenX, ThyroSeq, and 7GP), <10% had a change in planned management according to the 2009 ATAG.<sup>289</sup> In a prospective direct single-institution comparison that randomized Bethesda III/IV nodules to GEC versus ThyroSeq v2 MT,<sup>290</sup> the benign call rate differed (ThyroSeq 77% vs GEC 43%); however, not all MT negative nodules had histology. When nodules with histology were assessed, sensitivity for both tests was 100% (NPV 100%), but specificity was lower for GEC (16% vs ThyroSeq 60%). Particularly concerning cost efficacy, clinical validation data that evaluate use of >1 MT on the same nodule are not available.

A summary of the commercially available MTs and corresponding results from the index clinical validation study appears in Table 9.<sup>253,260,264</sup> However, use of MT results to make clinical decisions relies on PPV and NPV which are contingent on regional cancer prevalence for each cytology category.<sup>242</sup> Using sensitivity and specificity from the index studies, the risk of malignancy depending on a positive or negative MT result is shown relative to cancer prevalence in Figure 2.

**Recommendation 11: When the need for thyroidectomy is unclear after consideration of clinical, imaging, and cytologic features, MT may be considered as a diagnostic adjunct for cytologically indeterminate nodules. (Strong recommendation, moderate-quality evidence)**

**Recommendation 12: Accuracy of MT relies on institutional malignancy rates and should be locally examined for optimal extrapolation of results to thyroid cancer risk. (Strong recommendation, moderate-quality evidence)**

## MT to Guide Extent of Surgery

Because it is available preoperatively, some information from MT can be used to guide extent of surgery but clinical variables should also be considered, that is, as stated above, if total thyroidectomy is already indicated, then MT will not alter the extent of thyroidectomy under the current ATAG although under the 2009 ATAG, 7G MT was associated with increased rates of correct initial thyroidectomy.<sup>252</sup> To date, no MT has been studied for surgical guidance under the 2015 guidelines which substantially modified recommendations on the extent of thyroidectomy, so that lobectomy or total thyroidectomy are potential options for 1 to 4 cm TCs<sup>3</sup> (see “Indications, Extent, and Outcomes of Surgery”). To be useful for deciding extent of surgery, a given MT needs to first provide reliable prognostic information. In a single institution study of 1510 TC, aggressive features such as CLNM, distant metastasis, and recurrence were associated with *BRAF* V600E and *RET/PTC*-1 and -3 rearrangements.<sup>291</sup>

*BRAF* V600E, a mutation that was focused upon early in the evolution of MT, has been extensively studied and is associated with more aggressive PTC subtypes, such as the tall cell variant, in addition to other histologic tumor characteristics including CLNM and ETE.<sup>292,293</sup> *BRAF* V600E mutant tumors have also been associated with recurrence, even in PTMC.<sup>294,295</sup> When PTC is solitary and 1 to 4 cm in size, recurrence is more likely with positive *BRAF* V600E (9.5% vs 3.4%).<sup>296</sup> However, not all *BRAF* V600E-positive PTC are associated with aggressive disease. Overall, its prognostic value is limited when histologic features are available to refine risk stratification.<sup>297,298</sup> *BRAF* V600E can be detected by ThyGenX, Afirma GEC, and ThyroSeq. By contrast, *BRAF* K601E is a clinically indolent mutation that should not be confused with *BRAF* V600E.<sup>299</sup>

ThyroSeq and ThyGenX testing can also detect *TERT* promoter mutations which are found in ~10% of TC and are associated with cancer-specific mortality.<sup>300–302</sup> In a case report, aggressive PTC exhibited multiple mutations,<sup>303</sup> and in meta-analysis aggression was associated with coexistent *BRAF* V600E and *TERT* in particular.<sup>304</sup> Testing for *BRAF* V600E and *TERT* promoter mutations is not necessarily recommended for initial risk stratification; however, if MT is available and such mutations are present, they are called out as being associated with increased risk of recurrence in the 2015 ATA Risk classification.<sup>3</sup> Further study will determine if genotype provides information that has not already been obtained clinically, by US imaging, and/or by cytologic classification, as well as determine if altering the initial extent of surgery based on MT results will affect outcomes.

*RAS* mutations have been variably associated with malignancy, a phenomenon that is often the cause of differing specificity values for the MTs that include *RAS* testing (Table 9). In one single-institution series, *RAS*-positive nodules were associated with a 75% risk of malignancy with *HRAS* mutations conferring the highest risk (90%).<sup>305</sup> However, another series reported a *RAS*-associated malignancy risk of only 9%.<sup>258</sup> *RAS* mutation can be seen in several thyroid histologies, including FA, NIFTP, encapsulated and unencapsulated

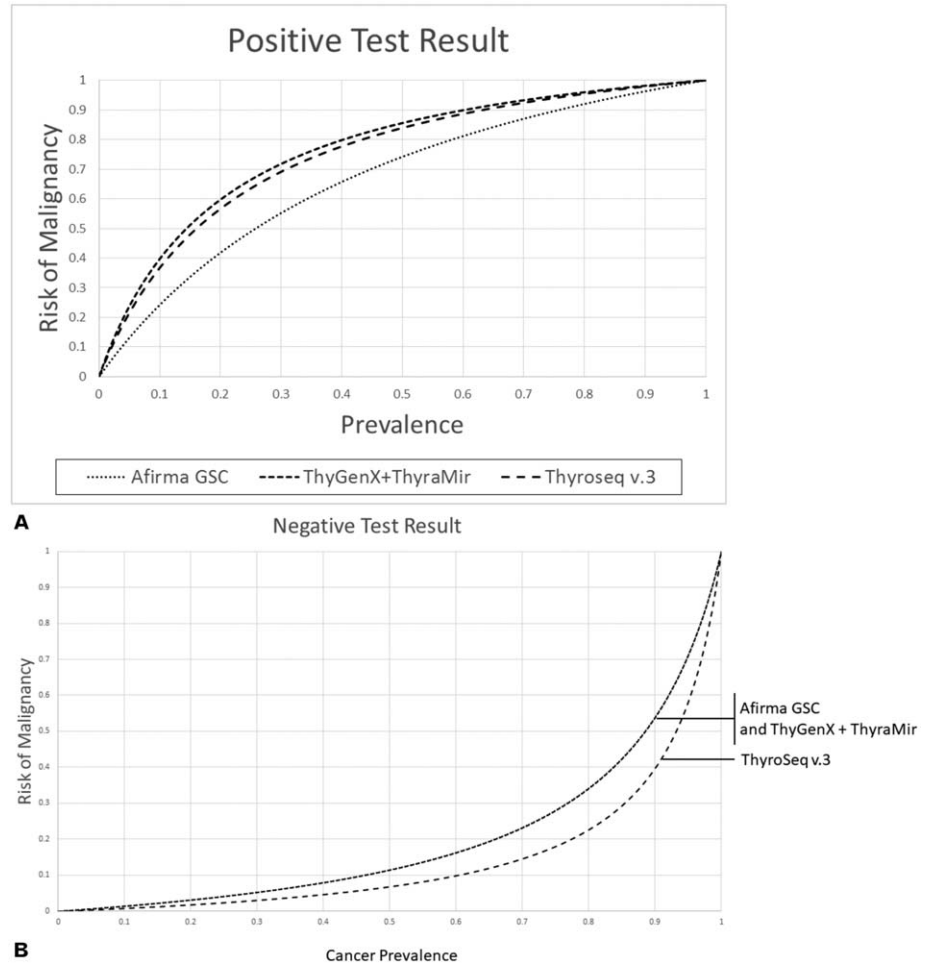
**TABLE 9.** Commercially Available Molecular Tests for Bethesda III and IV Nodules

Test Name	Type of Test	False Negatives*	Sensitivity (95% CI)*	Specificity (95% CI)*
Afirma Gene Sequencing Classifier	Multigene expression (RNA-based)	4/103 (4%)	91% (79%–98%)	68% (60%–76%)
Interpace ThyGenX+ThyraMir	7 gene panel + 10 miRNA	4/67 (6%)	89% (73%–97%)	85% (75%–92%)
CBLPath ThyroSeq version 3	Multigene NGS	4/150 (3%)	94% (86%–98%)	82% (75%–87%)

\*Includes only results with histologic correlation and before post hoc exclusions.

CI indicates confidence intervals; miRNA, micro-RNA; NGS, next-generation sequencing; RNA, ribonucleic acid.





**FIGURE 2.** Risk of malignancy according to test result and cancer prevalence. Figures constructed from published sensitivities and specificities in Table 9.

FVPTC, classic PTC, MTC, and PDTC/ATC.<sup>305,306</sup> The inter- and intraobserver variability associated with diagnosis of follicular-patterned thyroid neoplasms is high and likely accounts for the discrepancy.<sup>307</sup> Regardless, when clonally present, mutant *RAS* is an oncogene, and thyroid lobectomy should be considered for definitive diagnosis as well as definitive management.<sup>238</sup>

### Practical Aspects of MT

All MT types require either at least 1 dedicated FNAB pass (Table 10) or else retrieval of residual material in the needle hub after the FNAB specimen is collected for cytology; the collection vial with the necessary preservative is included in the shipping kits available with each test. An additional patient visit for repeat FNAB can be avoided if the sample for MT is routinely collected at initial FNAB, stored at the local institution, and then submitted for MT when needed. This may not be feasible at some locations but is in routine use at others. Current cost analyses for MT (below) do not include the cost and inconvenience of an additional office visit for MT-dedicated FNAB, when necessary. Although the costs of MT currently do not deviate substantially, most cost-effectiveness modeling studies have been sensitive to small cost fluctuations that can change the study outcome.<sup>245,283,284,308</sup>

### Concerns With MT

Validation and utility studies are needed for all MT. Many reports have relied on retrospective evaluation of initial accuracy

parameters, and follow-up independent studies have often reported diminished utility although in single-institution studies of small cohorts.<sup>266,276</sup> Providers and patients may also find it challenging to interpret MT results and identify the clinical situation where they may be most helpful, potentially leading to over- or under-treatment.<sup>240,289</sup> In clinical scenarios leading to nodule observation, patient willingness or ability to continue surveillance should also be carefully considered before obtaining MT.

The financial aspects of GEC, ThyroSeq, and 7GP have been evaluated in several hypothetical cost-effectiveness analyses.<sup>245,246,265,281,309</sup> In general, the cost of MT can indeed be offset by avoiding surgery, but the costs may equilibrate with long-term clinical surveillance.<sup>308</sup> A better understanding of what malignancies are missed by MT, and the natural history of MT-negative nodules, could help identify which nodules truly require continued follow-up. In a meta-analysis, cost-effectiveness was determined by a number of avoided operations, which was projected based on theoretical estimations for both ThyGenX + ThyraMIR and Rosetta since few clinical validation studies exist for these 2 tests.<sup>310</sup> No MT has been clinically validated for pediatric patients. MT validation and utility studies for Bethesda V nodules are also lacking.

Another variable in evolution that will likely impact MT performance is the recent terminology shift to NIFTP.<sup>311</sup> Molecular analysis has shown the presence of clonal cell populations in NIFTP which may have the potential to be invasive or metastatic<sup>311</sup> but because NIFTP decreases the risk of true malignancy for the

**TABLE 10.** Practical Aspects of Molecular Testing

	Afirma GSC	ThyGenX+ThyraMir	ThyroSeq
Sample type needed	Two dedicated passes	One dedicated pass	One dedicated pass; cell blocks or FFPE can be used
Cytology interpretation Separate FNA	Centralized Selective versus all FNAB sent for centralized cytology review	Centralized or local Selective versus all FNAB sent for centralized cytology review	Centralized or local Selective versus all FNAB sent for centralized cytology review
Specialized kit	Yes	Yes	Yes
Time to test results	Within 2 wks	10–14 business days	Within 2 wks
How test results reported	a. Cytopathology resulted then GSC is evaluated on BIII/IV only b. GSC resulted as Benign or Suspicious c. Additional analysis for <i>BRAF</i> V600E, MTC, <i>RET/PTC1</i> and 3 expression	a. ThyGenX oncogene reported b. If ThyGenX negative, then ThyraMIR assessed and reported as high or low risk	Positive or negative with detailed results for each type of molecular marker tested
Interpretation of MT results	Benign = consider surveillance Suspicious = consider surgery	7GP positive = consider surgery ThyraMIR High = consider surgery ThyraMIR Low = consider surveillance	Negative = consider surveillance Positive = consider surgery

indeterminate Bethesda categories (see “FNAB Diagnosis”) the PPV of all MT will be impacted.<sup>3,12</sup>

**INDICATIONS, EXTENT, AND OUTCOMES OF SURGERY**

The indications for thyroidectomy can be grouped into the general categories of local compressive symptoms, malignancy risk, and hyperthyroidism. For patients who are to undergo thyroidectomy, the initial extent of surgery is determined by multiple factors as discussed throughout these guidelines and summarized in Table 11. The outcomes of thyroid operations, including the impact of surgeon volume, are also presented.

**Extent of Initial Thyroidectomy**

As summarized in Table 11 and addressed below, when an indication for thyroidectomy is present, the surgical decision regarding initial operative extent is driven by multiple factors including symptoms, primary etiology, presence of contralateral nodular disease, thyroid functional status, comorbidities, family history, surgical risk, comparative outcomes, and patient preferences (see “Initial Evaluation,” “FNAB Diagnosis,” “Molecular Testing,” “Initial Thyroidectomy,” “Goiter,” “Reoperation”).

**Cytologically Benign Nodules**

Although the majority of thyroid nodules are cytologically benign on FNAB (Bethesda II) and can be safely observed (see “FNAB Diagnosis”), thyroidectomy should be considered for Bethesda II nodules associated with significant local compressive symptoms such as difficulty with breathing or swallowing. Patients with larger nodules are more likely to report such symptoms,<sup>313</sup> which can be multifactorial and incorrectly attributed to the thyroid (see “Initial Evaluation”). Cross-sectional imaging and other studies may help to delineate whether the nodule is actually compressing the trachea or esophagus.<sup>87</sup>

Progressive enlargement of a nodule classified as Bethesda II is another indication for thyroidectomy. The 2015 ATA guidelines define nodule growth on follow-up US as either a 20% increase in at least 2 nodule dimensions with a minimum increase of 2 mm, or more than 50% increase in volume, and suggest that such patients be offered repeat FNA or resection.<sup>3</sup>

**TABLE 11.** Clinical Factors That Favor Initial Total Thyroidectomy Versus Lobectomy

Favor total thyroidectomy	<ol style="list-style-type: none"> <li>1) Planned RAI for known or suspected DTC, including:                             <ol style="list-style-type: none"> <li>a. Malignant FNAB for &gt;4 cm lesion</li> <li>b. Gross ETE on US or intraoperatively</li> <li>c. Clinical, IOPE or US evidence for CLNM</li> <li>d. Known distant metastasis</li> <li>e. Adverse MT result (ie, BRAF V600E + TERT)</li> </ol> </li> <li>2) MTC</li> <li>3) Bilateral thyroid disease, including:                             <ol style="list-style-type: none"> <li>a. Euthyroid or toxic nodular goiter</li> <li>b. Graves’ Disease</li> <li>c. Contralateral dominant/index nodule</li> <li>d. History of XRT</li> <li>e. Familial predisposition syndrome</li> <li>f. Need for concurrent contralateral parathyroidectomy</li> </ol> </li> <li>4) Struma ovarii</li> </ol>
Controversial/ no consensus	<ol style="list-style-type: none"> <li>1) Uni-lobar known or suspected DTC 1–4 cm that appears low-risk on US</li> <li>2) Index lesion plus existing thyroid hormone dependence</li> <li>3) Uni-lobar DTC with need to facilitate Tg/US surveillance</li> <li>4) Uni-lobar lesion with complex medical situation</li> <li>5) Uni-lobar lesion and patient preference for TT</li> </ol>
Favor lobectomy and isthmusectomy	<ol style="list-style-type: none"> <li>1) Uni-lobar PTMC that appears low-risk on US</li> <li>2) Uni-lobar lesion with indolent MT result</li> <li>3) Unilateral goiter</li> </ol>

When thyroidectomy is already indicated, the listed factors can help inform decision-making about the initial surgical extent, that is, the choice of initial bilateral versus unilateral thyroidectomy. The content is based on the expert opinion of the authors and is not intended to be prescriptive or rotely applicable to individual clinical circumstances (see “Cautions to Implementation,” “Abbreviations Table”).

No absolute threshold for nodule size mandates thyroidectomy, but some routinely consider resection of BII nodules measuring  $\geq 3$  or  $\geq 4$  cm due to a reported increased risk of malignancy (5%–22.8%).<sup>219,314</sup> A 2014 study reported that routine thyroidectomy for 125 Bethesda II nodules measuring  $\geq 4$  cm on US resulted in a 10.4% rate of histologic TC.<sup>219</sup> A 2017 Italian study of 202 patients with solitary BII nodules recommended a 3 cm threshold for operation due to a 22.8% malignancy rate on final pathology.<sup>314</sup> The issue remains controversial due to methodology variations<sup>315</sup> and institutional variations in pathology/cytology analysis.

Some patients with Bethesda II nodules who are otherwise asymptomatic may elect to undergo thyroid resection for cosmetic or other reasons.

### Goiter and Thyroiditis

Most asymptomatic goiters in euthyroid patients can be safely observed, but many surgeons consider surgery for goiter causing dyspnea, dysphagia, tracheal or esophageal compression, or thoracic outlet syndrome, as well as for nodular goiter with substernal extension (see “Goiter”).<sup>87,316,317</sup>

Although most patients with Hashimoto’s thyroiditis are managed medically, surgery is occasionally indicated in thyroiditis patients with significant compressive symptoms, progressive enlargement, or suspicion of malignancy.<sup>24,318</sup> Uncommonly, progressive enlargement of a nontoxic goiter may prompt consideration of resection to prevent future development of symptoms. Some asymptomatic patients may request thyroidectomy because their goiter is cosmetically unappealing.

**Recommendation 13: Patients with a thyroid nodule, goiter or thyroiditis who exhibit local compressive symptoms or progressive enlargement should be considered for thyroidectomy. (Strong recommendation, low-quality evidence)**

### Hyperthyroidism

Antithyroid drug therapy, RAI, and thyroidectomy are all options for management of hyperthyroidism. Each modality has its own advantages and disadvantages, which should be discussed with patients and the multidisciplinary team. Most patients with hyperthyroidism can be managed with antithyroid medications, but some will be refractory to medical therapy, develop adverse reactions, have large glands or nodules not amenable to RAI, have contraindications to RAI, or have coexisting conditions or situations that may prompt consideration for thyroidectomy. Other types of hyperthyroidism may warrant thyroidectomy, including refractory amiodarone-induced thyrotoxicosis,<sup>319</sup> large toxic multinodular goiter,<sup>12</sup> and selected toxic solitary adenomas<sup>320</sup> (see “Hyperthyroid Conditions”).

**Recommendation 14: Thyroidectomy is one of several options for treatment of hyperthyroidism and should be preferentially considered when RAI or medical therapy is contraindicated or undesirable. (Strong recommendation, moderate-quality evidence)**

### Cytologically Malignant Nodules

The stratification of malignancy risk by FNAB and the use of MT to provide additional management information are covered above (“FNAB Diagnosis,” “Molecular Testing”).

Initial risk stratification in TC management is very often performed by the surgeon, who determines (based on imaging, clinical, cytologic, and molecular findings, etc.) whether and when to operate, the initial extent of resection, and what technique(s) to use. In general, patients should be considered for thyroidectomy with an FNAB result demonstrating DTC, MTC, (see “Perioperative Tissue Diagnosis”) or an isolated secondary metastasis to the thyroid

(see “Initial Evaluation”).<sup>3,321,322</sup> In contrast, thyroidectomy is not generally performed for PTL or ATC,<sup>323</sup> although the surgeon may sometimes need to perform an open biopsy to provide tissue to make a definitive diagnosis (see “Perioperative Tissue Diagnosis”). Rarely, thyroidectomy is performed for what is later found to be ATC histologically, or for known ATC that is confined to the thyroid gland.<sup>324</sup>

Active surveillance (AS) may be appropriate for patients with significant comorbidity or limited life expectancy<sup>3</sup> and is also a new option reported for selected patients with small, stable PTC (see “Cancer Management”). Active surveillance requires appropriate patient counseling, selection and a commitment to long-term follow-up.

Several studies have demonstrated that lobectomy for DTC 1 to 4 cm yields disease-specific mortality and recurrence outcomes similar to total thyroidectomy, but there is also continuing controversy.<sup>325–327</sup> A systematic review of 13 large-scaled studies reports comparative survival and disease-free survival outcomes by extent of surgery for PTC 1 to 4 cm. The largest series, using the National Cancer Database, found a 91.4% versus 92.9% difference in overall survival with lobectomy versus total thyroidectomy, but this did not maintain statistical significance with multivariable adjustment.<sup>328,329</sup> In a recent study which compared outcomes for FVPTC versus classical PTC and stratified by size, there was no difference in survival between subtypes by extent of surgery without size stratification; however, in the classical PTC group, patients who underwent total thyroidectomy for larger tumors (2.0 to 3.9 cm) had a significant survival advantage (HRR 1.53,  $P = 0.02$ ).<sup>330</sup> The results of the few studies reporting disease-free survival were mixed, with 3 of 5 reporting increased recurrence but with questionable clinical relevance.<sup>331–335</sup> In further discussion of the initial extent of thyroidectomy, several studies have called into question the oncologic outcomes of the new ATA Guidelines’ focus on lobectomy alone for low-risk DTC.<sup>3</sup> In retrospective studies, a high proportion of patients with apparent low-risk DTC who received TT but would have qualified for lobectomy under the new guidelines, would later have been recommended for completion thyroidectomy (43%, 59%, 49%) because of unanticipated findings such as tall-cell histology, angioinvasion, ETE, positive margins, or positive LN.<sup>336</sup> A 2018 study of actual outcomes following implementation of the 2015 ATA guidelines was more favorable, reporting that 20% of patients with low-risk DTC who underwent initial lobectomy required completion surgery.<sup>337</sup>

For patients with DTC cytology or known/suspected MTC who are to undergo thyroidectomy, the extent of resection is determined by multiple factors (Table 11, see also “Initial Thyroidectomy,” “Cancer Management”). In general, most patients with malignant cytology and tumors  $\geq 4$  cm, evidence of local invasion, nodal or distant metastases, multiple bilateral nodules, or evidence of MTC should undergo total thyroidectomy;<sup>3</sup> the need for possible lymphadenectomy is covered in “Nodal Dissection”. Patients with DTC 1 to 4 cm in size without aggressive cytologic or US features and no other identified reason for initial total thyroidectomy, may be offered ipsilateral lobectomy and isthmusectomy and are less likely to be recommended for postoperative RAI; however, such patients and their referring endocrinologists should be informed that close follow-up of the contralateral lobe and cervical nodal basins is required, that Tg measurements will be difficult to interpret due to remaining thyroid tissue, and that future RAI, if recommended, will first require completion thyroidectomy or 2-stage remnant ablation (see “Cancer Management”). Patients with isolated DTC  $\leq 1$  cm or minimally invasive FTC and no other worrisome radiographic or clinical features such as LNM or local invasion are usually treated with lobectomy alone.

## Cytologically Indeterminate Nodules

The safety and outcomes of active surveillance for management of indeterminate thyroid nodules are unknown.

Conventionally, patients with an FNAB result in the category of Suspicious (Bethesda V; see “FNAB Diagnosis”) should be considered for surgery. As with malignant cytology, the extent of thyroid resection is determined by tumor size, radiographic features, contralateral nodular disease, MT results if performed, and other clinical factors (Table 11).<sup>3</sup> Although it is no longer used routinely, in patients with Bethesda V cytology, intraoperative frozen section may be helpful in diagnosing malignancy and guiding decisions about initial surgical extent (see “Adjuncts and Approaches”).<sup>338</sup>

Patients with a cytologic diagnosis of FN (Bethesda IV) should be considered for MT or thyroidectomy.<sup>253</sup> Thyroidectomy is indicated in patients with larger FN tumors ( $\geq 3$ –4 cm), serial enlargement, worrisome US features, family history of TC, or a history of radiation exposure, and its extent is determined by clinical factors (Table 11).<sup>3</sup> In all other situations, if MT is not performed, or if it produces low yield or suspicious results, thyroidectomy is indicated, and the extent of resection is based on clinical factors.<sup>339</sup>

Patients with a cytologic diagnosis of AUS/FLUS (Bethesda III) may be offered the options of repeat FNA (see “FNAB Diagnosis”), surgery, or MT to assist with further stratification of malignancy risk.<sup>253</sup> If MT is performed and produces low yield or suspicious results, thyroidectomy is indicated with initial extent determined by clinical factors.<sup>339</sup> If MT is not performed, patients with confirmed AUS/FLUS should be considered for thyroidectomy.<sup>339</sup> In some multidisciplinary settings, selected Bethesda III patients without worrisome radiographic or clinical features may be offered the option of AS.<sup>340</sup>

In all cases of indeterminate cytology, patients should receive in-depth discussion regarding the utility and limitations of cytologic analysis, MT (if utilized), the unknown role of active surveillance, and the clinical and radiographic features that also factor into the decision-making process. In some situations, the use of MT may require repeat FNAB (see “Molecular Testing”).

**Recommendation 15: For nodules that are cytologically categorized as Bethesda III, clinical factors, radiologic features, and patient preference should inform decision-making regarding whether to proceed with repeat biopsy, MT, diagnostic thyroidectomy, or observation. (Strong recommendation, moderate-quality evidence)**

**Recommendation 16: Diagnostic thyroidectomy and/or MT are accepted options for patients with nodules cytologically categorized as Bethesda IV. (Strong recommendation, moderate-quality evidence)**

**Recommendation 17: Thyroidectomy is indicated for thyroid nodules >1 cm cytologically categorized as Bethesda V or VI. (Strong recommendation, moderate-quality evidence)**

## Other Situations

Patients with nodules that cannot be biopsied should be considered for thyroidectomy. In addition, patients who have undergone  $\geq 2$  FNAB with inadequate results (Bethesda I) should be offered diagnostic surgery.<sup>341–343</sup> Some thyroid nodules are located in positions inaccessible for FNAB (ie, substernal, posterior, or deep to the internal jugular vein/carotid artery) and should be considered for surgical resection. Some thyroid cysts may require resection.<sup>344</sup> The indications for and extent of initial thyroidectomy may be altered when concurrent surgery for primary hyperparathyroidism is planned (see “Concurrent Parathyroidectomy”). RAI treatment of struma ovarii (a rare ovarian tumor composed of thyroid tissue that may cause hyperthyroidism or present with metastasis) may first require total thyroidectomy.<sup>345</sup>

Medical comorbidities can increase perioperative risks (see “Initial Evaluation,” “Preoperative Care,” “Postoperative Care and Complications”). Strict age or comorbidity thresholds do not exist beyond which thyroidectomy is invariably unsafe. Surgeon judgment and patient selection remain the standards for assuring optimal outcomes, and appropriate preoperative counseling and engagement with other providers are particularly helpful in such instances. The surgeon retains the right to refuse operation if the patient is noncompliant or if the patient’s comorbidities render the operation unsafe.

## Outcomes of Thyroidectomy

Numerous recent reports have demonstrated improved outcomes of thyroidectomy in the hands of high-volume thyroid surgeons,<sup>346–349</sup> including both thyroid-specific complications (hematoma, hypoparathyroidism, RLN injury) and 30-day complications (infection, length of operation, length of hospital stay). A 2017 analysis of the National Inpatient Sample over a 10-year period identified that a surgeon volume threshold of  $>25$  thyroidectomies per year is associated with improved outcomes (coded as reduced short-term complication rates and shorter hospitalization).<sup>350</sup> A 2013 system-wide study of multidisciplinary surgical outcomes reported that surgeons who performed  $\geq 30$  total thyroidectomies per year had improved outcomes for DTC treatment, especially in completeness of thyroid resection.<sup>349</sup> A 2017 review of a nationwide registry in the United Kingdom found that surgeons performing  $\geq 50$  thyroidectomies per year had lower complication rates and shorter lengths of stay.<sup>351</sup> A 2017 study of patients with GD using the National Inpatient Sample demonstrated improved outcomes of thyroidectomy in patients treated at high-volume centers ( $>47$  thyroid operations per year).<sup>2</sup> It should be noted that total thyroidectomy is associated with higher complication rates than lobectomy alone, even in the hands of experienced surgeons (see “Postoperative Care and Complications”).<sup>352,353</sup>

Selected patients with preoperative complaints of dysphagia and dyspnea frequently report reduction in these symptoms following thyroidectomy. A 2012 review of 124 patients utilized a swallowing quality-of-life questionnaire to demonstrate significant improvement following operation,<sup>354</sup> and a 2012 report of  $>1000$  patients queried about positional dyspnea before and after thyroidectomy for goiter identified symptomatic improvement in 82%.<sup>87</sup> Snoring and sleep apnea can also improve after thyroidectomy, but with less complete documentation; a 2012 study utilizing a validated sleep apnea questionnaire demonstrated  $>20\%$  reduction in the number of patients with snoring and/or sleep apnea following thyroidectomy for goiter.<sup>355</sup> In patients with symptomatic thyroiditis, 2 single-institution reports from 2011 demonstrated  $>93\%$  symptomatic benefit in patients undergoing thyroidectomy after failing nonsurgical management.<sup>24,318</sup>

A 2000 meta-analysis of 35 studies involving  $>7000$  patients demonstrated a 92% success rate for subtotal or total thyroidectomy in treating hyperthyroidism.<sup>356</sup> A 2015 review found significantly improved outcomes ( $P = 0.001$ ), for total thyroidectomy (100% resolution of hyperthyroidism) compared with subtotal resection.<sup>357</sup>

**Recommendation 18: When possible, thyroidectomy should be performed by a high-volume thyroid surgeon. (Strong recommendation, moderate-quality evidence)**

## PREOPERATIVE CARE

### Antibiotics

Surgical site infection is a rare complication after routine transcervical thyroidectomy, with a reported incidence of 0.09% to 2%.<sup>358</sup> and in a small European study, preoperative antibiotic administration did not affect its incidence.<sup>359</sup> Antimicrobial prophylaxis

(AMP) for clean surgery of the head and neck was not recommended in a 1999 pharmacy guideline, with moderate strength of evidence.<sup>360</sup> A recent single-institution randomized trial confirmed the safety of clean thyroid and parathyroid surgery without AMP.<sup>358</sup> However, routine AMP is still commonly used for clean thyroid and parathyroid surgeries in Japan and many other countries,<sup>360,362</sup> according to an international survey of 275 endocrine surgeons, 26% administered AMP “almost always”, particularly in Asia (59%).<sup>362</sup> Because both preoperative (obesity, alcohol use) and intraoperative factors (ie, operative time, airway injury) are associated with infection, high-risk patients may benefit from selective use of AMP, in which case gram-positive coverage should be administered before or on induction.<sup>363</sup> With rare exceptions, postoperative AMP is not indicated (see “Postoperative Care and Complications”).

**Recommendation 19: Antimicrobial prophylaxis is not necessary in most cases of standard transcervical thyroid surgery. (Strong recommendation, high-quality evidence)**

### Steroids

As demonstrated in both a meta-analysis and a randomized controlled study, intravenous dexamethasone is associated with a reduction in postoperative nausea and vomiting (PONV) as well as pain after thyroidectomy.<sup>364,365</sup> Higher dexamethasone doses are generally more effective (8–10 mg vs 1.25–5 mg). The timing of administration is also an important factor as the effects of intravenous glucocorticoids are mediated mainly through altered protein synthesis, with an onset of action at 1 to 2 hours, thus dexamethasone given before induction of anesthesia is more effective.<sup>366</sup>

Data are inconsistent about the impact of perioperative steroids on voice outcomes after thyroidectomy<sup>367</sup> and such use is not yet widely advocated. A recent consensus clinical practice guideline made no recommendation regarding the impact of a single intraoperative dose of intravenous corticosteroid,<sup>95</sup> but a recent randomized double blind placebo-controlled trial showed that preoperative administration of dexamethasone (8 mg) reduced rates of postoperative temporary RLN dysfunction and hypoparathyroidism as well as reducing pain, fatigue, and PONV.<sup>368</sup> Similarly, a Swiss double-blind, randomized study showed that a single preoperative 8 mg dose of dexamethasone significantly improved PONV, pain, and postoperative voice function within the first 48 hours (most pronounced within 16 h of thyroidectomy).<sup>369</sup>

**Recommendation 20: Prior to thyroidectomy, in the absence of contraindications, a single preoperative dose of dexamethasone should be considered to reduce nausea, vomiting, and pain. (Strong recommendation, high-quality evidence)**

### Surgical Preparation for Graves' Disease and Hyperthyroidism

Thyroid storm may be precipitated by anesthetic agents, the stress of surgery, or thyroid manipulation and may be prevented by pretreatment with antithyroid drugs (ATDs). Whenever possible, thyrotoxic patients should be rendered clinically and if possible, medically euthyroid before undergoing surgery<sup>13</sup> (see “Hyperthyroid Conditions”). TSH levels will lag behind clinical improvement. If a euthyroid state cannot be achieved prior to surgery, the most important factor to control is the heart rate, using beta blockers to achieve a target rate less than 90 as this will help mitigate cardiac effects.

In GD, use of preoperative potassium iodide (KI, given as SSKI or as Lugol solution) is frequently advised. This treatment is controversial but has staunch adherents, with recent strong evidence that SSKI beneficially decreases thyroid blood flow, vascularity, and intraoperative blood loss<sup>370–372</sup> and also beneficially blocks conversion of T4 to T3.<sup>373</sup> Conversely, in a study comparing 162 patients

with GD to 102 patients with TMNG, none of whom received SSKI preoperatively, no differences were observed in operative time, blood loss, or complications and the authors concluded that omitting preoperative SSKI for GD patients does not impair outcomes.<sup>374</sup> These findings serve to mitigate concern when KI is not given because of scheduling issues, shortage, allergic reactions, intolerance, etc. KI can be given as 5 to 7 drops (0.25–0.35 mL) of Lugol solution (8 mg iodide/drop) or 1 to 2 drops (0.05–0.1 mL) of SSKI (50 mg iodide/drop) 3 times daily in water or juice for 7 to 10 days before surgery (see “Hyperthyroid Conditions”).

In exceptional circumstances when it is not possible to render a patient euthyroid, when the need for thyroidectomy is urgent, or when the patient is allergic to ATDs, the patient should be treated with beta-adrenergic blockade, KI, glucocorticoids, and potentially cholestyramine in the immediate preoperative period.<sup>13</sup> Rarely, plasmapheresis may be required if other measures cannot control the thyrotoxic state.<sup>375</sup> Plasmapheresis and plasma exchange are best used for short-term control followed by immediate thyroidectomy. It is best if the surgeon and anesthesiologist have experience in this situation.

**Recommendation 21: If surgery is chosen as treatment for GD:**

- Ideally patients should be rendered clinically euthyroid preoperatively. (Strong recommendation, low-quality evidence)**
- A potassium iodide containing preparation can be considered prior to surgery. (Weak recommendation, low-quality evidence)**

### Vitamin D and Calcium

Before total or reoperative thyroidectomy, patients who have had prior gastric bypass surgery should be counseled about a higher risk of severe postoperative hypocalcemia. Roux-en-Y gastric bypass surgery circumvents most of the stomach, duodenum, and proximal jejunum, thereby limiting the ability to absorb calcium and vitamin D,<sup>376</sup> with calcium citrate being the type that is best absorbed. The incidence of refractory hypocalcemia following thyroidectomy in patients who have undergone prior gastric bypass may be underreported<sup>377</sup> and if uncorrected can even necessitate bypass reversal,<sup>378</sup> thus vitamin D and calcium stores should be aggressively repleted (see also “Postoperative Care and Complications”). In addition, the residual equivalent of 1 normal parathyroid may not be sufficient to maintain normocalcemia, which has been proposed as a reason to preferentially consider lobectomy or to use a staged approach.<sup>379</sup>

**Recommendation 22: Gastric bypass patients should be counseled about a higher risk of severe postoperative hypocalcemia after total or completion thyroidectomy. (Strong recommendation, low-quality evidence)**

Hypercalcemia in a patient scheduled to undergo thyroidectomy should be further evaluated preoperatively (see “Concurrent Parathyroidectomy”). Vitamin D deficiency is a probable risk factor for postoperative hypocalcemia following total thyroidectomy, and in randomized but nonstratified studies, symptomatic hypocalcemia was less frequent in patients treated with perioperative oral calcium and vitamin D.<sup>380,381</sup> Calcium and vitamin D administration should be considered prior to thyroidectomy for patients at risk for hypocalcemia.

Similarly, recent data for GD suggest that preoperative supplementation of oral calcium and/or vitamin D may reduce the post-thyroidectomy risk of hypocalcemia. A prospective study compared 45 GD patients treated with oral calcium carbonate (3 g a day for 2 wks) to 38 GD patients who underwent thyroidectomy without treatment and to 38 euthyroid controls, and found that rates of biochemical and symptomatic hypocalcemia were higher in non-treated GD patients.<sup>382</sup> Again in GD, a meta-analysis identified both

preoperative vitamin D deficiency and GD itself as risk factors for postoperative hypocalcemia and advised that calcium and 25-hydroxy vitamin D levels be preoperatively assessed, and prophylactically repleted or supplemented.<sup>383</sup> This topic warrants further systematic study.

**Recommendation 23: Prior to thyroid surgery for GD, calcium and 25-hydroxy vitamin D levels may be assessed and repleted or supplemented prophylactically. (Strong recommendation, moderate-quality evidence)**

### Universal/Standard Consent and Counseling

Informed consent consists of 5 basic elements: voluntarism, capacity, disclosure, understanding, and ultimate decision-making.<sup>384</sup> Valid consent requires that a patient be given the information about risks, benefits, and alternatives to surgery and offered the opportunity to have questions answered prior to making a decision about whether to have surgery. The counseling discussion also helps patients manage their expectations, handle any consequences and/or complications that may arise,<sup>385</sup> and can also help to avert unnecessary emergency visits and patient anxiety. Many factors affect understanding and information retention<sup>386</sup> and the act of signing consent paperwork alone does not correlate well with understanding the comprehensive picture.<sup>387</sup> To enhance verbal communication, many thyroid surgeons thus use means such as pamphlets, datasheets, and multimedia or web-based interactive media to enhance perioperative patient learning.

When obtaining consent for surgery, trainees are often unable to provide patients with full descriptions of the risks, benefits and alternatives, or to correctly answer questions.<sup>388</sup> We advise that 1) patients be informed by the operating surgeon of the major risks specific to thyroidectomy and surgery in general, including injury to the laryngeal nerves resulting in temporary or permanent changes in voice; injury to the parathyroids resulting in hypocalcemia and the need for temporary or permanent medication; infection; bleeding resulting in return to the operating room, hypothyroidism requiring chronic medication, and other patient-specific factors; 2) patients be informed about recommendations for postoperative narcotic use (below), and 3) the consent process be documented clearly in the patient's chart.

### Venous Thromboembolism (VTE) Prophylaxis

Although VTE prophylaxis has become relatively routine in surgical procedures that are longer, more physiologically extensive and/or followed by bedrest, it remains controversial for routine thyroidectomy. Not only is the risk for VTE after thyroidectomy quite low (0.02%–0.2%) but also any postoperative hemorrhage may cause acute airway compromise requiring emergency decompression (below) thus many thyroid surgeons believe that the risk of bleeding outweighs the benefits of VTE prophylaxis.<sup>389–391</sup> In a large NSQIP study, the rate of VTE after thyroid and parathyroid operations was 0.16% and the authors concluded that VTE prophylaxis should be reserved for patients determined to be at high risk.<sup>389</sup> Immediate postoperative ambulation is routinely utilized after thyroidectomy.

**Recommendation 24: Chemical VTE prophylaxis should be reserved for selected patients determined to be at high risk for VTE after thyroidectomy. (Strong recommendation, low-quality evidence)**

### Interdisciplinary Communication

Communication among healthcare professionals is one of 9 notable ways to improve patient safety, and communication lapse is one of the most common causes of a sentinel event.<sup>392</sup> However, in thyroid surgery there is no universally accepted model for transmission of perioperative information. A recent study designed checklists

for different stages of the care process.<sup>392</sup> In addition, the ATA Surgical Affairs Committee suggested an essential perioperative dataset of critical information that should be readily available to the multidisciplinary team,<sup>393</sup> noting that these findings are acquired and discussed in 3 distinct settings: preoperative evaluation (see “Initial Thyroidectomy”), intraoperative findings, and postoperative data, events and plans. While optional, the ATA authors also noted that synoptic surgical reporting can facilitate systematic documentation.<sup>393</sup> Mutual multidisciplinary communication is an important component of optimal patient care and should be systematically encouraged.

### INITIAL THYROIDECTOMY

Except for survival data for DTC and MTC by initial surgical extent (see “Indications, Extent, and Outcomes of Surgery”) there is a paucity of data on the comparative outcomes of various types and techniques of thyroidectomy. Establishing common principles and terminology for safe, effective thyroidectomy is a critical component of these guidelines and allows for informed communication with patients and other physicians. Here, we discuss the conduct of initial thyroidectomy.

### Nomenclature

Descriptions of commonly used nomenclature for thyroidectomy are shown in Table 12, which also attempts to clarify the specific definitions of near-total and subtotal thyroidectomy as these differ historically and among experts today.

Partial thyroid lobectomy (“nodulectomy”) alone is not recommended, but rarely may be necessary during other cervical procedures such as tracheostomy. Lobectomy and isthmusectomy (or rarely an isthmusectomy alone) is the minimum extent of surgical resection in most cases of malignancy. During planned total thyroidectomy, the surgeon may choose to perform near-total resection by leaving a very small amount of thyroid tissue (for example, at the ligament of Berry) when the RLN is felt to be at risk. However, whether unilateral or bilateral, subtotal thyroidectomy is rarely recommended in the US except in highly unusual circumstances when intended to preserve thyroid, RLN, and/or parathyroid function.<sup>394</sup>

Whether it is done inadvertently or by intent, the most common sites of incompletely resected thyroid tissue are at the pyramidal lobe, the ligament of Berry, superior pole, and in the tracheoesophageal groove.<sup>395</sup> Failure to completely resect in situ thyroid tissue can also occur at the thoracic inlet. Particularly when performing thyroidectomy for malignancy, meticulous attention to removal of all tissue in these areas is recommended.

**TABLE 12.** Thyroidectomy Nomenclature

Name of Procedure	Extent of Resection
Lobectomy	One entire thyroid lobe without isthmus
Lobectomy and isthmusectomy	One entire thyroid lobe with isthmus and pyramidal lobe
Isthmusectomy	Isolated isthmus resection
Subtotal thyroidectomy	Preservation of small posterior remnant(s) of the contralateral or bilateral lobe(s) (Rarely recommended today)
Near-total thyroidectomy	Resection of all but a very small posterior remnant, ie, at the ligament of Berry
Total thyroidectomy	All visible thyroid tissue
Completion Thyroidectomy	Reoperative resection of any remaining thyroid tissue

## Surgical Planning

Except for rare circumstances, thyroidectomy is an elective procedure that occurs once the dual decisions are made that surgery is indicated and the patient is medically optimized in all the areas detailed above. Planning about the extent of initial thyroidectomy is covered in “Indications, Extent, and Outcomes of Surgery”. Imaging studies should be reviewed and, when possible, be available to view in the operating room (see “Imaging”). Interdisciplinary communication is essential, especially when treating patients with hyperthyroidism, large substernal goiters, or airway compromise (see “Preoperative Care”). A plan for managing a potentially difficult airway should be discussed with anesthesiology beforehand so that appropriate expertise and equipment are available. A surgical timeout improves team coordination, safety, and outcomes.<sup>396,397</sup> If a nerve monitor is being used (see “Laryngology”) one should verify the equipment is available and functioning and that only short acting neuromuscular blockade is used by anesthesiology for intubation.

While vessel ligation technique, types of suture, choice of retraction devices, and use of adjuncts (see “Adjuncts and Approaches”) may vary between surgeons (below) certain elements are critical to all safe and effective thyroidectomies.

## Positioning, Incision, and Exposure

Following successful intubation, the patient is generally placed in a semi-Fowler position with a bump (ie, rolled blanket, inflatable device, padded IV bag, etc) under the shoulders to extend the neck. Adequate neck access is important for exposure and is often impacted by body habitus. Over-extending the neck may be associated with increased postoperative pain.<sup>398</sup> It is important to ensure that the endotracheal tube is secured and out of the operative field. Pressure points should be padded, and the skin prepared and draped.

A transverse centered incision is made, preferably in a natural skin crease for optimal cosmetic results. The use of local anesthetic is at the discretion of the surgeon. Incisional positioning will vary according to patient habitus and surgeon preference but is generally rostral to the sternal notch and caudal to the cricoid cartilage. Incision length will be dictated by body habitus and thyroid size. Subplatysmal skin flaps are developed by some surgeons superiorly to the thyroid cartilage and inferiorly to the sternal notch.

Next, the median raphe is opened to begin mobilization of the sternohyoid and sternothyroid muscles away from the underlying thyroid. Although the strap muscles are usually retracted laterally and preserved, improved exposure of the superior pole by transection of the laryngeal head of the sternothyroid muscle and/or en bloc resection of cancer-invaded muscle, may be required on occasion.

## Critical Steps of Thyroid Dissection

The order of critical steps will vary based on surgeon preference, disease process, and patient anatomy. In general, thyroidectomy proceeds through tissue planes that deepen from a ventral to dorsal direction, while the overlying strap muscles are dissected in a medial to lateral direction away from the underlying thyroid capsule toward the carotid sheath.

The middle thyroid vein, which is often identifiable on the ventral surface of the thyroid lobe, is ligated and divided, allowing medial mobility of the lobe to gradually expose the tracheoesophageal groove. As the lobe is mobilized and rotated medially, its fine (ancillary) blood supply is isolated and divided. The inferior parathyroid is usually seen on or near the inferior thyroid capsule and typically resides anterior and medial to the RLN. It should be dissected away from the thyroid capsule with care being taken to

preserve the parathyroid capsule, lateral attachments and blood supply.

As dissection deepens, many experts routinely clear off the trachea inferior to the isthmus and superiorly, and dissect the pyramidal lobe with care taken to preserve the cricothyroid muscle fibers. The prelaryngeal “Delphian” lymph node(s) if present should be removed in cases of suspected or known malignancy and sent for pathologic review either as a frozen section (if this will change the extent of surgery) or with the thyroid specimen.

It is important to expose and resect in continuity the entire superior thyroid pole. Further exposure is obtained following ligation of the superior pole vessels, which is performed by inferolateral retraction of the superior pole together with dissection to isolate the vascular pedicle, which often arborizes on the anterior superior capsule. Both ligation of the superior pole vessels close to the thyroid capsule and consideration of the distance/heat of an adjunctive energy source will help to protect the external branch of the superior laryngeal nerve (EBSLN). The EBSLN may be visually identified at the inferior edge of the inferior constrictor muscle. If a nerve monitor is being used, the fibers being considered for transection may be stimulated prior to dividing the superior pole vasculature to help protect the EBSLN.

**Recommendation 25: The superior pole vessels should be ligated close to the thyroid capsule to avoid potential EBSLN injury. (Strong recommendation, insufficient evidence)**

A critical step is identification and protection of the RLN. Its course ideally should be visualized through the entire operative field and kept in view to assess for tension during medial retraction of the thyroid lobe. It usually runs in a superior-medial path passing posterior to the inferior thyroid artery, tubercle of Zuckerkandl (if present) and deep to or through the posterior suspensory ligament (ligament of Berry) before entering the larynx just deep to the lower border of the inferior constrictor muscle and posterior to the cricothyroid articulation. The path of the RLN can be variable, for example, it can pass anterior to the tubercle, and it can also branch at any point in its course. There are several ways to initially identify the RLN including at the thoracic inlet, in the tracheoesophageal groove, and at the laryngeal entry point. Whenever possible, RLN integrity should be protected with delicate, careful dissection that avoids tension and traction, taking caution in using a thermal device along its course. After the tubercle of Zuckerkandl (if present) is mobilized, the ligament of Berry should be divided as close to the trachea as possible without putting the RLN at risk. The most common site of RLN injury is at the ligament of Berry.<sup>399</sup> Routine RLN identification improves outcomes<sup>400</sup> (see “Laryngology”).

**Recommendation 26: The RLN should be identified to help preserve it. (Strong recommendation, low-quality evidence)**

The superior parathyroid should be carefully preserved in situ. Compared with the inferior parathyroid, the superior gland lies anatomically posterior to the RLN and is often identified superior-lateral to the intersection of the inferior thyroid artery and RLN. However, the relationships between the inferior thyroid artery, RLN, and superior parathyroid can be quite variable. Whenever possible, parathyroid glands that lie within the superficial thyroid capsule should be dissected free and preserved with their blood supply intact. If no parathyroid glands are identified, then inspection of the thyroid specimen capsule is reasonable. Whenever feasible it is ideal not to enter the thyroid capsule during dissection.

If the blood supply to a parathyroid gland is compromised, parathyroid autotransplantation should be strongly considered. In the uncommon case that a parathyroid is potentially involved with cancer

or level VI lymph nodes, after attention is paid to other viable parathyroid tissues the involved parathyroid may be taken en bloc. One way to perform autotransplantation is to sharply mince the devascularized parathyroid and place the tissue into a suture- or surgical clip-marked intramuscular pocket, commonly in the ipsilateral sternocleidomastoid (SCM). Alternatively, it can be placed contralateral to a known cancer, and/or into strap muscles.<sup>6</sup> Prior to autotransplantation it can rest briefly in cold sterile saline and it is reasonable to obtain an intraoperative pathologic evaluation (IOPE) to confirm parathyroid tissue identity (see “Perioperative Tissue Diagnosis”).

**Recommendation 27:**

- a. **Dissection should be performed along the thyroid capsule to help preserve the parathyroid glands. (Strong recommendation, low-quality evidence)**
- b. **If a parathyroid gland cannot be preserved, parathyroid autotransplantation should be performed. (Strong recommendation, low-quality evidence)**

As the RLN is traced, the inferior pole vessels are dissected and ligated while taking care to preserve the blood supply to the inferior parathyroid gland. Usually division of the inferior vascular pedicle will complete the lobar mobilization, but care should be taken to detect, deliver, and resect a substernal thyroid component if present (see “Goiter”).

The pyramidal lobe should be identified and resected during total thyroidectomy, and if a thyroid lobectomy and isthmusectomy is being performed, the pyramidal lobe should be identified and resected en bloc with the lobe. The isthmus is likewise taken in continuity and provides the medial margin of resection.

The specimen should be oriented for pathologic examination, typically with a suture placed to mark the superior pole to facilitate correlation with cytology and/or imaging. Any area of concern or query, such as gross extrathyroidal extension, should also be identified for the pathologist. Specimens are submitted for permanent section unless frozen section analysis is being used to guide the operative approach (see “Adjuncts and Approaches”).

If it is indicated to proceed to the contralateral lobe for total thyroidectomy, the surgeon can leave the ipsilateral lobe in situ or transect it at the isthmus. The same steps are then performed to mobilize and resect the contralateral thyroid lobe.

Prior to closure, a dry, bloodless field should be verified. Some surgeons have the anesthesiologist perform positive pressure ventilation to help assess for venous bleeding. Hemostatic agents have unclear benefit (see Adjuncts and Approaches). Drains are rarely used; a meta-analysis of >2000 patients reported that drain use after thyroidectomy was associated with no differences in reoperation rate, hematoma, or seroma formation- while also associated with increased pain and a trend for increased wound infection.<sup>401</sup> Various suture materials and techniques are used for approximation of the strap muscles, platysma, and dermis, all with similar results. Postoperative antibiotics are not indicated in thyroid surgery. The operative report should include standard recommended detail and features<sup>393</sup> (see “Postoperative Care and Complications”).

### Additional Considerations in Thyroidectomy for Cancer

In patients with known DTC or MTC, or with a suspicion of cancer, there are some additional technical considerations: 1) Preoperative FNA can cause an inflammatory reaction that mimics local invasion; when encountered, visible inflammation should be documented in the operative report; 2) Ipsilateral inspection and potential dissection of abnormal prelaryngeal (Delphian node), pretracheal,

and paratracheal lymph nodes is recommended (see “Nodal Dissection”); 3) If surgical clips are used for vessel ligation, titanium is the preferred metal as other types can affect the quality of future cross-sectional imaging; 4) Dissection and removal of the pyramidal lobe should be done as completely as possible; 5) Although the precept is debated, many surgeons prefer to approach the lobe with cancer first, thus preserving the option of limiting the operation to that side in the event of observed injury to the RLN; 6) For adequate oncologic management, an en-bloc resection is necessary with removal of all gross (visible) tumor; thus if there is suspicion for extrathyroidal or extracapsular extension of tumor into the surrounding strap muscles, these tissues should be taken with the specimen. Gross thyroid cancer should not be left behind with the intent of preserving parathyroid glands or nerves with the expectation that RAI will kill residual disease, and the risks and benefits of leaving residual tumor to preserve a functioning nerve are considered on a case by case basis; 7) During lobectomy, it is important that the resection include the isthmus as well as the entire Tubercle of Zuckerkandl unless doing so jeopardizes the RLN; 8) If cancer involves the RLN, the surgeon should consider its preoperative functional status to help decide between shaving tumor from a functioning nerve versus resecting a nonfunctioning nerve (see “Laryngology”); 9) In the rare event of unexpected tracheal involvement, the surgeon may need to seek experienced assistance i/n obtaining a grossly negative margin, which may involve tangential shaving of tumor, or consider tracheal sleeve resection after interval assessment and patient consent.

## PERIOPERATIVE TISSUE DIAGNOSIS

### Core Needle Biopsy of the Thyroid and Cervical Lymph Nodes

FNAB is the first line of investigation for suspicious thyroid nodules and cervical lymph nodes, but has nondiagnostic results in 5% to 15% of cases (see “FNAB Diagnosis”).<sup>212,384,402</sup> Alternative methods of diagnosis must balance high yield with ease of performance and safety, as well as cost, expertise, and patient comfort. Core needle biopsy (CNB) examines a tissue sample, rather than dissociated cells and colloid, and is associated with few complications when performed by experienced operators<sup>403,404</sup> but has a sensitivity of only 68% for thyroid nodules.<sup>405</sup> Moreover, due to the need to examine the lesional capsule on histology, CNB cannot distinguish FA from FTC. However, when FNAB is nondiagnostic, CNB may yield a higher rate of diagnosis than repeat FNA.<sup>405</sup>

CNB may also serve as a primary method for diagnosis for suspected PTL and ATC. Both are aggressive malignancies for which thyroidectomy is rarely indicated, making a noninvasive diagnostic approach ideal. Most studies are retrospective single-institution experiences with sensitivities in diagnosing PTL of 93% to 95% for CNB versus 45% to 71% for FNAB, and in diagnosing ATC of 77% versus 54%, respectively.<sup>407,408</sup> Because the 2008 WHO classification bases PTL diagnosis on morphologic features as well as immunophenotypic, cytogenic, and molecular profile,<sup>409</sup> and cellular yield for flow cytometry may be higher by FNAB than by CNB, CNB is often considered second-line for flow cytometry. In handling CNB tissue, if PTL is considered as a possible diagnosis, a portion of the fresh sterile core is teased to release cells into a transport medium such as Roswell Park Memorial Institute media, to be sent for flow cytometry (if not already performed by FNAB). The remainder of the tissue core is placed in formalin. Molecular analysis of CNB specimens is also possible (see “FNAB Diagnosis”).

**Recommendation 28: Core needle biopsy should be rarely utilized in the initial evaluation of a thyroid nodule. (Strong recommendation, low-quality evidence)**



## Incisional Biopsy of the Thyroid and Incisional/Excisional Biopsy of Cervical Lymph Nodes

In selected, unusual circumstances an incisional biopsy of thyroid tissue may be required to make a definitive diagnosis and is usually reserved for patients with PTL who cannot be appropriately subtyped or with ATC who cannot be definitively diagnosed by FNAB or CNB. Excisional or rarely incisional biopsy of a cervical LN should be reserved for when a thyroid-related diagnosis cannot be obtained otherwise. Incisional biopsy should only be considered if the LN is large and additional morbidity would be incurred by resecting it entirely.

## Intraoperative Pathologic Evaluation of the Thyroid

IOPE of the thyroid is typically performed by frozen section analysis (FSA) and/or cytologic touch or scrape analysis. It may be utilized in thyroidectomy to assure adequacy of tissue collection in the setting of an unknown diagnosis (above) as well as for clarification of tissue type and margin status (below). FSA should not be used when it could be deleterious, such as in the setting of a small lesion that would necessitate being frozen in its entirety with tissue loss preventing a diagnosis on final pathology.

IOPE has been often studied for its ability to predict final histopathology. Unfortunately, this ability is reportedly quite low, moreover (as with CNB) FSA is not informative for follicular neoplasms<sup>410,411</sup> since the histologic characteristics of FTC and HTC require detailed analysis of the tumor capsule and vasculature for invasion, which is not practical or feasible in an intraoperative setting.<sup>412</sup> Given that only the assessment of nuclear features is required to diagnose PTC, IOPE may be useful in cases where PTC is suspected and its diagnosis would change the extent of operation.<sup>410</sup> When PTC is diagnosed preoperatively by FNAB, IOPE is not recommended or useful.

Recently, IOPE has been suggested for use in determining extrathyroidal extension of tumor, which may lead to a change in operative plan,<sup>413</sup> but this single-institution observation needs further investigation. Although negative macroscopic margins are usually the goal of TC resection, IOPE may also be utilized for evaluation of margins to assist in complete tumor extirpation, such as at interface with the trachea. However, data to evaluate whether IOPE accurately predicts margin status on final pathology or changes the extent of operation are lacking.

**Recommendation 29:** *Thyroid IOPE should only be utilized in settings in which the information it provides has a high likelihood of altering the operative procedure. (Strong recommendation, low-quality evidence)*

## Intraoperative Pathologic Evaluation of CLN and Parathyroid Tissue

IOPE of a cervical LN can confirm its identity versus parathyroid tissue or extrathyroidal thyroid tissue, can help determine whether it harbors malignancy, and in both situations, may change the extent of operation. In a meta-analysis examining the use of IOPE to identify metastatic adenopathy during TC surgery,<sup>414</sup> among 242 LN without malignancy on IOPE, a positive result was diagnosed on final histology in 12%; the majority of the false negative cases were from studies utilizing LN immunohistochemical analysis (a rare practice) and/or represented metastasis. Several issues of IOPE pathologic expertise include 1) psammoma bodies without epithelium in an LN can represent metastasis thus should not necessarily be considered as negative; 2) with significant thyroiditis at the time of LN IOPE, there is potential for a false-positive read with the specimen sent as an LN in actuality being a sequestered, or parasitic, thyroid nodule which occurs when nodules of hyperplastic thyroid

obtain an independent blood supply and become separate from the main gland; 3) IOPE artifact can also cause intranuclear inclusions similar to those of PTC when a true LN should contain lymphoid follicles, a capsule, and a subcapsular sinus.

During thyroidectomy, the distinction of parathyroid tissue from LNs, thyroid nodules, and fatty tissue may be challenging. In a large retrospective review comparing 1579 cervical FSA to final pathologic diagnosis, the overall accuracy rate of distinguishing parathyroid from nonparathyroid tissue was 99.2%.<sup>415</sup> In situ or ex vivo PTH aspiration analysis can also be used to identify parathyroid tissue.<sup>416</sup>

**Recommendation 30:** *IOPE has value in confirming identification of parathyroid tissue. (Strong recommendation, moderate-quality evidence)*

**Recommendation 31:** *IOPE has value in identification of CLN metastases when the information may alter extent of surgery. (Strong recommendation, moderate-quality evidence)*

## Final Histopathologic Diagnosis

Interobserver variation in interpretation of final histopathologic diagnosis is not uncommon. In evaluation of 776 thyroid nodules, expert interobserver concordance of benign versus malignant thyroid disease was 90.3% (95% CI, 88.0%–92.3%),<sup>26</sup> concordance between the local histopathologist and final expert consensus was 90.7% (95% CI, 88.5%–92.7%), and the most disagreement seen was in diagnosis of FTC and HTC (61%). The determination of malignancy type is also subject to observer variance; that is, minimal extrathyroidal extension (ETE) and extranodal extension are PTC features that predict disease biology but in a recent study, the interobserver concordance among expert pathologists was poor for ETE (kappa coefficient of 0.14), and fair for extranodal extension (kappa coefficient of 0.35) suggesting the need for standardized criteria.<sup>417,418</sup> In single-institution studies a second histopathologic opinion commonly alters clinical treatment. When 66 specimens were reread at a tertiary center with a thyroid multidisciplinary focus, disagreement led to a change in the assessed prognosis for 10% of patients, and strong disagreement led to change of therapy for 8%.<sup>419</sup> To summarize, second reads of thyroid histopathology should be performed when the initial pathologist is uncertain of the diagnosis and at the discretion of the clinician or patient, and also should be strongly considered for difficult diagnoses, such as FTC and NIFTP.

The surgeon and pathologist should establish mutual expectations of how tissue specimens are to be optimally received by the pathologist, the typical length of time for a diagnosis to be rendered, and the communication plan for patients in instances that require further time for evaluation.

## Benign Lesions of the Thyroid

Follicular-patterned nodular hyperplasia can exhibit complete or partial encapsulation and often contains a combination of macro- and microfollicles. The nodules may display a variety of degenerative changes including fibrosis and hemorrhage. Consistent histopathologic criteria distinguishing hyperplastic nodules from FA are lacking. Classically, FA is a single encapsulated lesion in an otherwise normal gland that lacks any vascular or capsular invasion and has a distinct growth pattern (microfollicular, macrofollicular, or trabecular).<sup>420</sup>

## Differentiated Thyroid Carcinoma

DTC arises from the thyroid follicular epithelial cell. Classic PTC is diagnosed by its nuclear features which include enlargement, oval shape, elongation, and overlapping.<sup>421</sup> The nuclei usually display clearing and irregular contours, including grooves and nuclear pseudoinclusions. A papillary architecture is often present

and complex with branching, though if absent, the diagnosis of PTC may rely upon nuclear features alone. PTCs are immunoreactive for cytokeratins, thyroglobulin, and thyroid transcription factor-1 and negative for chromogranin A and synaptophysin.

Variant types of PTC (Table 13) include FVPTC, which is composed of neoplastic follicles, rather than papillae, and has 2 main subtypes: infiltrative (or nonencapsulated) and encapsulated (EFVPTC). Infiltrative FVPTC has absent or incomplete encapsulation with tumor penetrating non-neoplastic thyroid parenchyma.<sup>422</sup> EFVPTC was recently evaluated with a distinction made between invasive and noninvasive EFVPTC, and the latter was reclassified by a new nomenclature as noninvasive follicular thyroid neoplasm with papillary-like features (NIFTP) [<sup>311</sup>, below]. Other PTC variants include columnar cell, tall cell, cribriform morular, diffuse sclerosing, and hobnail.

FTC is an invasive neoplasm of follicular cell origin characterized by follicle formation without the typical nuclear features of PTC. FTC is categorized by two main features: 1) capsular invasion, defined by tumor penetration through the tumor capsule and not affiliated with previous FNA site, and/or 2) vascular invasion.<sup>421</sup> Minimally invasive FTC possess only microscopic capsular invasion and no vascular invasion. Grossly encapsulated angioinvasive FTC exhibit vascular invasion with or without microscopic capsular

invasion.<sup>420</sup> Widely invasive FTC demonstrate widespread infiltration of the adjacent thyroid tissue and/or blood vessels. Although older studies recommended 10 tissue blocks to adequately evaluate the tumor capsule and thyroid interface,<sup>423,424</sup> there are no good data on number of blocks, moreover encapsulated FTC can vary greatly in size, making a recommendation for a specific number of blocks unreasonable. Challenges for the pathologist in evaluating follicular-patterned lesions include difficulty in diagnosing capsular invasion since consensus is absent on what constitutes invasion, with some counting any penetration into the tumor capsule while others requiring complete infiltration through the complete thickness of the capsule. In FTC the number of foci of vascular invasion is also an important histologic finding, as  $\geq 4$  foci is associated with a higher risk of recurrence.<sup>425,426</sup> Scoring systems such as MACIS and TNM (see “Cancer Management”) are also prognostic for FTC, with 10-year disease-free survival rates of 97% to 98% for minimally invasive FTC and  $<50\%$  for widely invasive FTC.<sup>427–429</sup>

HCC, once described as an oncocytic variant of FTC, is now thought to represent a distinct type of DTC, in part due to its unique mutational profile.<sup>287,430,431</sup> HCC is made up of cells with abundant granular eosinophilic cytoplasm reflecting plentiful mitochondria and is associated with a range of architectural patterns varying from well-formed follicles to solid or trabecular growth. Classification of

**TABLE 13.** PTC Subtypes

Subtype	Nuclear Features of PTC Present?	Characteristics	Prognosis
(Follicular-variant encapsulated, non-invasive) now NIFTP	Y	Follicular growth pattern with no invasion, no well-formed papillae, low mitotic activity, lack of tumor necrosis, and low nuclear score <i>RAS</i> mutation more common	10-yr DSS 100%
Follicular-Variant	Y	Follicular growth pattern  <i>RAS</i> mutation or <i>PPARG</i> rearrangement more common	10-yr DSS 93%  10-yr DSS ~100%
Encapsulated, invasive		Low rate of LNM  <i>BRAF</i> V600E more common	Equivalent to classic/conventional PTC
Nonencapsulated/infiltrative Columnar cell	Occasionally	Papillae lined by columnar cells with nuclear stratification  Large tumors with capsular invasion are associated with LNM and DM	Variable
Cribriform morular	N	Presence of morules–squamous areas with intranuclear inclusions and nuclear clearing  Associated with Familial Adenomatosis Polyposis Syndrome	Equivalent to classic/conventional PTC
Classic/conventional	Y	LNM common	5-yr DSS 97.4% 10-DSS 93%
Diffuse sclerosing	Y	Diffuse fibrosis, dense lymphoid infiltration, squamous metaplasia	5-yr DSS 96% Equivalent to high risk PTC
Tall cell	Y	Extrathyroidal extension and LNM possible $>30\%$ – $50\%$ cells are $2\times$ long as wide and eosinophilic cytoplasm	5-yr DSS 95.6%
Hobnail	Y	Increased risk of DM $>30\%$ have hobnail features (eccentric nuclei and tapering cytoplasm), syncytial or micropapillary clusters with apically placed nuclei  <i>BRAF</i> V600E or <i>p53</i> positive	5-yr DSS 83%

invasion for HCC is similar to that for FTC as described above. HCC may have higher risk for local recurrence and be less iodine-avid.<sup>432–435</sup> 10-year survival for HCC is lower than FTC (76% vs 85%).<sup>436</sup>

The pathology report for a patient with DTC should include the histologic diagnosis, including subtype, location, and the characteristics required for AJCC TNM staging. For the 8th edition AJCC guidelines, which no longer utilize microscopic ETE, requisite histopathologic characteristics for staging of DTC and PD/ATC include the size of the dominant nodule as well as presence of LNM.<sup>437</sup> Additional histopathologic features are associated with disease biology and should be considered for reporting, including tumor multifocality, microscopic margin status, angioinvasion, lymphatic invasion, perineural invasion, and microscopic ETE.<sup>438</sup> In reporting histopathologic features, the 8th edition AJCC guidelines suggest inclusion in the pathology report of the number and location of involved LN, the number of nodes sampled, the size of largest involved LN, the size of metastatic foci within an involved LN, and the presence of extranodal extension.<sup>437</sup> The use of synoptic pathology reporting minimizes variability between institutions and ensures inclusion of information required for patient care.<sup>439</sup> The College of American Pathologists (CAP) provides a widely utilized checklist-format synoptic for thyroid cancer.<sup>440</sup>

**Recommendation 32: A standardized synoptic pathology report is recommended when reporting thyroid neoplasms. (Strong recommendation, low-quality evidence)**

### Neoplasms of Uncertain Malignant Potential

Some encapsulated follicular-patterned neoplasms cause diagnostic difficulties due to ambiguity as to whether the nuclear changes are adequate to diagnose PTC, or due to uncertainty about the presence or absence of capsular or vascular invasion.<sup>431,441</sup> In 2017, the World Health Organization acknowledged these 2 uncertainties and utilized the terms “well-differentiated tumor of uncertain malignant potential” (WDT-UMP) and “follicular tumor of uncertain malignant potential” (FT-UMP); FT-UMP includes cases in which the tumor does not have nuclear features of PTC but the capsular or vascular invasion is equivocal, and WDT-UMP describes a well-circumscribed tumor composed of follicles with partially developed PTC-type nuclear changes and questionable capsular or vascular invasion. Evaluation of the entire tumor capsule or its margin circumference is required to make the diagnosis of any borderline thyroid tumor.

NIFTP is the newly-minted term for those encapsulated or circumscribed tumors for which capsular and vascular invasion has been excluded. Other criteria for NIFTP diagnosis include: encapsulation or clear demarcation from adjacent thyroid tissue, a follicular growth pattern, a nuclear score of 2 to 3, no tumor necrosis, and no high mitotic activity.<sup>311</sup> In more recent studies, any papillary growth or presence of psammoma bodies excludes a tumor from being described as NIFTP and confers a diagnosis of encapsulated PTC.<sup>442</sup> Because capsule invasion is one of the defining features differentiating EFVPTC and NIFTP, thorough evaluation of the tumor capsule interface is essential before making or excluding the diagnosis of NIFTP. The presence of BRAF V600E mutation has also been recommended as an exclusion criterion for this diagnosis.<sup>443</sup>

### Poorly Differentiated Thyroid Carcinoma

PDTC occupies a morphologically intermediate position between DTC and ATC. Diagnostic consensus criteria for PDTC, known as the Turin criteria, were created by an international group of thyroid pathologists and include 1) presence of a solid/trabecular/insular pattern of growth, 2) lack of conventional nuclear features of

PTC, and 3) presence of  $\geq 1$  of the following features: convoluted nuclei; mitotic activity  $\geq 3 \times 10\text{HPF}$ ; and tumor necrosis.<sup>51</sup>

### Anaplastic Thyroid Carcinoma

ATC is a widely invasive tumor composed of a mixture of 3 main growth patterns: spindle cell, pleomorphic cell, and squamoid. Rarely (10%) ATC is confined to a thyroid lobe or gland or is represented by microscopic anaplastic foci.<sup>444,445</sup> Most cases exhibit numerous mitotic figures and atypical mitoses<sup>446</sup> as well as extensive coagulative necrosis.<sup>421</sup> Immunohistochemical markers of thyroid differentiation, such as thyroglobulin, are usually not present. Transcription factor-1 can be identified in up to 30% of cases. Unlike lymphoma, ATC often is positive for pankeratin (AE1/AE3).<sup>54</sup>

### Medullary Thyroid Carcinoma

MTC derives from C cells and is a neuroendocrine tumor. Characteristic histologic features are sheets, nests, or trabeculae of polygonal, round or spindle cells that are separated by fibrovascular stroma. Tumor cells often possess round or oval regular nuclei with nonprominent nucleoli and scant mitotic figures. The most important immunohistochemical markers used to identify MTC are calcitonin and CEA. More general neuroendocrine markers such as chromogranin A and synaptophysin may also be helpful for diagnosis.

In hereditary MTC, C-cell hyperplasia (CCH) occurs prior to cancer development and most likely represents clonal proliferation of multiple transformed progenitor cells. The diagnostic criteria for CCH are controversial but there is general consensus on the complete surrounding of follicles by C cells and distribution of C cells beyond the normal anatomic location.<sup>447</sup> Also challenging is the distinction between CCH and medullary microcarcinoma, which by definition is an MTC tumor of  $< 1\text{ cm}$  and showing invasion. CCH may be physiologic or neoplastic, the former requiring IHC and quantitative analysis for diagnosis and the latter usually diagnosed by H&E stains.<sup>448</sup> For the 8th edition AJCC guidelines, requisite histopathologic characteristics for MTC staging include dominant nodule size and presence of lymph node metastasis.<sup>437</sup> Use of the College of American Pathologists (CAP) synoptic for thyroid cancer is recommended for reporting MTC and includes additional histopathological features such as multifocality, microscopic margin status, angioinvasion, lymphatic invasion, perineural invasion, microscopic extrathyroidal extension, and CCH.<sup>438</sup> Synoptic nodal information for MTC and DTC are the same (above).

### Thyroid Paraganglioma

Paragangliomas in the region of the thyroid gland are rare tumors arising from the inferior laryngeal (parasympathetic) paraganglia. They can be mistaken for follicular or C-cell-derived malignancies, may present as intrathyroidal masses, are not functional in terms of catecholamine secretion, and can be distinguished from other tumors by positive staining for chromogranin A, synaptophysin, neuron-specific enolase, and/or S-100.<sup>449</sup>

### NODAL DISSECTION

Lymph node metastasis (LNM) is often present at TC diagnosis and can occur subclinically in up to 75% and 80% of MTC and PTC patients, respectively.<sup>450–452</sup> Therefore, a preoperative diagnosis of TC by cytology or molecular testing should prompt imaging to assess for LNM.<sup>453</sup>

Neck US that includes evaluation of central and lateral LN basins is recommended in patients with cytologic evidence of TC (see “Imaging”) and may be performed in patients with indeterminate cytology to help identify nonpalpable lymphadenopathy.<sup>3</sup> In selected patients, CT of the neck and upper chest can provide additional data especially in extensive lateral neck disease and for

regions not accessible by US.<sup>454</sup> Iodinated intravenous contrast should be utilized with CT to assess for vascular involvement.

Preoperative FNAB of an abnormal LN is recommended if a diagnosis of locally metastatic TC would change the operative plan (see “FNAB Diagnosis”). LN FNAB results, or LN tissue sampling if necessary (see “Perioperative Tissue Diagnosis”) may help establish a definitive diagnosis of TC with an indeterminate or non-diagnostic nodule FNAB result, and/or change the operative plan to include lateral and/or central compartment dissection.<sup>3</sup> If metastatic DTC is the primary concern, measurement of Tg level in the washout fluid of the cytology specimen may improve diagnostic sensitivity (see “FNAB Diagnosis”).<sup>204</sup>

Nodal basins (see Table 14, Fig. 3) are defined by anatomic boundaries and include the central (levels VI and VII) and lateral (levels I-V) compartments.<sup>154,455</sup> The extent of lymphadenectomy should consider laterality and whether the nodal basins ipsilateral and/or contralateral to the primary cancer are affected. Additionally, although operative conduct is similar, describing whether nodal dissection (ND) is performed *therapeutically* (ie, for clinically or radiographically evident LNM) or *prophylactically*, (ie, for clinically node negative or subclinical disease) is important for prognostic purposes (below; see “Cancer Management”).

To limit recurrence, initial nodal dissection (either central or lateral) for TC should be a compartment-oriented clearance of the fibrofatty and lymphoid tissue within the defined anatomic boundaries of the compartment while avoiding berry-picking of only grossly positive LN.<sup>3</sup> In a modeling study of NCDB patients with PTC and resection of at least 1 central and/or lateral LN, examination of 6, 9, and 18 LN in patients with T1b, T2, and T3 tumors, respectively, was adequate to exclude the possibility of occult nodal disease and underscore the importance of compartment-oriented dissection to improve yield.<sup>453</sup> Operative notes should describe the anatomic boundaries, laterality, and gross findings of nodal dissection.<sup>393</sup>

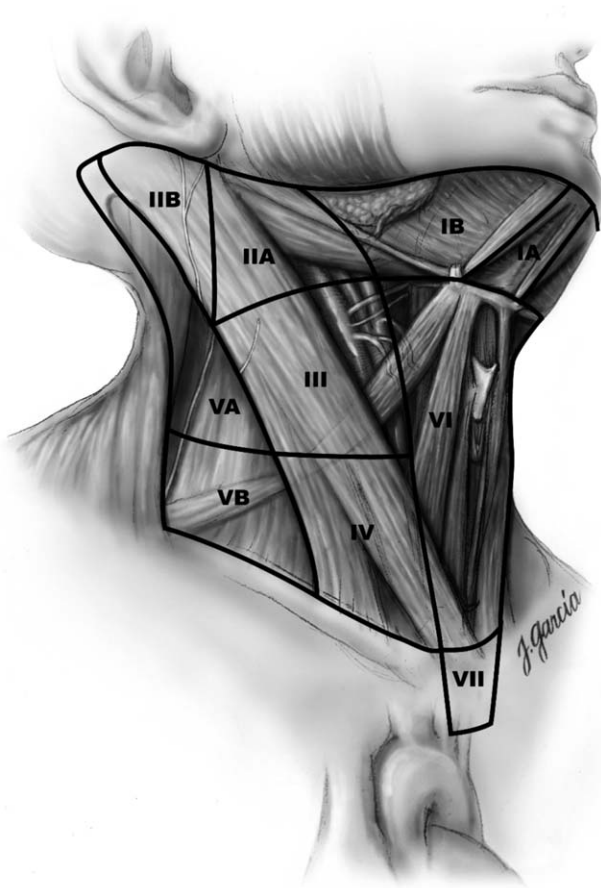
### Central Compartment ND

The central compartment (defined as levels VI–VII) is typically the first site for LNM in both PTC and MTC (see “Imaging”).<sup>154</sup> One exception that can occur when the primary tumor is located in the upper pole and LNM may “skip” the central compartment to be found initially in the lateral compartment only.<sup>456</sup> Central LNM involving the bilateral compartments occurs in 20% to 25% of PTC and is reportedly more common with PTC >1 cm, for PTC located in the isthmus, and when the ipsilateral LN

**TABLE 14.** Anatomic Boundaries of the Neck and Involvement in PTC

Level	Anatomic Boundaries	Likelihood of LNM [95% CI]
I	S: body of the mandible P: stylohyoid muscle A: anterior belly of the contralateral digastric muscle I: hyoid Triangular boundaries comprising anterior bellies of digastric muscles and hyoid separates Ia and Ib	5%–9% [na]
II	S: skull base P: posterior SCM A: stylohyoid muscle I: hyoid CN XI separates IIa and IIb IIa nodes lie anterior to IJV	IIa: 53% [47%–60%] IIb: 16% [8%–27%]
III	S: hyoid P: posterior SCM A: sternohyoid muscle I: horizontal plane defined by the cricoid cartilage	71% [67%–74%]
IV	S: inferior border of the cricoid cartilage P: posterior SCM A: sternohyoid muscle I: clavicle	66% [61%–71%]
V	S: convergence of SCM and trapezius P: anterior border of trapezius A: posterior SCM I: clavicle Inferior border of cricoid separates Va and Vb	Va: 8% [3%–20%] Vb: 22% [8%–48%]
VI	S: hyoid superiorly P: deep layer of the cervical fascia A: anterior layer of the cervical fascia I: sternal notch	40%–60% [na]
VII	S: sternal notch P: deep layer cervical fascia A: sternum I: innominate on right and equivalent plane on the left	

A indicates anterior; I, inferior; na, not available; P, posterior; S, superior; SCM, sternocleidomastoid muscle.



**FIGURE 3.** Cervical lymph node compartments. Consensus statement on the terminology and classification of central neck dissection for thyroid cancer. Reprinted with permission from Mary Ann Liebert, Inc. from American Thyroid Association Surgery Working Group, et al.<sup>154</sup> Copyright © Mary Ann Liebert, Inc., New Rochelle, NY. All permission requests for this image should be made to the copyright holder.

compartment is positive.<sup>457–459</sup> In MTC, central LNM are present in the majority of patients who undergo initial TT and are not always apparent by pre- or intraoperative assessment.<sup>450</sup> Bilateral prophylactic CND for known MTC is recommended at initial surgery (see “Familial TC”).<sup>106,460</sup> Conversely, FTC rarely involves LNM.

**Therapeutic** central compartment LN dissection (CND) is indicated for PTC or MTC patients who have clinical or imaging-apparent nodal disease, with the goal of complete resection of oncologic disease at initial surgery to achieve local and regional control. Incomplete nodal resection is associated with lower rates of disease-free and cancer-specific survival.<sup>461</sup> Because preoperative imaging has low sensitivity for detecting CLNM when the thyroid is in situ, the central compartment should also be inspected at the time of initial thyroidectomy, so that therapeutic CND may be performed concurrently, if appropriate.<sup>462–464</sup>

**Prophylactic** CND for low risk PTC is controversial. The rationale is based on retrospective data that suggest excision of all microscopic metastatic foci will help to avoid the potential added morbidity of reoperation,<sup>465</sup> allow for accurate staging,<sup>466</sup> and limit recurrence.<sup>467–469,470</sup> An estimated 31 patients would need to be treated with prophylactic CND to prevent one recurrence.<sup>467</sup> Three

rebuttal points have been used to discourage routine prophylactic CND for PTC. First, CND is potentially associated with higher risks of hypoparathyroidism and RLN dysfunction.<sup>467</sup> Early results from 1 randomized trial evaluating outcomes after TT demonstrated that while bilateral prophylactic CND produced lower Tg levels post-ablation, it also resulted in a higher rate of permanent hypoparathyroidism (18% vs 7%,  $P = 0.02$ ).<sup>471</sup> With a median of 60-month follow-up, the incidence of persistent PTC in both cohorts was the same; however, the study was designed to demonstrate noninferiority and was not powered to show differences in disease-related outcomes.<sup>471</sup> Second, PTC recurrence has low rates (<5%) after TT alone, which are equivalent to those of TT with CND, and which can be managed by reoperation with low morbidity at specialty centers.<sup>298,472,473</sup> Third, the prognostic significance of the micrometastatic PTC that is typically resected in prophylactic CND appears minimal; in fact, current staging systems (ATA Risk Stratification, 8th edition AJCC TNM Staging, see “Cancer Management”) have been modified to diminish the role of low volume nodal involvement.<sup>3,474</sup> Prophylactic CND has not been shown to influence survival, although prospective studies with adequate follow-up are lacking.<sup>475–477</sup> There are no data on prophylactic CND in lobectomy alone.

A selective approach to prophylactic CND has been proposed and in multivariable analysis of large retrospective datasets, younger age, male gender, and larger DTC may be associated with a higher likelihood of central LNM.<sup>478,479</sup> Current ATA guidelines suggest considering prophylactic CND for advanced primary DTC (T3/T4) and/or if lateral LNM are present; however, this recommendation is based on expert opinion.<sup>3</sup> To distinguish PTC patients who may benefit from CND, identification of the sentinel lymph node by lymphoscintigraphy and/or blue dye has been described with variable results and is still considered investigational (see “Adjuncts and Approaches”).<sup>480</sup> IOPE of a suspicious-appearing central compartment lymph node (see “Perioperative Tissue Diagnosis”) is used by some surgeons to determine if CND is needed and has also been used to guide need for bilateral CND.<sup>481</sup> In 1 study, IOPE of the Delphian LN, found in level VI anterior to the cricothyroid membrane, had 35% sensitivity and 97% specificity in predicting additional central LNM.<sup>482</sup>

In summary, in the absence of clinically evident LNM, there are no conclusive data showing that aggressive prophylactic extirpation of microscopic PTC LNM improves disease-specific outcomes. A well-designed and adequately powered randomized study is likely not feasible for oncologic endpoints.<sup>154,483</sup> Overall, whether prophylactic CND for PTC is performed during initial thyroidectomy should depend on tumor and patient characteristics and surgeon expertise. For DTC, prophylactic CND in the reoperative setting is not indicated.

**Recommendation 33:** *During initial thyroidectomy for PTC, the central compartment should be assessed for suspicious lymphadenopathy. If clinical or imaged LNM is present (ie, macroscopic disease), a therapeutic CND is recommended. (Strong recommendation, high-quality evidence)*

The risks associated with CND for any indication include temporary hypocalcemia in up to 40% of patients.<sup>468</sup> Although this resolves in the majority, in a meta-analysis the rate of permanent hypoparathyroidism after CND is 2% to 4% which was higher than after TT alone (OR 1.84, 95% CI 1.2–3.0).<sup>468</sup> After bilateral prophylactic CND, the rate of permanent hypoparathyroidism approaches 18%.<sup>471</sup> CND also carries an increased risk of RLN dysfunction,<sup>154</sup> however, most large studies report rates of paralysis that range from 1% to 3% which are comparable to those with total thyroidectomy alone.<sup>470,473</sup>

Intraoperatively, one of the first steps of CND should be identification of the RLN and delineation of its course. LN and CLNM are often found posterior to the RLN especially on the right, and this area should be included. During mobilization of the upper thyroid pole, particular effort should be made to preserve the superior parathyroids on their vascular pedicles. Preservation of the inferior parathyroid glands is a priority but because of concomitant LN disease, may not be possible; devascularized or resected parathyroid tissue should be immediately autotransplanted (see “Initial Thyroidectomy”). IOPE can help confirm parathyroid tissue prior to autotransplantation (see “Perioperative Tissue Diagnosis”).

### Lateral Compartment ND

The lateral compartment is comprised of 5 nodal levels; the submandibular and submental (level I), the upper (II), middle (III), and lower (IV) jugular, and the posterior triangle (V) (Table 14).<sup>455</sup> A radical neck dissection includes systematic dissection of all LN from levels I to V, together with resection of the internal jugular vein (IJV), the spinal accessory nerve (CN XI), and the SCM. The procedure is morbid, disfiguring, and rarely performed for thyroid cancer today. A modified radical neck dissection preserves 1 or more of the following: IJV, CN XI, SCM.

A compartment-oriented selective neck dissection (SND) is the term used when fewer than all 5 nodal levels are removed and is the most commonly utilized type of therapeutic LN resection for TC.<sup>455</sup> At initial SND for PTC, levels IIa, III, IV, and Vb are typically included (Table 14)<sup>3</sup> and their comprehensive clearance is associated with a lower risk of recurrence.<sup>455,484–486</sup> To reduce the risk of injury to CN XI and because of the low likelihood of LNM involvement, level IIb is only dissected if there is radiographic evidence of LNM or level IIa is positive, and similarly level Va is only dissected when it has clinically or radiographically apparent LNM.<sup>455</sup> TC LNM in level I is rare (<10%) and recurrence is also rare (<1%) if not dissected at initial SND.<sup>487–489</sup> Prophylactic lateral ND has not been shown to improve PTC survival or recurrence rates; thus, SND is typically performed only for clinically evident disease.<sup>490–492</sup>

At the time of MTC diagnosis with palpable primary tumor, ipsilateral lateral LNM are subclinically present in up to 75% of patients, and calcitonin levels can help direct the need for lateral ND.<sup>450</sup> Ipsilateral and contralateral lateral LNM are signaled by basal calcitonin levels >20 and >200 pg/mL, respectively.<sup>106</sup> Some therefore advocate for prophylactic selective dissection of the ipsilateral neck for MTC although this remains controversial.<sup>56,493</sup> The suspicion for lateral nodal disease in MTC can be based on US findings and/or serum calcitonin levels (see “Familial TC”).

#### Recommendation 34:

- A compartment-oriented therapeutic lateral ND is recommended for lateral LNM. (Strong recommendation, high-quality evidence)**
- Prophylactic lateral ND is not indicated for PTC. (Strong recommendation, high-quality evidence)**

Lateral ND can be associated with significant morbidity. CN XI palsy occurs in 6% to 20% of cases, resulting in shoulder weakness and inability to raise the arm requiring physiotherapy;<sup>455,494</sup> the dysfunction will resolve in most patients but can be debilitating. Other neurologic complications include injuries to the marginal mandibular branch of the facial nerve (which can occur during dissection of levels I and II resulting in an asymmetrical smile), injury to the hypoglossal nerve, and lateral neck numbness from injury to the cervical sensory branches in level V.<sup>495</sup> Less common (<1%) are injuries to the phrenic nerve, brachial plexus, cervical sympathetic chain (Horner syndrome) and/or hypoglossal nerve (CNXII).<sup>455</sup> Chyle leaks occur in up to 10% of patients who

undergo lateral ND, more commonly on the left side where the thoracic duct joins the left IJV at its junction with the left subclavian vein is located but also with right-sided dissection.<sup>494,496,497</sup> Intraoperatively, large lymphatics, which can be present especially with bulky lateral neck disease, should be ligated, and raising the intrathoracic pressure with Valsalva maneuver and head-down positioning can help to identify chyle leak. Drains may help diagnose and allow conservative management of chyle leak, but are not mandatory after neck dissection.<sup>498,499</sup> Management of low volume chyle leak can often be done in the outpatient setting and includes adequate drainage, diet modification (a low fat, medium-chain triglyceride diet, occasionally TPN), and potentially octreotide.<sup>500</sup> Persistent high output leaks (>500 mL/d) may require surgical management and if uncontrolled, even embolization of the thoracic duct with coils or tissue adhesive, or thoracoscopic ligation of the thoracic duct between the aorta and azygous vein hiatus.<sup>497</sup> Chylothorax is a very rare occurrence (<20 cases reported) but may have significant consequences.<sup>501</sup>

### Prognostic Implications of LNM

Patients with clinical N1 DTC (see “Cancer Management”) or with >5 pathologic LNM are considered ATA intermediate risk with a recurrence rate of 15% to 20%.<sup>3</sup> In multivariable analysis, the risk of PTC recurrence is higher with age ≥45 years, >10 LNM, LN extranodal extension, or if the proportion of resected LNM (defined by the ratio of positive to total resected LN) exceeds 17%.<sup>502</sup> In other studies of PTC, extranodal extension is associated with a higher risk of both recurrence and disease-specific mortality.<sup>503,504</sup> The risk of recurrence is also higher in patients with large nodal metastasis (>3 cm).<sup>483,505</sup> The prognostic significance of LNM in younger patients (age <45 yr) is controversial. A population-level study using the SEER database demonstrated that LNM did not alter overall survival in young patients.<sup>506</sup> However, a more recent study utilizing data from both SEER and NCDB demonstrated a modest decrease in overall survival associated with LNM in patients <45 years old.<sup>507</sup> In addition, the survival decrease was associated with a rising number of LNM up to 6.<sup>507</sup> In MTC, the number of LNM is also associated with decreased overall survival.<sup>508</sup>

In DTC, reoperation for recurrent nodal disease results in biochemical remission in only 30% to 50% of patients. In addition, if the compartment has been previously dissected, reoperation for LNM is associated with a higher risk of complications<sup>509,510</sup> and although a compartment-oriented dissection is recommended at reoperation, this may be limited by scarring and the extent of initial dissection.<sup>3</sup> In 1 study of PTC patients who had at least 1 abnormal LN on US surveillance following initial treatment, at median follow-up of 3.5 years, LN growth occurred in only 10% to 20%, suggesting that sonographically concerning LN may not require immediate resection.<sup>511</sup>

In poor operative candidates, especially those with multiple prior neck surgeries, percutaneous ethanol injection of PTC LNM has been reported in small single-institution series and can lead to biochemical remission and resolution of structural disease.<sup>512</sup> There is a risk of associated RLN or other nerve (phrenic, brachial plexus) injury although the risk appears to be low (<1%).<sup>513</sup> Recurrences occur in ~20% to 25% as ethanol injection only treats the targeted LN.<sup>512,513</sup> The management of recurrent or persistent nodal disease in TC patients can be complex and should occur within a multidisciplinary framework.<sup>514</sup>

## CONCURRENT PARATHYROIDECTOMY

### Epidemiology and Evaluation

Concomitant primary hyperparathyroidism (pHPT) occurs in 0.2% to 5% of patients with thyroid disease, thus various groups have

recommended routine assessment of calcium and/or PTH levels prior to planned thyroidectomy.<sup>99,100,515,516</sup> In a retrospective study of 1049 patients undergoing thyroidectomy, 5% had concomitant pHPT, and another 0.9% had normal preoperative calcium and PTH levels but were found to have an enlarged parathyroid at surgery.<sup>100</sup> A retrospective study of 13,387 patients evaluated in an endocrinology clinic found hypercalcemia due to pHPT in 0.2% of patients with a thyroid disorder; pHPT was more likely with thyroid disease [0.9% with vs 0.29% without], especially with euthyroid goiter ( $P < 0.05$ ) or thyroid cancer ( $P = 0.01$ ).<sup>515</sup>

When pHPT is present, the cost-effectiveness of surgical treatment is well established.<sup>517–519</sup> The potential benefits for proceeding with initial parathyroidectomy at the same time as initial thyroidectomy are numerous.<sup>6</sup> While published data support routine preoperative assessment, no data exist regarding the cost-effectiveness of routine screening for pHPT. Many patients undergoing thyroid surgery will likely have had at least a recent metabolic panel. When present, hypercalcemia should be evaluated biochemically (see “Preoperative Care”). Important cautions are that on US, an enlarged parathyroid is not necessarily hyperfunctioning; parathyroid gland size does not perfectly predict function; and an imaged structure may ultimately represent ectopic thyroid, fat, thymic tissue, or LN.<sup>520</sup>

**Recommendation 35: Hypercalcemia should be evaluated preoperatively in a patient being evaluated for thyroid surgery. (Strong recommendation, low-quality evidence)**

In a patient diagnosed with concurrent thyroid and parathyroid disease, US is the preferred initial imaging modality for both disease types (see “Imaging”).<sup>6</sup> Further specific imaging, such as 99m-technetium sestamibi with single-photon emission CT (SPECT), SPECT-CT, or 4 dimensional (4D) CT, can be helpful in guiding parathyroidectomy, especially if results allow a unilateral approach when thyroid lobectomy is planned, indicate a contralateral exploration, or diagnose an ectopic abnormal parathyroid.<sup>1</sup> However, when total thyroidectomy is already planned, further parathyroid imaging may be unnecessary given the expectation that all parathyroids will be examined during bilateral dissection.

In the setting of concomitant thyroid disease, parathyroid imaging studies are less sensitive and less specific,<sup>521–524</sup> for example, posterior thyroid nodules may be mistaken for enlarged parathyroids,<sup>522,524</sup> and 99mTc-MIBI may be retained in thyroid nodules on delayed images.<sup>523</sup> Except in select, uncommon situations such as a suspected intrathyroidal parathyroid, preoperative parathyroid FNAB is not advised<sup>6</sup> (see “Imaging”). Prior to deliberate parathyroid FNAB, the authors suggest consulting a surgeon regarding the potential utility of results.

Incidental removal of normal parathyroid tissue occurs during 4% to 22% of thyroid resections, with associated factors of female sex, younger age, total/subtotal thyroidectomy for malignancy, and concomitant CND.<sup>6,525–534</sup> Unintended removal can also be due to intrathyroidal parathyroid location, which is reported in 0.7% to 4% of patients undergoing surgery for pHPT.<sup>535,536</sup> During thyroidectomy, liberal autotransplantation of a questionably viable, morphologically normal parathyroid is recommended to minimize the risk of permanent hypocalcemia (see “Initial Thyroidectomy”) after confirming it is parathyroid tissue by IOPE.

### Indications for Concurrent Parathyroidectomy

To both reduce the need for reoperative neck surgery and appropriately address treatable parathyroid disease when present, multiple studies have advised that patients with a diagnosis of pHPT should undergo concurrent parathyroidectomy at the time of planned initial thyroidectomy,<sup>100,528,530,537–539</sup> which can be performed

safely and with equivalent rates of cure compared with parathyroidectomy alone but may result in increased rates of hypocalcemia.<sup>100,528,538,540</sup> The addition of thyroidectomy to parathyroidectomy increases the risk of RLN injury.<sup>538</sup>

Occasionally, an enlarged parathyroid gland is encountered during thyroidectomy in a patient with normal preoperative calcium and/or PTH levels, a situation reported in 2 retrospective series to occur in 1.0% and 1.9% of patients.<sup>100,541</sup> We suggest that when other viable parathyroid glands are preserved, a single incidentally discovered, enlarged parathyroid should be removed, although data are lacking to support or refute this approach.

**Recommendation 36: Patients undergoing initial thyroidectomy who are diagnosed with primary hyperparathyroidism should undergo concurrent parathyroidectomy. (Strong recommendation, moderate-quality evidence)**

### Special Situations

During initial surgery, the order of dissection for concurrent thyroidectomy and parathyroidectomy depends on the indications, disease severity, risk profile, use of adjuncts, alteration in venous outflow, and other factors. In general, the most pressing problem should take priority along with assurance of airway preservation.<sup>6</sup>

Hypercalcemia occurs in up to 22% of patients with thyrotoxicosis, most often in older patients with GD, and in such cases preoperative biochemical evaluation to differentiate this phenomenon from pHPT should be pursued.<sup>515,537,542,543</sup>

In patients with chronic kidney disease on dialysis, at the time of thyroidectomy the opportunity should be taken to treat secondary HPT if present. After subtotal parathyroidectomy for multiglandular parathyroid disease of any type, careful notation of the position of the parathyroid remnant and its proximity to the RLN is advised, in the event of need for reoperation. A clip or permanent suture may be placed on or near the remnant to mark its location. Patients on chronic lithium therapy should undergo full evaluation for pHPT prior to planned thyroidectomy as the prevalence of lithium-associated HPT is high (18%)<sup>544–546</sup> with a high rate of multigland parathyroid disease (32%–62%).<sup>547–549</sup> Patients who have had gastric bypass surgery have special considerations as well (see “Preoperative Care”).

Specific guidelines for the screening and management of coexisting thyroid and parathyroid disorders exist for patients with MEN I<sup>550,551</sup> and MEN IIA.<sup>58,493,550–552</sup> In familial conditions of pHPT, the management of coexisting thyroid disease and HPT is facilitated when a genetic mutation has been identified prior to surgery (see “Familial TC”).

**Recommendation 37: Evaluation for HPT is recommended in patients scheduled to undergo thyroid surgery who have a history of familial pHPT. (Strong recommendation, moderate-quality evidence)**

## HYPERTHYROID CONDITIONS

Hyperthyroidism is defined as increased synthesis or secretion of thyroid hormone by the thyroid gland and is a principle cause of thyrotoxicosis, which is a clinical syndrome resulting from excessive amounts of bioavailable thyroid hormone from any source (Table 15). The prevalence of hyperthyroidism in the US is about 1.2%<sup>13</sup> with variable presentation; approximately 40% of hyperthyroid patients have subclinical disease and 60% have overt features. Hyperthyroid patients with TA or TMNG should undergo further investigation (see “Initial Evaluation,” “Imaging,” “FNAB Diagnosis” “Goiter”). The incidence of TC in selected cohorts of surgically-treated TMNG is variable (3%–20%), but overall low.

**TABLE 15.** Causes for Thyrotoxicosis Associated With and Without Hyperthyroidism

Thyrotoxicosis of thyroid origin	Nodular Autoimmune Destructive Recurrent hyperthyroidism due to thyromatosis
Thyrotoxicosis of nonthyroid origin	HP axis—TRH, TSH producing pituitary adenoma Extrathyroidal neoplasms—trophoblastic disease, struma ovarii, choriocarcinoma Excessive ingestion of levothyroxine Functional thyroid cancer metastases Medications—amiodarone, lithium, interferon alpha, interleukin-2, iodinated contrast, tyrosine kinase inhibitors, post-RAI for Graves disease (early), post-RAI for TMNG (late), certain other immunomodulators Genetic—resistance to thyroid hormone, familial nonautoimmune hyperthyroidism

HP indicates hypothalamic-pituitary; RAI, radioactive iodine; TRH, thyroid releasing hormone; TSH, thyroid stimulating hormone.

Thyroid stimulating immunoglobulin and thyrotropin receptor antibodies are indicative of GD, whereas antithyroid peroxidase or antithyroglobulin antibodies indicate Hashimoto or chronic lymphocytic thyroiditis.<sup>13,553</sup> Biotin ingestion may interfere with certain thyroid immunoassays and should be discontinued if thyroid function results do not match the clinical scenario.<sup>554</sup> Hypercalcemia is common in GD (see “Concurrent Hyperparathyroidism”).

In a hyperthyroid patient, a RAI uptake test establishes the functional status of the gland and any nodules which may be present, but does not predict cancer risk.<sup>555,556</sup> Although each laboratory should establish its own normal range, normal RAI uptake is generally 5% and 25%, while uptake is usually increased in GD, TA, or TMNG, and is decreased or absent in thyroiditis. The thyroid scintigraphy pattern after oral administration of 123I or intravenous administration of 99mTc is helpful in distinguishing diffuse (GD), heterogeneous (TMNG), and increased uptake in a single nodule with suppression of uptake in the remainder of the gland (TA).<sup>13</sup>

In hyperthyroidism, decisions about the type and timing of treatment are determined by factors including urgency of cure, compliance, access to care, and disease severity which can range from subclinical to life-threatening. Overall, long-term treatment with antithyroid medications is not recommended as a first or second-line choice.<sup>13</sup> RAI ablation or surgery may be selected as definitive treatment (Table 16). Each treatment modality carries a risk profile and should be balanced with practice patterns, patient preferences, costs, and physician experience (Table 17).

## Medical Treatment

Treatment of hyperthyroidism depends on the time-course of the disease, which in some situations will resolve over weeks to years with supportive treatment (such as, beta blockers, anxiolytics, or gastrointestinal remedies) and in other cases, may require ATDs for long-term management. Methimazole is the most common medication used to lower thyroid hormone levels. PTU is also available but carries a “black box” warning due to a higher risk of serious adverse effects (rash, hepatotoxicity, agranulocytosis). However, PTU remains the most effective medication to rapidly lower hormone levels in thyroid storm and may be used with care in highly selected situations for short periods until methimazole can be substituted. PTU is also the drug of choice in the first trimester of pregnancy (below).<sup>557</sup>

Other medications and treatments that may assist in lowering thyroid hormone levels either acutely or long term (see “Preoperative Care”) include steroids, lithium, cholestyramine, plasmapheresis, and KI,<sup>13</sup> which transiently inhibits thyroid iodide organification for 7 to 10 days, after which normal organification resumes, thus continued administration of KI should be avoided as it can lead to worsening hyperthyroidism.<sup>373,374,558,559</sup>

In a cost-effectiveness analysis comparing medical management to both RAI ablation and surgery, long-term ATD treatment was the least cost-effective.<sup>560</sup> However, cost-effective strategies may be different in other countries as revealed in a study examining practices in Australia and England where RAI ablation was found to be the least expensive strategy followed by ATDs and surgery.<sup>561</sup>

**TABLE 16.** Recommended Treatment for Causes of Hyperthyroidism

Cause of Thyrotoxicosis	Typical Treatment*	Additional Treatment Options	Other (ETOH Ablation, RFA)	Extent of Surgery
Single toxic nodule	Surgery	RAI	ETOH ablation or RFA	Lobectomy and isthmusectomy
TMNG	Surgery	RAI		Total thyroidectomy
Graves' disease 1) No or mild GO 2) + GO	1) RAI or Surgery 2) Surgery	Methimazole		Total thyroidectomy
Acute, subacute, chronic thyroiditis	Supportive (Beta-blockers, NSAIDs)	Steroids Surgery†		Total thyroidectomy†
Functional thyroid cancer metastases or benign thyroid deposits	RAI or surgery	Image/catheter guided therapy Chemotherapy	ETOH ablation RFA	Complete resection
Hypothalamic pituitary axis	Surgery	XRT	Medication (octreotide, bromocriptine)	Complete resection
Extrathyroidal neoplasms	Surgery	Image/catheter guided therapy		Complete resection

\*Selection of therapy depends on the clinical situation and patient factors.

†Surgery for thyroiditis is rarely needed in highly selected situations.

ETOH indicates ethanol; GO, Graves ophthalmopathy; NSAID, nonsteroidal anti-inflammatory drug; RFA, radiofrequency ablation.



**TABLE 17.** Considerations for Selection of Surgery Rather Than Radioactive Iodine for Treatment of Thyrotoxicosis

Pregnancy or desire for pregnancy within 6 months
Concern for thyroid malignancy
Goiter >80 g
Moderate or severe Graves ophthalmopathy
Social issues (infants, small children in the home, unable to follow RAI safety measures)
Poorly controlled hyperthyroidism requiring rapid normalization of thyroid hormone levels
Airway compromise necessitating urgent resolution
Other central neck pathology requiring surgery (primary hyperparathyroidism, large size (>4 cm) or multiple benign thyroid nodules)
Prior radioactive iodine treatment
Low % iodine uptake

In the US, RAI ablation provides a common definitive approach to achieving a euthyroid state for selected patients with TMNG, isolated TA, or GD.<sup>10,13,563–566</sup> RAI is well tolerated in most patients but can fail to completely treat the disease, cause keratoconjunctivitis sicca and xerostomia, and exhibit differential thyroid uptake which may require surveillance and additional long-term treatment. Destruction of thyroid tissue by RAI ablation can lead to a transient increase in thyroid hormone levels about 1 week after treatment, which should be anticipated in patients with cardiovascular disease, who may develop dysrhythmias or other complications. Compared with thyroidectomy, hyperthyroidism takes somewhat longer to resolve (4–8 wk for RAI ablation vs 2–6 wk for surgery depending on preoperative levels)<sup>566</sup> and is less likely to achieve full remission. In a retrospective study, RAI ablation was successful in 92% of patients versus 100% for surgery.<sup>567</sup> RAI ablation is contraindicated in pregnancy. The risks of thyroidectomy specific to hyperthyroid patients are detailed below.

For TA, 2 other therapeutic approaches are ethanol injection (see “Nodal Dissection”) and radiofrequency ablation,<sup>568</sup> neither of which have gained popularity in the US nor are recommended as initial treatment,<sup>13</sup> but which may be considered when patients are not candidates for conventional treatment. In most cases a surgeon should be consulted prior to proceeding, as surgery after one of these interventions can be more difficult if a euthyroid state does not result, hyperthyroidism recurs, or a nodule persists.

### Surgical Treatment

Surgery is selected for definitive treatment of hyperthyroidism after considering factors that include etiology, clinical course and severity, regional resources and limitations, patient comorbidities, social constraints, and patient preference (Tables 16 and 17). Overall, while the risks of thyroidectomy in general are low, they are demonstrably higher in hyperthyroidism (below);<sup>569–574</sup> moreover, the likelihood of other morbidity is also increased, such as, cardiac dysfunction in amiodarone-induced thyrotoxicosis (below).<sup>575,576</sup> For hyperthyroid patients who select thyroidectomy, appropriate preoperative preparation is important (see “Preoperative Care”).

In general (see “Indications, Extent, and Outcomes of Surgery”) thyroidectomy is rarely performed for thyroiditis, but may be required in situations of brittle, difficult-to-control thyrotoxicosis, unremitting symptoms, and/or large compressive goiter.<sup>24,318,577,578</sup> Lobectomy may be selected for patients with isolated TA who are young, desire more rapid resolution than RAI ablation provides, or have a TA that is large, enlarging, causing compressive symptoms, or

cosmetically significant. For those with TMNG, total or near-total thyroidectomy may be preferred over RAI ablation given large goiter size or risk of persistent/recurrent disease, whereas subtotal thyroidectomy, once favored, is no longer recommended as definitive treatment (see “Initial Thyroidectomy”)<sup>12,13</sup>.

Surgery for GD is performed commonly today in the U.S.,<sup>555,566,569–572,574,579</sup> and total thyroidectomy is the procedure of choice. Total thyroidectomy is more effective for GD than subtotal thyroidectomy (Table 12) or RAI ablation (Table 16).<sup>359,556,580,581</sup> In a retrospective study of 40 patients undergoing total thyroidectomy for GD, improvement in quality of life was reported to be marked and rapid, with resolution of hyperthyroid symptoms in an average of 32 days.<sup>582</sup>

Amiodarone-induced thyrotoxicosis, which occurs as Type 1 (iodine-induced) and Type 2 (thyroiditis-induced)<sup>583</sup> may require thyroidectomy if medical management fails. Such patients often have significant underlying cardiac dysfunction with high risk for complications from anesthesia and surgery by the time surgical consultation is obtained. Operative mortality as high as 9% has been reported<sup>584</sup>, although other series reveal better outcomes.<sup>585–587</sup> It is thus important that thyroid surgeons be involved in the therapeutic decision making for amiodarone-induced hyperthyroidism as soon as there is evidence of nonresponse to medical therapy. Thyroidectomy under loco-regional anesthesia can be considered in select cases, but requires a willing and able patient and a skilled team.<sup>588</sup>

### Graves’ Ophthalmopathy

Additional considerations affect treatment selection in patients with Graves ophthalmopathy (GO) a debilitating condition that can jeopardize eyesight.<sup>589,590</sup> In patients with moderate to severe GO,<sup>591–594</sup> surgery is preferred over RAI ablation because it has less potential for acute worsening of GO.<sup>13,595</sup> A retrospective study of 150 patients treated with ablation observed worsening ophthalmopathy in 15% within 1 year of treatment. In a study that compared subtotal thyroidectomy to RAI ablation, GO progressed in 6% versus 10% of patients, was stable in 78% versus 86%, and improved in 16% versus 3%.<sup>13,596</sup> Whether progression of GO after RAI or surgery is simply due to the natural course of disease is unclear, since the active phase of GO may last for 18 to 36 months.<sup>590</sup> In mild GO, RAI ablation and surgery have equivalent low ophthalmologic risks if steroid treatment is prescribed at the time of RAI.<sup>13</sup> In moderate to severe GO, steroids should be given with RAI ablation if surgery cannot be pursued as the first-line option, to attempt to mitigate any worsening of GO.<sup>13</sup> As GO may not be obvious to nonophthalmologists, and/or may threaten optic nerve viability, it is advisable to refer GD patients to an ophthalmologist familiar with GO for a baseline examination, the results of which may also direct selection of treatment.

**Recommendation 38:** *In patients with moderate to severe Graves ophthalmopathy, total thyroidectomy should be considered as first-line definitive treatment. (Strong recommendation, moderate-quality evidence)*

### When to Start Thyroid Hormone

In patients who were rendered euthyroid preoperatively based on free T4 and T3 levels (as changes in TSH will lag), ATDs should be discontinued after surgery and weight-based levothyroxine should be started.<sup>13</sup> For patients who are hyperthyroid at the time of surgery, ATDs should be discontinued postoperatively, and levothyroxine typically started 1 week after surgery to allow time for thyroid hormone levels to decrease to normal. Beta blockers, if used, should be weaned over several days as tolerated to prevent rebound tachycardia, headache, and other symptoms.

## Surgical Complications in Hyperthyroidism

A recent National Inpatient Sample database study found an increased risk of complications (bleeding, hypocalcemia, vocal-cord paralysis, tracheostomy; see “Postoperative Care and Complications”) in patients undergoing thyroidectomy for GD compared with nontoxic goiter.<sup>2</sup> However, when thyroidectomy is performed by a high-volume thyroid surgeon, permanent complications rates (RLN injury, hypocalcemia) were no higher than for thyroidectomy performed for other reasons.<sup>352,597</sup>

Hematoma and intraoperative blood loss are more likely in patients undergoing surgery for thyroiditis and especially for GD.<sup>567,571,598,699</sup> Such glands are often larger, adherent, inflamed, and more vascular; from this perspective, KI solution given preoperatively to help control thyroid hormone levels also may help to decrease gland vascularity.<sup>371,558</sup> (see “Preoperative Care”).

Temporary postoperative hypocalcemia is also more common in surgery for hyperthyroidism, especially GD.<sup>381,567,569,571,600,601</sup> This is thought to be in part due to thyrotoxic osteodystrophy, that is, increased bone hunger in longstanding hyperthyroidism<sup>602–606</sup> although a meta-analysis advised that calcium and 25-hydroxy vitamin D levels be preoperatively assessed and prophylactically repleted or supplemented in GD patients (see “Preoperative Care”).<sup>383</sup>

Some groups have reported higher RLN injury rates in GD,<sup>607–609</sup> while others report no difference in permanent dysfunction.<sup>555,579,610–613</sup> Injury is postulated to be due to stretch from more difficult medial retraction, as well as increased intraoperative bleeding with diminished visualization.

In patients with GD, the feared yet rare complication of thyroid storm<sup>13,614–619</sup> may occur during surgery or afterward even if the patient is preoperatively rendered euthyroid, and is postulated to occur from intraoperative manipulation and compression with release of hormone into the circulation.<sup>617</sup> Intraoperative thyroid storm may resemble malignant hyperthermia with tachycardia, hypertension or hypotension, heart failure, fever or diaphoresis, but can be distinguished by lack of muscle rigidity/masseter spasm and rise in end-tidal CO<sub>2</sub>.<sup>615,617,620,621</sup> Treatment includes fluids, beta-blockers and other cardiovascular medications, steroids, and anti-thyroid medications. Mortality ranges from 8% to 25%.<sup>13,614–619</sup>

**Recommendation 39:** *Due to the higher risk and greater technical difficulty, thyroidectomy in Graves disease is best performed by high volume thyroid surgeons. (Strong recommendation, low-quality evidence)*

## The Hyperthyroid Pregnant Patient

TSH is expected to decrease in the first trimester due to a normal hCG-mediated effect that requires no treatment.<sup>622</sup> True hyperthyroidism in pregnancy is treated with ATDs. Since teratogenic effects from methimazole occur in 2% to 4% of exposed children, PTU is the drug of choice in the first trimester. Methimazole may be instituted after the first trimester.<sup>623–630</sup> If beta-blockade is required, atenolol should be avoided due to possible fetal growth restriction with prolonged use.<sup>13</sup>

If hyperthyroidism cannot be adequately controlled and surgery is deemed necessary, it is ideally performed during the second trimester due to teratogenic effects of anesthesia in the first trimester, and preterm labor and lower birth weight in the third trimester.<sup>631–636</sup> Although some series report acceptable maternal and fetal outcomes during all trimesters,<sup>637,638</sup> there remains some risk of preterm labor with surgery during the second trimester (4.5%–5.5%).<sup>632,639,640</sup> US evaluation of the fetal thyroid is reasonable to gauge development in anticipation of any issues requiring treatment at birth, such as fetal

goiter causing airway compromise.<sup>641–645</sup> In pregnant patients undergoing thyroidectomy, consultation with a high-risk obstetrics team is advised, including documentation of immediate perioperative fetal heart tones.<sup>646,647</sup>

## GOITER

Goiter is a clinical term used to describe enlargement of the thyroid gland; it is often further defined by relationship to iodine status, morphology (diffuse vs nodular), functional activity (nontoxic vs toxic), hereditary relationship (familial vs sporadic), and anatomic location (cervical vs mediastinal). The causes of goiter are multifactorial and depend on genetic susceptibility interacting with environment.<sup>648</sup> The definition of goiter has been debated over many decades without consensus;<sup>87</sup> a normal thyroid gland weighs approximately 10 to 20 gm. While some experts have proposed a particular weight for goiter,<sup>649–653</sup> the ATA has utilized the more generalized term of “benign enlargement.”<sup>80</sup>

Goiter is considered endemic when it is present in more than 10% of a population due to chronic iodine insufficiency, a situation that reduces thyroid hormone synthesis and secretion leading to tissue overgrowth.<sup>654</sup> In the US, dietary iodine has been considered adequate since the 1920s when iodine fortification occurred<sup>655</sup> and the mean thyroid weight fell from 28 g before 1950 to 18 g after 1960.<sup>656</sup> Morphologically, iodine-deficient goiters are often diffuse with a homogenous increase in size and preservation of normal follicle morphology, whereas multinodular goiter (MNG) represents a mixed group of etiologies and histologic features.<sup>657</sup>

Functionally, patients with goiters may be hypothyroid, euthyroid, or endogenously hyperthyroid, and if the patient is hyperthyroid, the cause can be due to GD, a single hyperfunctioning nodule, or TMNG (see “Hyperthyroid Conditions”). Etiologically, in GD, autoimmune thyrotropin receptor antibodies stimulate the TSH-R to increase hormone levels with subsequent diffuse enlargement of the gland,<sup>13</sup> whereas TMNG is often a combination of variously functioning nodules with a balance of biochemical hyperthyroidism thought secondary to constitutive activation of the cAMP signaling pathway.<sup>658,659</sup> Other etiologic factors include cigarette smoking, natural goitrogens such as cassava, Hashimoto thyroiditis and other infiltrative diseases, malignancy, and dyshormonogenesis.<sup>660</sup> Familial clustering and female predominance suggest a genetic predisposition for euthyroid goiter.<sup>657</sup> Rarely, goiter is caused by a TSH-secreting pituitary tumor, thyroid hormone resistance,<sup>661</sup> or (for TMNG) an autosomal-dominant activating germline mutation in the TSHR gene.<sup>662</sup>

Goiter is denoted substernal if mediastinal extension is present, meaning that the gland extends caudally past the sternal notch on physical examination (below), CT imaging, or at the time of surgery. A secondary mediastinal goiter involves the downward growth of an enlarged cervical thyroid and represents the majority of cases, while primary mediastinal goiter (2%) arises from ectopic thyroid tissue with blood supply from intrathoracic vessels.<sup>663</sup>

The most commonly encountered goiters in current US practice are nontoxic and multinodular.<sup>656</sup> In the absence of hyperthyroidism, an inflammatory process, or known malignancy, a goiter is described as nontoxic, which is the subject of the remainder of this chapter.

## Indications for Resection

Surgical treatment of nontoxic goiter is indicated for symptoms related to compression of the trachea, esophagus, RLN, or superior vena cava (see “Indications, Extent and Outcomes of Surgery”). The most common symptoms are nonspecific and include shortness of breath (50%), dysphagia (30%), and voice change

(13%).<sup>667</sup> In a systematic review of the impact of resection, tracheal compression was noted in 9% to 58% with cervical goiter and 35% to 73% with a substernal component.<sup>648</sup> Tracheal compression can cause positional dyspnea, defined as difficulty breathing that improves by position change,<sup>87</sup> and generalized shortness of breath in up to half of patients.<sup>664</sup> When findings suggest substernal extension, CT or MRI should be performed to evaluate for tracheal compression and may aid in surgical planning. After thyroidectomy, 83% of goiter patients with positional dyspnea report improvement or resolution.<sup>87</sup> The effect of thyroidectomy performed for tracheal deviation is unknown. Formally defined obstructive sleep apnea syndrome is associated with goiter;<sup>665</sup> in evaluations assessing the influence of cervical and substernal goiter on tracheal airflow using flow volume loops, 14% to 60% of patients had upper airway obstruction, often without associated symptoms.<sup>666–670</sup> In an analysis that used a validated sleep apnea questionnaire, thyroidectomy significantly improved obstructive sleep apnea symptoms in patients who screened positive before resection.<sup>358</sup>

The radiographic prevalence of goiter-associated esophageal compression (8%) and deviation (14%)<sup>664</sup> are not well studied. Patient-reported swallowing difficulties occur in 10% to 43% of those referred for goiter treatment,<sup>86,317,356</sup> and goiter is also associated with globus sensation.<sup>664</sup> The efficacy of goiter resection for patient-reported swallowing difficulties is unknown.

Goiter resection is also indicated when there is an inability to biopsy lesions of concern, either because of inaccessibility within the thorax or because a high burden of nodularity (innumerable nodules) precludes adequate evaluation. Approximately 9% to 13% of substernal goiters harbor malignancy.<sup>86,317,671–674</sup> Additionally, the natural history of substernal goiter can be progressive growth with development or worsening of symptoms, an observation to consider when deciding on potential surgical intervention.<sup>86</sup> Patients with substernal goiter who have a positive Pemberton sign warrant thyroidectomy.<sup>675,676</sup>

## Nonsurgical Treatment

Medical treatment options for nontoxic goiter include iodine replacement, suppressive T4 therapy, and RAI ablation. Iodine replacement is associated with a decrease in goiter size in areas of severe iodine deficiency,<sup>677</sup> but it is ineffective in regions of iodine sufficiency.<sup>80</sup> In a randomized, double-blind placebo trial of euthyroid patients with nodular goiter in an iodine-sufficient region, suppressive T4 therapy (target TSH 0.2–0.8 mU/l) plus iodine replacement, as well as suppressive T4 therapy alone, mildly decreased thyroid volume at 1 year; neither long-term outcomes nor effect on symptoms were studied.<sup>678</sup> However, suppressive T4 therapy has low efficacy with a modest effect that is temporary, as nodules will regrow to baseline within 1 year of treatment cessation.<sup>679,680</sup> Suppressive T4 therapy is also associated with thyrotoxic symptoms,<sup>681</sup> requires lifelong use, and has been linked to both atrial fibrillation and osteoporosis.<sup>682–684</sup>

RAI ablation has been widely used to treat patients with nontoxic goiter for over 3 decades. In a randomized clinical trial of I<sup>131</sup> versus T4 suppression, at 2 years' time goiter size was reduced by 44% in the former versus 1% in the latter group, with a significant decrease in bone mineral density in T4 suppressed patients as well.<sup>681</sup> Use of recombinant human TSH (rhTSH) enhances RAI uptake, improving its long-term effect and decreasing the required dose.<sup>685–687</sup> Adverse effects associated with RAI use for nontoxic goiter include transient posttreatment thyrotoxicosis due to release of stored hormone, transient or permanent hypothyroidism, initial gland swelling which can pose a problem in large goiters with compromised inspiration at baseline, and rare potential for development of secondary malignancies such as salivary gland cancer and leukemia.<sup>688</sup>

RAI use is not appropriate if there is a suspicious thyroid nodule on imaging or cytology, or if there is pregnancy, impending pregnancy, or inability to tolerate the treatment or its isolation constraints (see “Hyperthyroid Conditions”). In summary, RAI ablation may be considered for benign goiter in selected patients and T4-suppression should be avoided.

## Extent and Conduct of Resection

Whereas medical or RAI therapy may result in partial size reduction of goiter, surgery offers the opportunity for definitive treatment. In the past, subtotal thyroidectomy was a common procedure but the associated high rate of recurrence has led many to recommend total thyroidectomy or initial complete lobectomy (see “Initial Thyroidectomy,” “Reoperation”). A systematic review<sup>689</sup> evaluated 4 randomized trials of total or near-total thyroidectomy versus subtotal thyroidectomy for NTMG<sup>690–693</sup> and reported that recurrence was lower in the total thyroidectomy group (OR 0.05 (95% CI 0.01–0.21);  $P < 0.0001$ ; 1057 participants), the incidence of transient hypoparathyroidism was lower in the subtotal thyroidectomy group (OR 2.47 (95% 1.57–3.88);  $P < 0.0001$ ; 1275 participants), and the incidences of permanent hypoparathyroidism and transient and permanent RLN palsy did not differ. For goiter that is confined anatomically to 1 lobe, lobectomy is a reasonable approach given the low risk of disease development in the contralateral lobe requiring surgical intervention (2%) and the reasonable probability of retaining euthyroid status not requiring T4 replacement (73–78%).<sup>694,694</sup> In short, the extent of thyroidectomy for nontoxic goiter must balance concerns for recurrence with potential morbidity.

### Recommendation 40:

- When surgery is indicated, total thyroidectomy is preferred for treatment of bilateral goiter. (Strong recommendation, low-quality evidence)**
- When the contralateral lobe is normal, lobectomy and isthmusectomy is recommended for treatment of unilateral goiter. (Strong recommendation, low-quality evidence)**

## Diagnosis and Preoperative Management

Because symptoms associated with nontoxic goiter (above) can alter management, clinicians should routinely query patients about potential symptoms related to local mass effect (see “Initial Evaluation”). On physical examination, a goiter may be graded by World Health Organization criteria: Grade 0—nonpalpable/not visible; Grade 1a—Palpable but not visible even in full extension; Grade 1b—Palpable in neutral position/visible in extension; Grade 2—visible in normal position of the neck/no palpation required to make diagnosis; Grade 3—visible at a distance. Substernal goiter is diagnosed when the full extent of an enlarged thyroid cannot be palpated with the patient's neck extended, even with deglutition or supine. A suboptimal exam may occur with obesity, a short thick neck, or kyphosis; in such cases CT or MRI imaging may be useful for diagnosis if US or exam fails to define the inferior thyroid border. A preoperative voice assessment is advised (see “Initial Evaluation”) and further laryngoscopic evaluation is reserved for those with voice change or history of previous anterior neck surgery.<sup>696</sup>

Preoperative imaging of goiter starts with cervical US (see “Imaging”). If the inferior edge of the thyroid lobes cannot be identified on US or there is clinical concern for a substernal component (above) cross sectional imaging is recommended. CT or MR imaging is recommended to determine the smallest cross-sectional area of the trachea, and surgeon review of images is often helpful as tracheal compression is not always reported radiologically. Correlation between CT and CXR is poor in this respect and CXR should not be used for this purpose.<sup>86,664,697,698</sup>

**Recommendation 41: Cross sectional imaging of goiter is recommended if there is concern for a substernal component. (Strong recommendation, moderate-quality evidence)**

Ninety-eight percent of substernal goiters can be removed through a cervical incision.<sup>663,697</sup> Anecdotally, CT images showing caudal extent past the top of the aortic arch, to below the arch, or to the carina, are increasingly strong reasons to involve thoracic surgery preoperatively, and additional factors include intrathoracic goiter that appears larger than the thoracic inlet, involves the posterior mediastinum, compresses the superior vena cava, or is suspicious for malignancy on imaging.<sup>663,769,700</sup> Thoracic consultation may also be important to inform the patient of additional morbidity if there is concern that substernal goiter cannot be removed cervically, and in the rare situation of primary mediastinal goiter, which is completely separate from the cervical thyroid gland, precluding removal through a cervical approach.

### Intraoperative Management

Surgery for a large cervical and/or substernal goiter is multifaceted and best handled by experienced thyroid surgeons<sup>701</sup> (see “Indications, Extent, and Outcomes of Surgery”). An anesthesia team experienced in managing complex airway issues is also vital if there is significant tracheal compression, and video-scopic laryngoscopy with awake fiberoptic intubation and/or rigid bronchoscopy may be useful when difficult laryngeal exposure is anticipated. In the hands of experienced anesthesiologists, intubation complications (defined as >2 intubation attempts) are uncommon, reported in up to 11% of goiters > 600 g.<sup>80,702,703</sup> In some instances, goiter size and location may prevent rescue tracheostomy, a potential situation that should also be discussed preemptively by the anesthesia and surgery teams. Other considerations may include the need for large-bore intravenous access if concern for blood loss is high, the location of such access if the large veins within the chest could be compromised in the resection, the need for a type and screen, placement of an arterial line and/or Foley catheter, and use of an operating room equipped to manage a potentially extensive procedure including median sternotomy or thoracotomy. If RLNM is being used (see “Adjuncts and Approaches”) the team should keep in mind that with resection of a large goiter, manipulation of the larynx and trachea can malposition the endotracheal tube and loss of signal may result.<sup>704</sup>

**Recommendation 42: When performing surgery for substernal goiter, good communication, preparation and cooperation of experienced surgical and anesthesia teams is recommended. (Strong recommendation, low-quality evidence)**

To lift a goiter cephalad and facilitate its cervical delivery, the patient should be positioned with optimal extension of the neck as allowed by habitus and comorbidities. The chest should be prepped and draped if a sternal split is anticipated. The approach is typically a collar incision placed approximately 1 to 2 fingerbreadths above the sternal notch. In managing bilateral goiter, many surgeons resect the larger lobe first while others selectively approach the smaller lobe to facilitate later delivery of the larger lobe into the neck. Early ligation and division of the superior vascular pedicle often assists in cervical delivery of a thoracic component, along with sequential placement of tissue clamps and delicate use of digital mobilization. Selective early division of the isthmus may allow better access to the medial inferior vessels. Delivery of the substernal component is usually necessary before the RLN can be identified in the tracheoesophageal groove, but occasionally the nerve is displaced anteriorly onto the parenchyma of the thyroid gland making it more vulnerable to injury; taking this anatomic possibility into consideration, delivery under

direct visualization is preferred to a blind sweep of the finger which should be done with caution.

Drain placement has not been shown to improve outcomes and may increase length of hospitalization and postsurgical infection,<sup>705,706</sup> (see “Postoperative Care and Complications”). In the setting of goiter, drains have not been studied but with substernal goiter resection are occasionally used.

In a National Inpatient Sample database study, patients undergoing surgery for substernal goiter versus cervical thyroidectomy were more likely to experience iatrogenic pneumothorax (adjusted OR 5.440; CI 5.2.01–9.33).<sup>707</sup> Although this complication is rare, with any concern there should be a low threshold for obtaining a postoperative CXR. Other adjusted complications specific to the substernal goiter population include hemorrhage or hematoma [OR 1.34 (1.09–1.65)], respiratory failure [1.94 (1.48–2.55)], and postoperative hypocalcemia [1.44 (1.28–1.62)].<sup>707</sup>

An extubation consideration specific to goiter is concern for tracheomalacia, a condition traditionally thought to arise from long-standing extrinsic compression impairing the structural integrity of the tracheal rings and, giving rise to dynamic airway collapse >50% of diameter.<sup>708</sup> Today, there is debate as to the existence of this phenomenon, and it is recognized that some cases have actually represented bilateral RLN paralysis. In a systematic review, tracheomalacia related to a large goiter was rare (0.8%–10%) and most often handled without tracheostomy.<sup>663</sup> Treatment options include tracheostomy, prolonged endotracheal intubation, internal stenting, and noninvasive positive pressure intubation.<sup>709</sup>

### ADJUNCTS AND APPROACHES

While the basic principles of safe thyroidectomy have remained constant since the early 20th century, numerous technical adjuncts have been introduced, the most common and current of which are discussed here.

#### Energy-based Vessel-sealing Devices

Control of the extensive vascular system of the thyroid has traditionally been achieved using fine ties, titanium clips, and electrocautery (see “Initial Thyroidectomy”). In addition, in the past few decades 2 types of adjunctive energy-based vessel-sealing devices have achieved widespread use. The electrothermal bipolar device (Ligasure) relies on bipolar cautery to seal blood vessels, and in many retrospective and prospective studies produces equivalent rates of RLN injury, hematoma, and hypoparathyroidism when compared to conventional ligation technique.<sup>710–715</sup> Most studies also demonstrate decreased operative time compared with conventional knot-tying, typically in the range of 5 to 10 minutes per operation.<sup>710–715</sup> The ultrasonic coagulator (Harmonic) uses an ultrasonic shear technique to seal and divide blood vessels, and in retrospective and prospective studies has rates of RLN injury, hypoparathyroidism, and hematoma that are equivalent to conventional technique;<sup>716–722</sup> a multicenter prospective randomized trial in Italy also identified decreased operative blood loss.<sup>716</sup> All studies of the ultrasonic coagulator have shown decreased operative time, typically in the range of 10 to 30 minutes per operation.<sup>716–722</sup> The 2 devices have also been compared in a number of clinical trials, predominantly with no observed differences in complication rates or operative time;<sup>723–728</sup> although some studies found decreased operative times for the ultrasonic coagulator.<sup>723,724</sup> In 2 systematic reviews examining 35 randomized trials of >4000 thyroidectomy patients, the safety and efficacy of energy-based devices were comparable to conventional knot-tying, and both adjuncts reduced operative time with the ultrasonic coagulator an average of 6 minutes faster.<sup>729,730</sup>

## Intraoperative Assessment of Nerve Function

Traditional methods for avoiding nerve injury during thyroidectomy rely on both intraoperative visualization and knowledge of the normal and variant RLN anatomy (see “Initial Thyroidectomy”). Reported rates of permanent RLN dysfunction after thyroidectomy are typically low (<1%–5%) although due to several factors, reports may underestimate the true incidence (see “Postoperative Care and Complications”).<sup>731</sup> In an attempt to reduce dysfunction, over the past few decades RLNM has become an increasingly popular adjunct in thyroidectomy. At a minimum, its use (below) requires preoperative planning, significant expertise, and avoidance of neuromuscular blockade after anesthetic induction.

The efficacy of RLNM has been studied extensively, including several large-scale multi-institutional trials, both prospective and retrospective.<sup>399,732–739</sup> However, no study has demonstrated a significant difference in either transient or permanent RLN injury rates with RLNM use. A 2017 review of 8 meta-analyses confirmed no observable reduction in transient or permanent RLN injury.<sup>740</sup> Routine use of RLNM during total thyroidectomy was not found to be cost-effective compared with visual identification alone. A 2017 study reported that RLNM was potentially cost effective in preventing bilateral RLN dysfunction.<sup>741,742</sup>

Despite these findings, selective use of RLNM is common. Some surgeons advise that use is beneficial during challenging operations such as reoperation, resection of large or substernal goiter, or resection of locally advanced thyroid cancer, citing a systematic review of 10 studies that reported a trend toward decreased rates of temporary and permanent RLN injury when compared to visual identification alone.<sup>743</sup> Although comprising >10,000 nerves at risk, this study was underpowered to detect a significant difference in outcomes. Surgeons who wish to adopt the practice of selective RLNM should be aware that successful utilization requires a learning curve.<sup>744</sup> An area in which RLNM may prove useful during planned total thyroidectomy is in prevention of bilateral RLN injury, and in this regard the concept of staged thyroidectomy based on RLNM findings has gained recent traction. During a planned total thyroidectomy, upon completion of the initial lobectomy, if the stimulated signal has decreased by certain criteria or has been lost, consideration is advised for stopping the operation rather than proceeding and placing the contralateral nerve at risk.<sup>742,745–748</sup> However, false-positive causes of diminished function by RLNM can occur.<sup>749</sup>

The most widely used RLNM systems utilize passive monitoring, in which the presence and quality of the interrogation signal confirm neural integrity, and loss of signal at any point caudal to an injury indicates a nonfunctioning nerve or technical issues. In 2011 an international group of high-volume thyroid surgeons established guidelines for safe use of RLNM, including an algorithm for troubleshooting when loss of signal is encountered.<sup>704</sup> In brief, the surgeon first palpates the posterior aspect of the cricoid cartilage during nerve stimulation to feel for laryngeal twitch (LT), and if LT is present without a corresponding auditory or EMG signal, the anesthesiologist should be asked to reposition the endotracheal tube. If LT is absent, then the RLNM system should be investigated for problems with connections and auditory output, and the anesthesiologist should confirm that the patient is not receiving neuromuscular blockade. The stimulator should also be tested on nearby muscle and if muscular twitch is intact, then ipsilateral RLN injury should be suspected.

Recently, a technique for continuous RLN nerve stimulation via direct placement of a flexible silicon cuff electrode which encircles the vagus nerve has been suggested as a more accurate, real-time technique<sup>750–755</sup> especially for early detection of potential injury via traction or stretch, but does require additional time as well as dissection of the vagus within the carotid sheath. A prospective

multicenter study of >100 patients demonstrated safety.<sup>752</sup> However, a smaller prospective study of continuous vagal nerve monitoring in thyroidectomy was aborted after 2 of 9 patients had serious adverse events (hemodynamic instability and reversible neuropraxia attributed to the monitoring apparatus).<sup>756</sup>

Intraoperative monitoring of the EBSLN has been reported to assist in its identification when compared to visualization alone, with limited data on voice quality outcomes.<sup>757–760</sup> The expected rate of injury to the EBSLN is unknown (see “Laryngology”) and is suspected to be underreported.

**Recommendation 43:** *While it does not prevent RLN injury, RLNM is safe and may assist the surgeon during initial or reoperative thyroidectomy. (Strong recommendation, moderate-quality evidence)*

**Recommendation 44:** *During planned total thyroidectomy, after completion of the initial lobectomy, if RLNM results suggest loss of function, the surgeon may consider stopping the operation for possible completion at a later date. (Strong recommendation, low-quality evidence)*

## Rapid Parathyroid Hormone Testing

Some surgeons use rapid intra- or postoperative PTH testing during total or reoperative thyroidectomy to help determine the likelihood of postoperative hypocalcemia due to hypoparathyroidism.<sup>761–770</sup> The majority of studies are nonrandomized prospective analyses demonstrating some utility. Protocols vary but the most common time points for serum PTH measurements are at the beginning of surgery and around 10 minutes following removal of the thyroid gland, with later postoperative (ie, recovery room) intervals also described. A PTH cutoff of <10 pmol/L is typically used to predict postoperative hypocalcemia.<sup>762,764,767,770</sup> Recommendations on how to manage patients with single-digit PTH levels vary between institutions and include initiation of calcitriol and planning for prolonged hospitalization. In a meta-analysis of 14 studies, intraoperative PTH testing helped predict postoperative hypocalcemia, but there was no difference in utility versus early (within 1–4 h) postoperative PTH measurement.<sup>771</sup> The predictive value of this adjunct will vary with the local rate of hypoparathyroidism after thyroidectomy. Cost efficacy has not been studied.

**Recommendation 45:** *Rapid PTH measurement during or after total or completion thyroidectomy may help to manage patients at risk for hypocalcemia. (Weak recommendation, moderate-quality evidence)*

## Intraoperative Tissue Analysis

Potential use of IOPE in evaluation of thyroid, LN, parathyroid, and other tissues is covered in “Perioperative Tissue Diagnosis.” During thyroidectomy, because the intraoperative identification of parathyroid glands may be difficult due to their small size and similar appearance to surrounding tissues, new technologies for assisting with parathyroid identification (such as autofluorescence) continue to be reported and evaluated.<sup>772–778</sup>

## Remote-Access Approaches

While thyroidectomy via cervical incision remains the standard approach (see “Initial Thyroidectomy”), numerous remote-access techniques have gained popularity internationally, and can each be performed endoscopically or robotically, including the transaxillary approach<sup>779,780</sup> the bilateral axillo-breast approach (BABA),<sup>781,782</sup> the posterior “facelift” approach,<sup>783</sup> and recently a transoral endoscopic vestibular approach (TOETVA).<sup>784</sup> Remote-access approaches have not achieved widespread use in the US,<sup>785</sup> a fact that may relate to differences in cultural values, habitus, disease severity, surgeon preference, and learning curves. In a US national

database study of thyroid cancer patients undergoing thyroidectomy from 2010 to 2011, 225 patients received a robotic approach compared to >68,000 who had conventional thyroidectomy.<sup>786</sup>

The primary advantage of remote-access thyroidectomy is improved cervical cosmesis. Several Asian studies have reported increased patient satisfaction with cosmetic results following remote-access thyroidectomy compared to cervical thyroidectomy.<sup>783</sup> Data regarding other outcomes, including complications, are mixed, and data on long-term outcomes are lacking. A meta-analysis of 11 studies of robotic transaxillary and BABA thyroidectomy, identified increased operative time, hospital stay, and rate of transient vocal fold dysfunction for robotic versus conventional thyroidectomy, while blood loss, hematoma, and permanent vocal fold dysfunction rates were similar between groups.<sup>787</sup> In terms of cost, remote-access approaches require longer operating times and additional specialized equipment.<sup>788</sup> A 2016 ATA consensus statement concluded that remote-access thyroidectomy may be considered in selected patients with unilateral small thyroid nodules who wish to avoid neck incision, and should only be performed in high-volume centers by surgeons with expertise in both thyroid and endoscopic or robotic surgery.<sup>783</sup>

**Recommendation 46: Remote-access thyroidectomy should only be performed in carefully selected patients, by surgeons experienced in the approach. (Strong recommendation, low-quality evidence)**

## Hemostatic Agents

A wide variety of topical hemostatic agents are currently available with the intention of facilitating surgical hemostasis, but data are limited concerning their effectiveness in preventing bleeding. A 2013 randomized study of oxidized cellulose patch (Surgicel) in thyroidectomy patients reported trends toward higher rates of hematoma, increased postoperative drain output, and longer hospital stay when compared with untreated patients,<sup>769</sup> and the authors concluded that this agent was not helpful and potentially harmful.

Although drains are not typically used in thyroidectomy in the US (see “Initial Thyroidectomy”), a 2009 Italian study utilizing a matrix hemostatic agent with human recombinant thrombin Floseal demonstrated treatment reductions in drain output, operative time, and hospital stay; however, rates of hematoma were not different.<sup>790</sup> In a multicenter prospective randomized trial, the combined use of this agent and the ultrasonic coagulator reduced drain output and operative time, but again with no difference in rate of neck hematoma compared to conventional thyroidectomy.<sup>791</sup> A 2005 Canadian prospective randomized study of fibrin sealant (Tisseel) in thyroidectomy demonstrated 44% less drain output but no differences in hematoma, hospital stay, or other outcomes.<sup>792</sup> Additional concerns have been raised regarding the cost efficacy of topical hemostatic agents and the potential risks of infection with use of human-derived products.

## LARYNGOLOGY

Responsible for vocal fold motion, the bilateral RLNs control all intrinsic muscles of the larynx except for the cricothyroid muscle, which is innervated by the bilateral EBSLNs which lengthen and tense the vocal folds to modulate pitch and voice projection. Vocal fold dysfunction (VFD) can arise prior to thyroidectomy from prior cervical or mediastinal surgery, RLN involvement by central neck or mediastinal cancer, and other causes including idiopathic.<sup>793</sup> During thyroidectomy, VFD can be caused by direct injury related to the endotracheal tube or other tubes (nasogastric, temperature probe, etc.), during intubation or extubation, and by operative impairment of the RLN, vagus nerve, or ESBLN, with the latter situation less well

characterized. VFD can be partial (paresis), complete (paralysis), temporary (resolves within 6 months of surgery), permanent (no resolution 12 mo after surgery), and unilateral and/or bilateral (see “Postoperative Care and Complications”).

A 2009 meta-analysis including more than 25,000 patients undergoing thyroidectomy reported a temporary VFD rate of 9.8% (range 1.4%–38%) and a permanent rate of 2.3% (0%–18.6%).<sup>794</sup> Factors such as age, comorbidities, complexity, and severity of disease (malignancy, thyroid size, inflammation, anatomic factors), extent of dissection, and surgeon experience are associated with VFD risk after thyroid surgery.<sup>795</sup> Less commonly, VFD may be due to intubation alone; in a large retrospective study of 31,217 patients undergoing elective surgery, 0.077% experienced vocal fold paralysis believed to be due to intubation alone.<sup>796</sup>

The impact of VFD is significant, affecting quality of life and in some cases having an adverse economic impact.<sup>797</sup> Rarely, associated swallowing dysfunction or significant preoperative pulmonary compromise may lead to intolerance of unilateral VFD and even to a requirement for tracheotomy and/or gastrostomy. Due to the possibility of airway compromise if bilateral VFD were to occur, the potential need for tracheostomy should be considered. Because laryngeal function is so important, a number of thyroid-related societies have published statements or guidelines on perioperative assessment of changes in voice, swallowing and respiratory effort.<sup>3,793,798–800</sup> The method, timing, and indications for this assessment have not been standardized.<sup>801</sup>

## Preoperative Evaluation

Preoperative knowledge of vocal fold abnormalities may alter the conduct or extent of operation or delay thyroidectomy. Laryngeal assessment may be functional or anatomic in nature. The utilized methods vary widely by provider, specialty, and volume and complexity of thyroid operation.<sup>95,802–804</sup> Commonly used methods include auditory assessment, mirror examination, transcutaneous laryngeal ultrasound (TLUS), flexible laryngoscopy, and videolar-yngostroboscopy.<sup>161,162,696,800,804–806</sup>

When evaluating patients for thyroidectomy the surgeon should assess voice function and quality (see “Initial Evaluation”). Most deem simple auditory assessment by the surgeon to be an acceptable initial method. Although subjective, a recent retrospective review of 464 patients found that voice assessment by the surgeon combined with knowledge of prior neck surgery was more reliable than patient-reported voice change; however, voice quality was not assessed in this study using a validated instrument.<sup>801</sup> Clinically, in the absence of poor pulmonary function, a sustained maximum phonation time (MPT) <10 seconds (due to excessive air escape from incomplete glottic closure) may suggest vocal fold dysfunction.<sup>807</sup> Vocal quality may also be assessed by structured listening and questioning of patients and family members; common tools include the Grade, Roughness, Breathiness, Asthenia, and Strain (GRBAS) Scale, the Consensus Auditory-Perceptual Evaluation of Voice Clinical Protocol,<sup>808</sup> and the Voice Handicap Index (VHI).<sup>809–812</sup> In a meta-analysis, only 3% of patients reporting preoperative dysphonia had VFD after thyroidectomy, instead having conditions such as polyps, gastroesophageal reflux, allergies, and other sources of inflammation. Conversely, documented VFD occurs with a wide range (0%–87%) when patients report no changes in voice quality.<sup>813,814</sup>

Anatomic assessment of vocal fold function can be performed in the office by indirect mirror examination, TLUS, or indirect flexible laryngoscopy. Indirect mirror examination is simple to perform and has little to no associated cost but may not provide adequate visualization in all cases and is not tolerated by some patients.<sup>796</sup> Introduced within the past decade, TLUS may be unable

to visualize the vocal folds due to calcified thyroid cartilage (more common in older patients and men) or body habitus, but with clear visualization of equal and symmetric bilateral motion has equal sensitivity and specificity to other methods, moreover is safe, performed without discomfort, has a short learning curve (<50 cases),<sup>155</sup> and may be performed at the time of office US, thereby minimizing cost. If there is any question of inadequate visualization of the vocal folds, indirect flexible laryngoscopy should be performed.<sup>153,155,808,811–815</sup>

Prior to thyroidectomy, visualization of the vocal folds is recommended routinely by some medical societies, and selectively by others for patients determined to be at risk<sup>3,95,794,800,804</sup> including those with notable voice changes, known VFD, prior neck, mediastinal, cardiac or upper thoracic surgery, apparent invasive malignancy, large substernal goiter, or extensive LNM.<sup>3,95,800</sup> When the vocal folds are visualized, the incidence of preoperative VFD among patients with TC ranges from 1.7% to 9.6% (prevalence 0.69%–4.3%).<sup>815,816</sup> In patients without concerning findings or comorbidities, the incidence of preoperative VFD is lower at 0% to 3.5%.<sup>664,696,802,806,813,817–819</sup> In situations without obvious concern for VFD, a recent retrospective study reported that routine preoperative flexible laryngoscopy is not cost-effective.<sup>696</sup>

**Recommendation 47:** *In preoperative discussion of thyroidectomy, the surgeon should disclose to the patient the possibility, likelihood, and implications of permanent vocal fold dysfunction. (Strong recommendation, moderate-quality evidence)*

**Recommendation 48:** *Prior to thyroidectomy, laryngeal examination should be performed in patients determined to have vocal abnormalities as assessed by the surgeon, pre-existing laryngeal disorders, prior at-risk surgery, or locally advanced thyroid cancer. (Strong recommendation, low-quality evidence)*

## Intraoperative Events

Intraoperative events that can cause VFD (see “Postoperative Care and Complications”) include: 1) intubation resulting in vocal fold laceration, hematoma, edema or rupture; arytenoid dislocation; formation of chronic granuloma or polyp; 2) thermal or traction-related nerve trauma (ie, use of energy devices too close to a nerve; unintentional clamping, ligation or transection); or 3) nerve transection (intentional or rarely unintentional)(see “Postoperative Care and Complications”). Visual intraoperative identification of the RLN and EBSLN are useful in preventing impairment (above and “Initial Thyroidectomy”). Some degree of functional assessment can be provided by RLNM (see “Adjuncts and Approaches”). Excessive traction on the RLN or a thermal event are common mechanisms leading to paresis or paralysis and may not always be recognized intraoperatively.

## Postoperative VFD Care

If VFD is known or suspected to have occurred intraoperatively, immediate careful observation after extubation should be considered by the entire team (surgery, anesthesia, nursing), assessing in particular for altered respiratory status, stridor, and aspiration of secretions. Immediate management of suspected unilateral VFD varies depending on the setting and severity of the condition. Immediate management of suspected bilateral VFD generally requires direct examination to discern vocal fold position and motion, extent of glottic closure, and presence of edema. With either unilateral or bilateral VFD, the symptomatology and objective findings may prompt additional management with options ranging from simple observation to moderate supportive measures (racemic epinephrine, humidified oxygen, elevated head of bed, steroids) to major supportive measures (continuous positive airway pressure) and rarely to tracheotomy or a laryngeal procedure. Thyroid surgeons should be

well versed in the immediate management of VFD as the situation can be life threatening. However, as long as the airway is protected, and adequate respiration is occurring, care can proceed in a careful and calm manner. If reintubation or tracheotomy is required in the recovery area or elsewhere in the hospital, assistance from anesthesiology and a multidisciplinary airway team should be considered, depending on the acuity and severity of the situation, equipment available, and the specific expertise of the surgeon.

After 24 to 48 hours postoperatively, the reported likelihood of altered vocal quality varies widely (30%–90%) depending on study type and methods.<sup>820–825</sup> Postanesthetic changes in voice may last for up to 2 weeks unless structural damage to the larynx has occurred with intubation.<sup>95,826</sup> The AAO-HNS recommends that voice assessment be performed 2 to 8 weeks postoperatively since in VFD the ideal time for vocal fold augmentation is <3 months after thyroidectomy.<sup>95,785,827,828</sup> Early intervention in those with RLN paresis or paralysis is associated with superior functional outcomes. Another reason for prompt diagnosis of VFD is possible early institution of nimodipine pharmacologic therapy. In a small 2018 prospective study, nimodipine use for 2 to 3 months postoperatively was associated with long-term normalization of the Vocal Handicap Index and maximum phonation time and no atrophy of the paralyzed vocal fold.<sup>829</sup> In a study of 30 vocal fold dysfunction patients, the motion recovery rate was tripled compared with historical controls; nimodipine treatment was not tolerated by 7 excluded patients.<sup>830</sup> In a prospective study of 53 vocal fold dysfunction patients, 67% recovered purposeful motion. Time to recovery was not different when nimodipine was begun within 15 days, between 15 and 30 days, and after 30 days.<sup>831</sup>

EBSLN dysfunction reduces the highest obtainable fundamental frequency of the projected voice,<sup>832,833</sup> typically resulting in a voice that is low pitched, gravelly, soft, and/or cannot be raised to shout or reach high notes.<sup>793–795,823,834–849</sup> Neuromonitoring can be used intraoperatively to assist with identification and preservation of the EBSLN.<sup>759</sup> However, EBSLN dysfunction can be difficult to assess and confirm as currently there is no consensus for diagnostic findings on laryngoscopy.<sup>832,850,851</sup> Even laryngeal electromyography of the cricothyroid muscle, which is considered the standard for diagnosis of EBSLN paralysis, has limitations regarding interpretation of results.<sup>832,852</sup> Because reliable diagnosis is difficult, baseline rates of EBSLN dysfunction and recovery after thyroidectomy are not well understood. When assessed during thyroidectomy by RLNM, reported EBSLN injury rates range from 0% to 58%, with permanent paralysis in 0% to 5%.<sup>794,795,842,844–849</sup> Although the potential for EBSLN dysfunction is often cited in the thyroidectomy literature, it is unclear if treatment recommendations would significantly change outcomes. Voice therapy is most commonly employed for EBSLN injuries but has inconsistent results.<sup>832,852</sup>

An area of continued debate among thyroid surgeons is routine postoperative anatomic assessment of the vocal fold motion. Two recent decision analyses found that routine laryngoscopy for all patients was not cost-effective.<sup>98,816</sup> In general, because patients with VFD may be asymptomatic,<sup>847</sup> the extent of investigation may hinge on the outcome to be assessed, for example, voice quality as it impacts quality of life versus accurate assessment of complication rates. In the first situation, auditory assessment alone is deemed by multiple authors and medical societies to be sufficient.<sup>3,95,793,798,843,844,849</sup> In the latter circumstance, routine postoperative anatomic testing is necessary utilizing mirror exam, TLUS, flexible laryngoscopy, or videolaryngostroboscopy. A retrospective study of over 1000 RLNs at risk revealed that only 6% of patients reporting significant voice changes after thyroidectomy had VFD, and 44% of patients with documented dysfunction were asymptomatic.<sup>853</sup> In a large retrospective study of over 5000 patients from the

Scandinavian Quality Registry, the incidence of VFD from groups performing routine postoperative laryngeal examination was nearly twice that of groups utilizing subjective voice assessment.<sup>802,854</sup> Surgeons should strive to know their own rates of temporary and permanent VFD both to accurately inform patients and assess the need for changes in operative technique.

**Recommendation 49:** *Voice assessment should be performed at the postoperative visit. (Strong recommendation, low-quality evidence)*

**Recommendation 50:** *After thyroidectomy, laryngeal examination should be performed in patients with known or suspected new RLN dysfunction or aspiration. (Strong recommendation, moderate-quality evidence)*

Patients with known or suspected VFD, or those with particular concern about their voice after thyroidectomy, may be referred to a laryngologist for additional evaluation and possible treatment. A speech pathologist will in turn often become involved. Early referral (2–8 wk postsurgery) to a laryngologist in combination with early intervention results in superior voice outcomes.<sup>785,827,828</sup> Often, paresis improves over 6 to 12 months, but earlier short-term intervention with nimodipine (above), temporary vocal fold medialization, or another procedure may benefit patients with severe symptoms until the need for definitive treatment can be determined.<sup>785,827,828</sup> Long-term treatment options for unilateral RLN paralysis may include injection of bulking agents, thyroplasty, arytenoid adduction, and reinnervation procedures. Depending on the resting position of the paralyzed vocal fold, management options for bilateral paralysis may include tracheostomy, cordotomy, arytenoidectomy, suture lateralization, reinnervation, electrical pacing, and/or CPAP.

**Recommendation 51:** *If vocal fold motion impairment is suspected or identified, early referral of the patient to a laryngologist is recommended. (Strong recommendation, moderate-quality evidence)*

## FAMILIAL THYROID CANCER

More than 90% of all TC is sporadic in nature, secondary to somatic genetic alterations.<sup>855</sup> Approximately 3% to 9% of TC is FNMTC,<sup>856</sup> with PTC the most common histologic subtype (85%–91%), followed by FTC (6%–10%), ATC (1.6%), and HTC.<sup>857–859</sup> FNMTC is nonsyndromic in 95% of cases. MTC accounts for 3% to 5% of all TC with approximately 25% of cases being hereditary.

## Genetic Testing

The American Society of Clinical Oncology has published iterative policy statements on genetic and genomic testing for cancer susceptibility, stressing the importance of communication with the patient about the purpose of the genetic testing, the potential outcomes and implications for the patient and family members, and the risks of cancers related to the genes being tested.<sup>860</sup> Unfortunately, direct-to-consumer testing removes provider involvement and leads to inadequate counseling and informed consent; moreover, while concurrent multigene testing is increasingly recognized as an efficient method of evaluating multiple high-penetrance genes, a considerable proportion of such panels will identify variants of uncertain significance (below) associated with over-interpretation.<sup>861–863</sup> Additionally, many multigene panels include moderate-penetrant genes of unclear clinical utility. For these reasons, the decision to perform genetic testing, as well as the associated counseling and interpretation of results, should involve an experienced professional team, which ideally includes a genetic counselor.

**Recommendation 52:** *Germline genetic testing should include pre- and post-test counseling by a knowledgeable health care provider. (Strong recommendation, low-quality evidence)*

## Hereditary Nonmedullary TC

### Nonsyndromic Familial Nonmedullary TC (NFMNMTTC)

NFMNMTTC is defined by the presence of follicular cell-based TC with 3 affected first-degree relatives<sup>864,865</sup> in the absence of predisposing environmental risk factors<sup>856</sup> or a known familial syndrome. The genetic basis of NFMNMTTC is uncertain, and molecular etiology may result from cumulative occurrence of several lower penetrance susceptibility genes, to date including SRGAP1, TITF-1/NKX2-1, FOXE1, telomere–telomerase complex, and RTFC, with further validation necessary.<sup>866–870</sup> Chromosome loci such as *TCO* (19q13.2), *NMTC1* (2q21), *fPTC/PRN* (1q21), *MNG1* (14q32); *FTEN* (8p23.1-p22), have also been implicated, though the candidate genes at these locations are unknown.<sup>871–875</sup> Currently, there is no clinically available germline testing.

NFMNMTTC often occurs at an earlier age than its sporadic counterpart, with conflicting reports about aggression.<sup>876–879</sup> A meta-analysis of 12 studies including 12,471 patients found that patients with NFMNMTTC had a higher recurrence rate, higher risks of multifocality, bilaterality, and extrathyroidal extension, and lower disease-specific survival than those with sporadic disease.<sup>880</sup> “Anticipation,” namely, the finding that younger generations have earlier and more severe features of malignancy than their predecessors, has also been observed.<sup>881,882</sup> A prospective cohort study using annual US surveillance found that TC prevalence in at-risk individuals from kindreds with 2 first-degree affected relatives was the same as for the general population (4.6% vs 4.5%) while the corresponding rate of TC in families with three- or more first-degree affected relatives was significantly higher at 22.7%;<sup>883</sup> the youngest age at TC diagnosis by screening was 18 years. The age of screening initiation is unclear, but an acceptable algorithm could be to begin screening 5 years prior to the youngest adult family member diagnosed, with the understood caveat of potentially finding and managing benign or indeterminate thyroid disease.<sup>884</sup> Although no data exist to support prophylactic thyroidectomy in NFMNMTTC, with a clinical diagnosis the surgical decision about extent of thyroidectomy should take into consideration the potentially higher rates of observed multifocality and bilaterality.

**Recommendation 53:** *DTC screening should be performed in at-risk individuals from families with three or more affected first-degree relatives. (Strong recommendation, low-quality evidence)*

### Syndromic FNMTC

Five percent of FNMTC cases are minor components of inherited cancer syndromes (below) that are often associated with well-defined driver alterations; testing of known susceptibility genes is recommended when a syndromic phenotype is recognized (see Table 4). Diagnosing a hereditary syndrome in an affected individual properly allows both personal evaluation of other associated diseases and screening of potentially affected family members.

**Familial Adenomatous Polyposis.** FAP is an autosomal-dominant disease caused by inactivating mutations of the adenomatous polyposis (*APC*) tumor suppressor gene located on chromosome 5q21. FAP is typified by multiple gastrointestinal adenomatous polyps (especially in the colon) with malignant potential. Gardner syndrome is an FAP variant that also has extracolonic manifestations such as fibromas, osteomas of the mandible, epithelial cysts, congenital hypertrophy of the retinal pigment epithelium (CHRPE), and



upper GI hamartomas. TC is associated with FAP, the most common type being PTC with 20% to 40% possessing a cribriform-morular variant histological pattern.<sup>885</sup> Recent prospective registry screening programs suggest the prevalence of PTC in FAP is 2.6% to 11.8%.<sup>886–898</sup>

Screening recommendations for TC in FAP patients vary widely, from no screening,<sup>889,890</sup> to screening only in those with CHRPE, to screening by neck palpation<sup>891</sup> or with US beginning at age 16<sup>887</sup> or as an adult.<sup>892</sup> The relative rarity of FAP and lack of tumor genetic analysis to confirm an APC-based etiology make determinations of prevalence challenging. Because cribriform-morular variant PTC represents only 0.16% of all PTC,<sup>893</sup> it is reasonable that any patient presenting with this rare histology be evaluated for FAP.

**Cowden Syndrome.** Cowden syndrome (CS) is an autosomal-dominant disease characterized by macrocephaly, mucocutaneous lesions, hamartomatous changes, and epithelial tumors of the thyroid, breast, kidney, colon, and endometrium. In 1995 and subsequently, an international consortium created and refined criteria for CS diagnosis, detailing pathognomonic major and minor criteria to aid in initiation of genetic testing.<sup>894–896</sup> Whereas early studies suggested that 85% of CS patients harbored the *PTEN* tumor suppressor gene mutation,<sup>897,898</sup> using more relaxed CS criteria, a prospective study of 3042 probands found that 9.5% patients had a *PTEN* mutation;<sup>899</sup> the authors devised a clinical scoring test to prompt *PTEN* testing and recommended that patients <40 years with endometrial, thyroid, or breast cancer be evaluated for other features of a *PTEN* germline mutation, particularly macrocephaly.<sup>899</sup> Overrepresentation of pediatric presentation as well as FTC histology are also associated with *PTEN*-mutated CS.<sup>900</sup>

Because the lifetime risk of developing TC is 35% in patients with a known *PTEN* mutation,<sup>901</sup> consideration may be given to screening US in this population, but no published data yet exist. Prophylactic total thyroidectomy has been suggested for those *PTEN*-mutated CS patients with developmental delay from severe autism, a diagnosis that may be associated impractical lifelong screening;<sup>76</sup> however, the burden of daily thyroid hormone replacement and the low likelihood of FNMTC (35%) should also be considered. Other germline mutations responsible for CS include alterations in *SDHB-D*, *PIK3CA*, *AKT1*, *SEC23B*, and *KLLN* promoter methylation.<sup>856</sup>

**Carney Complex.** Carney complex (CNC) is an autosomal-dominant disease with manifestations including myxomas of the soft tissues and heart, spotty skin and mucosal pigmentation, blue nevi, schwannomas, tumors of the adrenal and pituitary glands, Sertoli cell tumors, thyroid nodules, and TC. CNC is diagnosed if 2 of these features are present, or 1 major manifestation and an affected first degree relative, or an inactivating *PRKARIA* mutation.<sup>902</sup> *PRKARIA* is thought to be a tumor suppressor gene, and a *PRKARIA* mutation or deletion was present in 73% of 353 patients evaluated from the CNC consortium.<sup>903</sup> The prevalence of thyroid cancer or nodules is 5% in CNC.<sup>902,904,905</sup> No screening programs have been described and given the relative rarity of TC in CNC, no prominent thyroid histology has been identified and no evidence exists to support prophylactic thyroidectomy.

**Werner Syndrome.** Werner syndrome (WS) is an autosomal-recessive disease characterized by premature aging beginning in the second decade of life, including scleroderma-like skin changes, cataracts, atherosclerosis, osteoporosis, and premature graying and hair loss. Further manifestations include soft tissue calcification, hypogonadism, and high occurrence of neoplasms. An individual has

the clinical diagnosis if he or she possesses all of the cardinal features and 2 further signs (www.wernersyndrome.org). WS is associated with mutations of the *WRN* gene on chromosome 8p11–21;<sup>906</sup> patients with a clinical diagnosis should be offered genetic testing. In a case series, TC was reported in 16% of 189 patients with WS at a median age of 40.<sup>907</sup> In another series of 845 patients, among the 2.7% who were diagnosed with TC, FTC was the most common (48%), followed by PTC (35%) and ATC (13%).<sup>908</sup> Patients with the clinical diagnosis of WS should be intermittently screened for TC; no data are available on a role for prophylactic thyroidectomy.

**DICER1 Syndrome.** *DICER1* syndrome (DS) is an autosomal-dominant disorder of loss of function in *DICER1*, a protein that cleaves noncoding small RNA precursors to create mature miRNAs. It is characterized by pleuropulmonary blastoma (PPB), ovarian Sertoli-Leydig tumors, multicystic nephroma, pineoblastoma, and multinodular goiter along with other neoplasms. DS penetrance is estimated at <15% for any of the associated manifestations<sup>909,910</sup> which usually present in childhood. Refined criteria for *DICER1* genetic testing include individuals who present with familial multinodular goiter with consideration in isolated cases of pediatric goiter.<sup>911</sup> Treatment with alkylating chemotherapy (for PPB) has been suggested to be a predisposing risk for DTC<sup>912–914</sup> although a case report for a family with *DICER1* mutation and no history of chemotherapy described multiple first-degree relatives with DTC; the youngest age of diagnosis was 7 years.<sup>915</sup> No current guidelines for thyroid screening exist, but reasonable suggestions in the literature include thyroid palpation from age 10 years and, if exposure to chemotherapy, thyroid US at 5 years after therapy completion or at age 10 years, whichever occurs first.<sup>911</sup>

**Papillary Renal Neoplasia.** Papillary renal neoplasia is a type of syndromic FNMTC in which the authors mapped a PRN1 locus on chromosome 1q21 in a single family with PTC, benign thyroid nodules, and papillary renal neoplasia.<sup>873</sup>

**McCune-Albright Syndrome.** McCune-Albright syndrome is caused by a post-zygotic somatic activating mutation in *GNAS* that is associated with fibrous dysplasia and endocrinopathies, including thyroid nodules and dysfunction; because it is a somatic mutation, there is no inheritable risk.<sup>916</sup>

**CHEK2.** Germline mutations in the cell cycle checkpoint kinase 2 (*CHEK2*) tumor suppressor gene may predispose to PTC. A study evaluating 4 founder mutations for *CHEK2* in 936 individuals found those harboring a mutation to be 3.3 times higher risk ( $P < 0.0001$ ) of harboring PTC.<sup>917</sup>

## Hereditary MTC

Mutations of the *RET* proto-oncogene, located on chromosome 10q11.2, are responsible for almost all cases of hereditary MTC, with the majority found in identified codons within exons 10,11,13 to 16. Penetrance of MTC nears 100% in patients who harbor a *RET* germline mutation. The 2015 ATA guidelines on MTC recommend that all hereditary MTC be classified into either Multiple Endocrine Neoplasia (MEN) 2A or 2B.<sup>56</sup>

MEN2A accounts for 95% of MEN2 cases, and may be subdivided into 4 variants: 1) classical MEN2A, in which mutations occur in *RET* codons 609, 611, 618, or 620 of exon 10 or codon 634 of exon 11, and patients uniformly develop MTC and less frequently have pheochromocytoma and pHPT depending on the codon involved; 2) MEN2A with cutaneous lichen amyloidosis, a rare presentation characterized by dermatological lesion(s) in the scapular region of the back corresponding to dermatomes T2-T6, and

associated almost exclusively with *RET* codon 634 mutation; 3) MEN2A and Hirschsprung disease, with the latter occurring in 7% of patients<sup>918–920</sup> due to a mutation in *RET* codon 609, 611, 618, or 620; 4) familial MTC (FMTC), which is now considered a variant of MEN2A and is defined by the presence of a *RET* mutation in families with MTC and no history of pheochromocytoma or pHPT.

Individuals with MEN2B have early onset MTC, often in infancy, with most cases due to the codon M918T *RET* mutation in exon 16. Approximately 50% of patients will develop pheochromocytoma; other manifestations include a typical facies, thickened and everted eyelids, the inability to form tears in infancy, skeletal malformations (marfanoid body habitus, slipped capital femoral epiphyses, scoliosis), and ganglioneuromatosis throughout the digestive tract.<sup>921,922</sup> Individuals with high risk mutations (such as C634) often develop MTC in early childhood; genetic screening, calcitonin measurement, and physical and US examinations should ideally begin by age 3 with strong consideration for prophylactic total thyroidectomy by age five. The phenotypes associated with *moderate risk* mutations (below) are much more varied in presentation; genetic screening and biochemical/radiographic evaluation can begin at approximately age 5 and delaying surgery for years may be a possibility if the findings remain unremarkable. Discussion between the parents and the experienced healthcare team is essential.

Because 1% to 7% of individuals diagnosed with presumed sporadic MTC will harbor a germline *RET* mutation,<sup>923,924</sup> the literature advises that all patients diagnosed with apparent sporadic MTC should undergo genetic testing in the setting of appropriate pre- and postgenetic counseling.<sup>51</sup>

**Recommendation 54:** All patients diagnosed with MTC should undergo genetic testing for a germline *RET* mutation. (Strong recommendation, high-quality evidence)

At a minimum, *RET* testing in presumed sporadic MTC currently includes exons 8, 10, 11, 13 to 16; sequencing of the entire coding region may be performed if no *RET* mutation is identified and there is high clinical suspicion. If *RET* testing confirms a pathogenic mutation in a patient diagnosed with MTC, further workup consists of evaluation for pheochromocytoma and pHPT (in MEN2A) or for pheochromocytoma alone (in MEN2B). If MTC is diagnosed by FNAB prior to surgery, the patient should either undergo genetic testing before resection, or have preoperative biochemical evaluation to rule out the presence of pheochromocytoma and pHPT. A priori knowledge of a MEN2A-associated *RET* mutation allows for non-cervical autografting of a parathyroid devascularized during thyroidectomy to facilitate management of future pHPT. When concurrent pheochromocytoma is diagnosed, its management takes clinical priority over thyroidectomy, whereas when pHPT is concomitantly present it can typically be managed during thyroidectomy (see “Concurrent Parathyroidectomy”).

As sequencing of the entire coding region has become commonplace, more *RET* variants of uncertain significance are being identified for which the mutation pathogenicity and phenotypic expression are unknown. In this setting, intermittent screening for pheochromocytoma and primary hyperparathyroidism is reasonable, but the approach to genetic testing of at-risk family members is challenging. Exome sequencing databases have an increasingly important role. Easily available databanking offers efficient validation of newly discovered mutations implicated in the pathogenesis of all hereditary cancers. This can help determine the pathogenicity of the genetic alteration and how to best counsel affected individuals.<sup>925</sup>

In 2015, the ATA revised the genotype-phenotype categories denoting levels of risk associated with age of MTC development: *highest risk* includes patients with MEN2B with a M918T *RET* mutation, *high risk* includes patients with a C634 or A883F mutation,

and *moderate risk* includes patients with known pathogenic *RET* mutations other than M918T, C634 and A883F. With a screening diagnosis of *RET* germline mutation, these categories are helpful in guiding the timing of prophylactic total thyroidectomy, defined as removal of the thyroid before MTC develops or while it is clinically unapparent and confined to the gland.<sup>56</sup> Prophylactic thyroidectomy has a survival advantage in MEN2B. The timing and extent of prophylactic thyroidectomy must balance the oncologic benefit of removing the thyroid with the potential risks of hypoparathyroidism and recurrent laryngeal nerve compromise, particularly early in life, and typically requires considerable experience and expertise.

Familial MTC age of onset and course cannot be determined by the kindred’s specific history, which should be used cautiously in counseling.<sup>926</sup> In general, kindred members at risk for the M918T mutation (*highest risk*, associated with MEN2B) should have genetic testing soon after birth and undergo thyroidectomy, ideally in the first year of life, but unfortunately this group only makes up 25% of MEN2B patients.<sup>921,922</sup> Again, discussion between the parents and the experienced healthcare team is essential.

**Recommendation 55:** An experienced multidisciplinary care team should manage patients diagnosed with MEN2A and MEN2B. (Strong recommendation, low-quality evidence)

The goal of total thyroidectomy in familial MTC is to remove all C cells, each of which harbors a *RET* mutation and therefore is at risk for malignant transformation. Because the distribution of C cells is in the superior third of the thyroid lobes bilaterally, care should be taken not leave remnant tissue in situ. In known MTC, whether sporadic or familial in origin, a concomitant CND should be performed (see “Nodal Dissection”). However, CND is not routine in the setting of a prophylactic thyroidectomy in a known germline carrier, but may be needed if abnormal LN are identified pre- or intraoperatively.

## POSTOPERATIVE CARE AND COMPLICATIONS

After total thyroidectomy, testing of thyroid function should be coordinated with the patient’s endocrinologist and/or primary care physician. TSH level should be checked at 6 to 8 weeks postoperatively and T4 dose adjusted accordingly (below).<sup>927</sup> Patients undergoing lobectomy should be aware that they are at risk for developing subclinical hypothyroidism even with the contralateral lobe intact<sup>928–930</sup> and should have their TSH level checked as well,<sup>931</sup> which is especially important if potentially pregnant.<sup>635</sup> The optimal postoperative TSH level depends on multiple factors, including whether the patient has a diagnosis of TC of follicular cell origin and has any ongoing features of hypo- or hyperthyroidism.

## Routine Management

### Documentation/Communication

Clear and detailed documentation is highly recommended. Operative reports should include information about indication(s), informed consent, surgical findings (ie, ETE, LN status, aberrant anatomy), parathyroid gland status, RLN identification and preservation, attending surgeon presence during procedural steps, hemostasis, closure methods, and patient disposition.<sup>393</sup> Electronic health records allow for computerized and/or synoptic operative reporting which can improve documentation and efficiency.<sup>932,933</sup>

While thyroidectomy is generally a safe operation, complications such as hematoma and bilateral VFD with airway compromise can be life-threatening; thus appropriate preparation is essential. The decision between inpatient and outpatient postoperative care also depends on local resources, access for readmission

should an emergency arise, surgeon experience, and in some cases patient preference. It is reasonable to admit patients overnight for pain control, treatment of PONV, or observation with particular risk for hematoma (below). Thyroidectomy is increasingly being performed as an outpatient procedure,<sup>934,935</sup> which in high-volume settings has comparable outcomes and readmission rates to overnight stay after surgery.<sup>934–937</sup>

Prompt communication with referring physician(s) is courteous, helps ensure a cohesive postoperative plan, and provides a reminder of any immediate issues to be handled in a safe and timely manner;<sup>393</sup> if not done preoperatively, the surgical team should consider discussing with the prescribing physician the postoperative resumption of anticoagulants/NSAIDs/aspirin. Clear and simply written postoperative instructions should be provided to the patient and their escort. Specific protocols vary by institution but in general include contact information and “when to call” scenarios in addition to activity, diet, incisional care, and medication instructions. A postoperative visit should be scheduled to evaluate the patient’s recovery, voice, and symptoms, provide potential adjustment of medications, review surgical pathology, and arrange further treatment or follow-up.

### Incision Care

Incision care is a frequently discussed topic. Published evidence does not support the use of over-the-counter scar treatments.<sup>938</sup> In randomized controlled trials, neither onion-extract (eg, Mederma) gels nor vitamin E-based creams improve cosmetic results and in 1 study, vitamin E use resulted in 33% of patients developing contact dermatitis.<sup>938–941</sup>

### Medications

When required, T4 replacement dosing is initially started based on the patient’s weight (0.8 mcg/lb or 1.6 mcg/kg), with adjustments made for age (round up for younger patients, down for older patients), BMI, and pregnancy.<sup>942</sup> If RAI ablation is a possibility, communication with the referring endocrinologist is prudent before starting T4. T4 suppressive dosing should be performed per 2015 ATA guidelines, as there is evidence that maintaining TSH levels < 0.1 mU/L in high-risk nonmedullary TC improves outcomes but is a risk factor for atrial fibrillation and, in postmenopausal women, bone loss in the early postoperative period.<sup>3,943,944</sup> Arrangements should be made for a TSH level to be checked 6 to 8 weeks following initiation or change of T4 dosing. After surgery for hyperthyroidism, antithyroid medications should be stopped and beta-blockade weaned in communication with the prescribing physician (see “Hyperthyroid Conditions”).<sup>13</sup>

### Pain Management

While the Centers for Disease Control and Prevention have published guidelines for the use of opioids for chronic pain, no such guidelines exist for acute/postoperative pain control.<sup>945</sup> However, the CDC guidelines are helpful in underscoring the preference for non-opioid and nonpharmacologic therapy and caution that opioid dependence stems from prescriptions given for acute pain management. Overall, 6% of patients have persistent opioid use 90 days after surgery at rates equal after major and minor surgical procedures (adjusted  $P = 0.18$ ).<sup>946</sup> Moreover, opioid consumption is correlated to the amount prescribed; in a cohort of patients undergoing thyroid and parathyroid surgery, only 20% of opioid doses were used.<sup>947,948</sup> A retrospective study of over 1700 patients undergoing parathyroidectomy and thyroidectomy assessed the effect of a change in prescribing practices to decrease opioid use and increased patient education about nonopioid adjuncts, and reported fewer requests for

additional pain medication after discharge and that many patients did not require any opioid medication.<sup>949</sup> Use of nonsteroidal anti-inflammatory drugs is also effective in reducing opioid use.<sup>950</sup> If opioids are prescribed, the lowest effective, immediate-release options are preferred. Postoperative pain for patients undergoing thyroidectomy is general reported as minimal; 83% of patients needed less than 10 oral morphine equivalents (eg, 1 OMEQ = 5 mg hydrocodone).<sup>951</sup>

#### Recommendation 56:

- Use of nonopioid and nonpharmacologic therapies and patient education should be the first-line pain management after thyroidectomy. (Strong recommendation, moderate-quality evidence)*
- If opioids are prescribed for postoperative pain management, the lowest effective dose of immediate release opioids (< 10 oral morphine equivalents) should be prescribed. (Strong recommendation, moderate-quality evidence)*

## Immediate Complications

### Hematoma

Postoperative bleeding is a well-known complication of thyroidectomy. The reported incidence varies by institution and patient population and is 0.7% to 1.5%, although some single-institution reviews have reported rates as high as 5%. A large US population-based study from 2000 to 2009 reported an incidence rate of 1.3%.<sup>952</sup> Hematoma risk correlates inversely with surgeon volume, and is associated with increased mortality (1.3% vs 0.32%).<sup>935,953–954</sup> Approximately 50% of cervical hematomas requiring reoperation occur within 6 hours and 80% within 24 hours of the operation.<sup>598,935</sup> In a 2016 study of 5156 patients, 89% of hematomas took place within 12 hours of thyroidectomy.<sup>956</sup> Rarely, hematoma can occur days after hospital discharge, and patients should be informed about when to call with concern.

Multiple risk factors for post-thyroidectomy hematoma have been reported, but with inconsistency.<sup>565,920,936,937,938,939</sup> In a 2013 case-control study involving 15 institutions from 3 countries, associated factors included male gender, age >65, smoking, continued use of antiplatelet or anticoagulant medications, GD, total thyroidectomy (vs lobectomy), and drain placement.<sup>598</sup> A single-institution review of 5156 patients reported that male gender, benign pathology, hypertension, and prior thyroid operation were risk factors.<sup>956</sup> A 2015 population-based study of >100,000 thyroidectomies identified male gender, African-American race, history of alcohol abuse, 3 or more significant comorbidities, GD, substernal thyroidectomy, and reoperation as risk factors in the southern US.<sup>952</sup> A 2017 meta-analysis identified only GD as an independent predictor.<sup>599</sup> In reviews focusing on high BMI, postoperative hematoma rates do not appear to differ compared with normal BMI.<sup>957,958</sup>

Prevention of neck hematoma requires meticulous surgical technique (see “Initial Thyroidectomy”) and optimization of medical or pharmacologic factors that may contribute to bleeding (see “Preoperative Care”), that is continued anticoagulation is associated with twice the odds of postoperative bleeding.<sup>598</sup> No device or topical agent has been demonstrated to reduce the incidence compared with conventional vessel ligation (see “Adjuncts and Approaches”).

**Recommendation 57: Patients at higher risk for cervical hematoma should be considered for overnight observation following thyroidectomy. (Weak recommendation, moderate-quality evidence)**

To detect and manage hematoma, immediate postoperative observation and education of recovery room staff, nurses, and

trainees are critical. Safe treatment relies on early detection and expeditious evacuation to prevent or alleviate airway compromise. An emergency evacuation kit should be readily available. The classic sign is tense swelling and expansion under the incision, with an increase in neck circumference, but early hematoma is sometimes subtle and may be difficult to recognize. Ecchymosis is not a reliable indicator as skin bruising and flap edema are common post-thyroidectomy. As hematoma progresses, collected blood compresses the cervical trachea and impairs venous return from the larynx, and patients may develop rapid airway edema with sudden onset of stridor, voice change (“squeaky” or high-pitched), and tachypnea. Other signs can include diaphoresis, tachycardia, increasing local pain, difficulty swallowing, and anxiety or sense of “impending doom.” Decreased oxygen saturation is a late manifestation of airway compromise; normal oxygen saturation is typical in patients with life-threatening hematoma and such measurements should not replace clinical examination and judgment. In all instances of suspected post-thyroidectomy hematoma, the patient must be evaluated immediately at the bedside.

The timing of intervention for post-thyroidectomy hematoma depends on the severity of airway compromise as well as surgeon judgment and setting. If the patient is in extremis, bedside evacuation by opening the cervical incision is performed. If the patient is more stable, they may be transported to the operating room for urgent management. The controlled environment with a full anesthesia team is much preferred if the patient is maintaining an airway and can be brought back immediately. Decompression may be necessary prior to intubation. After the airway is secured, the patient can be positioned, prepped, and draped. The surgeon’s treatment objectives are to remove clotted blood and control the bleeding source(s), which requires opening the incision at all levels, that is skin, platysma and strap muscles, while exploring the deep compartments with caution to avoid RLN or parathyroid injury. In many instances of hematoma, a source of active bleeding is no longer identifiable due to compression. Hematoma can cause secondary pharyngeal or laryngeal swelling that should be discussed with anesthesia prior to safe intubation and extubation.

Nonoperative management of an acute post-thyroidectomy hematoma is not recommended; the surgeon should have a low threshold for cervical exploration and err on the side of caution as untreated hematoma is life-threatening. A few case reports have described successful observation for highly selected patients with minimal swelling and no signs or symptoms of airway compression, but such patients usually presented days or even weeks following operation.<sup>959</sup>

**Recommendation 58: Patients with suspected hematoma after thyroidectomy should be evaluated immediately with appropriate intervention as indicated. (Strong recommendation, low-quality evidence)**

### Recurrent Laryngeal Nerve Dysfunction

Voice changes are common after thyroidectomy. When secondary to vocal fold edema from endotracheal intubation alone, this usually subsides in a few days. If hoarseness persists, or there is coughing, especially while drinking fluids, or there is concern for nerve integrity, patients should be further evaluated (see “Laryngology,” “Initial Evaluation”).

Injury to the RLN is a recognized risk of thyroidectomy. Most series report temporary VFD rates of 0.5% to 10%, and permanent rates of 0% to 5% (see “Laryngology”). In a 2009 systematic review of 27 studies involving >25,000 patients, the average incidences of temporary and permanent VFD following thyroidectomy were 9.8% and 2.3%, respectively.<sup>794</sup> Several risk factors have been described. Reoperations have higher risk than do initial thyroidectomies (see

“Reoperation”)<sup>743,960,961</sup> and in numerous studies, reoperations for TC are associated with higher rates of both temporary and permanent RLN injury, especially if there is tumor involvement of the nerve itself, or if concurrent LND is required.<sup>743,960,962</sup> Goiters, either cervical or substernal, confer higher risk, with at least 1 study correlating the risk of VFD directly with goiter size.<sup>963</sup> Graves disease is a well-described independent risk factor for VFD,<sup>743,960,964</sup> as is the presence of a nonrecurrent laryngeal nerve.<sup>965</sup> BMI has not been shown to affect risk<sup>957,958</sup> nor has the use of RLNM (see “Adjuncts and Approaches”).

Rarely, transection of the RLN may occur or be required during thyroidectomy. In such cases an experienced surgeon should perform reanastomosis, with the purpose not to restore function, but rather to maintain vocalis muscular tone and postoperative voice quality by continued neural stimulation. If the 2 ends of the nerve lie in close proximity, primary reanastomosis is performed using interrupted fine monofilament nonabsorbable sutures (7–0 or finer). If the proximal end of the nerve is not identified, or too great a distance separates them, a nerve graft utilizing ipsilateral ansa cervicalis may be performed; the ansa cervicalis is mobilized from the strap muscle, transected distally, and the mobilized proximal segment is connected to the distal transected end of the RLN. In multiple reports, RLN reanastomosis by either technique<sup>966–969</sup> does not restore vocal fold mobility, but can improve voice outcomes by both subjective and objective voice quality measurements.

**Recommendation 59: If unilateral RLN transection occurs during thyroidectomy, an attempt should be made at repair. (Strong recommendation, moderate-quality evidence)**

In certain instances, the RLN is stretched during thyroidectomy, resulting in transient RLN dysfunction. Administration of calcium channel blockers can improve recovery<sup>970</sup> (see “Laryngology”).

Although a rare event (0.1%–0.4% of cases), bilateral vocal fold dysfunction can be a life-threatening condition in the immediate postoperative period (see “Laryngology”). If there is concern for transection or resection of a nerve and/or loss of RLNM signal, it is essential to communicate this with the anesthesia team and be prepared for reintubation and/or tracheostomy. Following extubation, patients should be evaluated at the bedside for stridor or marked dysphonia.

### Calcium Supplementation, Hypocalcemia, and Hypoparathyroidism

Because 2 contralateral parathyroid glands remain in situ, there is no risk of hypocalcemia with initial lobectomy and no need to measure postoperative calcium level in this setting.

After total or completion thyroidectomy, various institutional and individual surgeon protocols may be used to prevent, detect, and manage postoperative hypocalcemia; in 2018 the ATA released a consensus statement summarizing some of these practices.<sup>971</sup> Often, serum calcium levels (with or without PTH) are measured postoperatively and oral calcium with or without calcitriol supplementation is administered based on the results. Other experts routinely provide prophylactic calcium with or without calcitriol to all patients undergoing total or completion thyroidectomy with low observed rates of symptomatic hypocalcemia.<sup>972,973</sup> As a third alternative, PTH levels are checked intraoperatively or in the recovery room to guide supplementation (see “Adjuncts and Approaches”).<sup>771</sup> In a prospective cohort study of >400 patients, selective dosing of calcium and vitamin D based on PTH levels reduced both the proportion of patients experiencing symptoms of hypocalcemia, and critically low calcium levels.<sup>973,974</sup>

**Recommendation 60:** *To prevent and/or manage postoperative symptoms of hypocalcemia following total or completion thyroidectomy, a strategy for calcium and/or vitamin D supplementation should be considered. (Strong recommendation, moderate-quality evidence)*

Hypoparathyroidism leading to hypocalcemia is a recognized complication of thyroidectomy. Reported rates vary considerably, likely as a result of variations in biochemical definition, follow-up interval, expertise, under-reporting, and the use of rapid intraoperative PTH monitoring (see “Adjuncts and Approaches”). Hypocalcemia is defined by a calcium level below the lower limit of the normal range for an institution’s laboratory with or without associated symptoms such as acral or perioral numbness and tingling, progressing in some cases to muscle cramps, trismus, tetany, or laryngospasm. Transient hypocalcemia occurs commonly in the immediate postoperative period after total or reoperative thyroidectomy, and can also occur with diuretics, vitamin D deficiency, and/or intravenous hydration after any type of surgery.<sup>383,975</sup> Transient hypoparathyroidism is defined by hypocalcemia with elevated phosphorus and/or reduced PTH levels. Permanent hypoparathyroidism is defined by a requirement for calcium and/or calcitriol 6 months following thyroidectomy; when measured off calcitriol, the PTH level is usually low or undetectable. A 2014 systematic review of 115 studies of thyroidectomy reported a median transient hypocalcemia rate of 27% (range 19%–38%), and median permanent hypoparathyroidism rate of 1% (range 0%–3%).<sup>383</sup> Others have reported transient hypocalcemia rates following thyroidectomy as high as 50%, and permanent rates as high as 5%.<sup>383</sup>

Multiple anatomic, clinical, and technical factors can increase the risk of post-thyroidectomy hypoparathyroidism. In numerous studies, GD is an independent risk factor for post-thyroidectomy hypocalcemia and hypoparathyroidism<sup>383,976,977</sup> (see “Hyperthyroid Conditions”). In 1994, an increased rate of hypoparathyroidism was noted after thyroidectomy for large or substernal nontoxic goiter,<sup>977</sup> but more recent analyses have not shown a higher rate in these conditions.<sup>978,979</sup> A systematic review of 115 studies identified female gender and GD as the only factors predicting postthyroidectomy hypocalcemia.<sup>383</sup> Numerous studies have reported that concurrent CND for thyroid cancer is a risk factor;<sup>532,978,980,981</sup> this is believed to relate to both interruption of the blood supply and unintentional parathyroid removal (typically the lower glands). A 2017 single-institution study of CND with thyroidectomy reported a 28% rate of parathyroid removal, associated with 64% transient, and 15% permanent hypoparathyroidism rates, respectively.<sup>532</sup>

The parathyroid glands are often partially subcapsular to a thyroid lobe, or hidden within perithyroidal fat and/or lymph nodes, and can even be entirely intrathyroidal; thus unintentional parathyroidectomy during thyroidectomy is a risk factor for postoperative hypoparathyroidism, occurring in 20% of patients in a 2016 single-institution study and associated to a high (6.7%) rate of permanent hypoparathyroidism compared with 1.5% without parathyroidectomy.<sup>534</sup> Whenever possible, the surgeon should identify and preserve the parathyroid glands during thyroid operation (see “Initial Thyroidectomy”).

In general, patients with postoperative hypoparathyroidism or symptomatic hypocalcemia, whether from bone hunger or insufficient PTH, should receive calcium supplementation. The preferred initial method of administration is oral. Calcium carbonate is widely available without prescription, usually well tolerated, and a typical postoperative dose is 1–2 g, 2–3 times daily with prompt dose escalation as required for symptom relief (excess ingestion is readily excreted). For patients who have undergone prior malabsorptive weight loss surgery, have atrophic gastritis or other conditions

leading to malabsorption, or are taking a medication for chronic acid suppression, calcium citrate is the preferred alternative because of its better absorption (see “Preoperative Care”).

If significant hypocalcemia persists despite oral calcium therapy, oral calcitriol should also be initiated, at a typical dose of 0.25 to 0.5 mg twice daily, keeping in mind that its effects on calcium levels will not be apparent for at least a few days. The phosphorus level can help to distinguish between bone hunger (normal PO<sub>4</sub>) and hypoparathyroidism (elevated PO<sub>4</sub>). Magnesium and 25-OH vitamin D levels should also be checked, a 1,25-OH<sub>2</sub> vitamin D level considered, and diuretic use should be investigated as a potential confounder.

Intravenous calcium and calcitriol should be used in patients with life-threatening sequelae of hypocalcemia (cardiac arrhythmias, seizures, trismus, tetany, or laryngospasm) or severe refractory hypocalcemia despite oral calcium and calcitriol therapy.<sup>974</sup> Various regimens for intravenous correction of hypocalcemia typically use calcium gluconate in saline, administered over several hours.<sup>982</sup> The infusion rate is adjusted based on subsequent serum calcium levels. Intravenous boluses of calcium are not recommended due to their short-lived effect; infusions of calcium over several hours are more effective and preferred.

Recombinant parathyroid hormone (teriparatide) has recently been introduced as a pharmacologic method for treatment of post-thyroidectomy hypoparathyroidism refractory to oral or intravenous calcium and calcitriol therapy.<sup>983</sup> It is administered subcutaneously, typically twice a day. Teriparatide therapy is quite costly with minimal published data on its clinical use. In a 2016 pilot study of 16 patients with symptomatic hypocalcemia following thyroidectomy, teriparatide improved symptoms of hypocalcemia within 24 hours in all 8 patients who received it, allowing hospital discharge 1 day earlier.<sup>984</sup> Larger-scale studies are required and at this time, teriparatide therapy should be limited to carefully selected patients who have exhausted all other medical options.

**Recommendation 61:** *Patients with significant post-thyroidectomy hypocalcemia should receive oral calcium as first-line therapy, calcitriol as necessary, and intravenous calcium in severe or refractory situations. (Strong recommendation, low-quality evidence)*

### Rare Complications

A 2014 US NISQIP study reviewed >49,000 thyroid operations over a 7-year period and identified a 0.36% surgical site infection rate; risk factors included longer operating time (157 vs 117 min for noninfection), clean-contaminated wound, obesity, alcohol use, and dependent functional status.<sup>363</sup> In a prospective study of 6778 thyroidectomy patients operated on at a single institution over 6-year period, no antibiotic prophylaxis was administered and the incidence of postoperative infection was 0.49%.<sup>985</sup> The evidence for selected, uncommon use of antibiotic prophylaxis is covered in “Preop Care.”

Cardiopulmonary morbidity following thyroidectomy is rare. A 2017 NSQIP review of >40,000 total thyroidectomies from 2005 to 2014 reported a <1% incidence (each) for cerebrovascular accident, myocardial infarction, cardiac arrest, pulmonary embolus, pneumonia, and respiratory failure,<sup>89</sup> and an overall mortality rate of <0.1%. Appropriate preoperative medical evaluation and patient selection facilitate reduction of cardiopulmonary risk.

Aerodigestive perforation during thyroidectomy is a rare event that may occur with anesthetic manipulation, surgical technique, or tumor involvement of the trachea or esophagus (see “Imaging”).<sup>986,987</sup> Primary closure with muscle flap coverage is the recommended technique for repair. Pneumothorax following thyroidectomy is rare and typically involves LND<sup>988,989</sup> where the upper

aspects of the pleura are in close proximity to the lower cervical compartments. LND complications can also include chyle leak (see “Nodal Dissection”).

## CANCER MANAGEMENT

The initial management of TC depends in part on whether the diagnosis occurs pre- or postoperatively. Only ~50% of TC diagnoses occur by FNAB<sup>234</sup> moreover the diagnosis of FTC and HTC, in the absence of known distant metastasis, can only be determined histologically (see “Perioperative Tissue Diagnosis”). MTC can often be diagnosed on FNAB, however may also present as cytologic FN, depending on the histologic variant.<sup>221</sup> PD/ATC can be diagnosed by cytologic features but patients often have clinical characteristics which raise concern.

### Active Surveillance

Active surveillance (AS) is a possible management strategy for small PTC. The initial report of AS was from Kuma Hospital in Japan on 162 patients with PTMC (size <1 cm).<sup>990</sup> With 10-years’ follow-up, the cumulative experience for 1235 patients<sup>991</sup> reported that 8% had tumor size increase  $\geq 3$  mm, 3.8% had de novo LNM, and 16% received surgery. In a similar study from Tokyo, the cumulative data for 1465 patients with PTMC undergoing AS reported that none who required surgery for disease progression experienced recurrence or disease-specific mortality. Patients younger than 60 years were more likely to exhibit tumor growth over time.<sup>992,993</sup> Generally, tumor growth is common during AS, and in a study from South Korea by 5 years of follow-up, 36% of PTMC patients had an increase in tumor volume.<sup>994</sup>

Using AS, long-term outcomes data are available only for PTMC. In a US series of 291 patients with median short-term follow-up of 25 months, 20% had PTC 1 to 1.5 cm in size,<sup>995</sup> and the likelihood of tumor growth was independent of initial size suggesting that AS may potentially be an option even for larger tumors. Ideal candidates for observation were proposed to include older (age >60 yrs) patients with a solitary nodule surrounded by  $\geq 2$  mm of normal thyroid that is not located posteriorly near the RLN and no evidence of ETE or LNM on US.<sup>996</sup>

To date AS is not a widely adopted option. It requires informed surgical discussion, patient motivation and compliance, potentially more cost,<sup>997</sup> an experienced multidisciplinary management team, and high-quality neck US (see “Imaging”). Clinical protocols propose US every 6 months for 2 years to document nodule stability and then every 1 to 2 years with annual thyroid function testing.<sup>996</sup> Known surgical indications include tumor growth (increase  $\geq 3$  mm in any dimension has been used, but a clinically relevant threshold has not been studied), as well as LNM, or inability to continue active surveillance.

**Recommendation 62:** *An active surveillance protocol for PTMC may be appropriate for carefully selected, informed, and compliant patients. (Strong recommendation, moderate-quality evidence)*

### Postoperative Risk Assessment

In patients who are surgically treated for TC, postoperative oncologic management and communication rely on accurate prognostication using a standardized staging system. At least 18 TC prognostic staging systems have been described, and all predominantly use histologic variables to stratify risk of cancer-specific mortality. The broad utility of many systems is limited, as some were derived from PTC only (eg, MACIS and AGES) and others grouped PTC and FTC survival together in analysis (eg, AMES and GAMES).<sup>998</sup> In a comprehensive analysis of all available staging

systems applied to a single-institution cohort of PTC patients, MACIS was the most predictive of cancer-specific survival although at the time the available version of the AJCC TNM staging system was the 6th edition.<sup>998</sup>

The TNM system remains the most commonly used staging system for all thyroid cancers and is periodically updated; the 8th edition was released in October, 2016 with clinical implementation in January, 2018.<sup>999</sup> The TNM system was designed to correlate with survival thus is not as accurate in predicting recurrence. Changes in the 8th edition resulted in downstaging of most TC patients without altering stage-related mortality. For DTC, these changes included increasing the age threshold at diagnosis from 45 to 55 years before stratifying into stage III/IV disease, removing minimal ETE from the T3 definition, and decreasing the assigned stage (from III/IV–II) for tumors  $\leq 4$  cm with LNM<sup>474,999</sup> (Table 18). In new studies using the SEER and NCDB databases, the 8th edition down-staged 23% to 24% of PTC patients and improved staging discrimination for survival.<sup>1000</sup> For ATC, the 8th edition TNM system changed the definition of the T category to mirror the DTC definition, but the staging is largely unchanged.<sup>999</sup>

The TNM staging for MTC in the 8th edition is unchanged from the 7th edition. However, to improve MTC risk stratification, a recent study using population-level databases to construct a new TNM grouping proposed the inclusion in MTC stage IV of only patients with distant metastasis.<sup>1001</sup> Although histology is ultimately needed for accurate staging, the surgeon’s findings such as degree of intraoperative ETE and concern for LNM are important considerations.

**Recommendation 63:** *A validated postoperative staging system such as the AJCC TNM classification should be used in thyroid cancer care. (Strong recommendation, moderate-quality evidence)*

### Prognostic Variables

DTC is generally indolent; thus, recurrence is a more acute concern than survival. Accordingly, the ATA has a risk stratification system that was optimized for predicting recurrence and was predominantly based on histologic variables (Table 19).<sup>3,1002</sup> Under the 2009 ATA recommendation to perform TT for all DTC, the ATA Risk categories were independently validated but the literature does not yet consider application to de-escalated initial treatment such as lobectomy alone.<sup>1003,1004</sup> Although the risk of DTC recurrence varies, particularly in the low and intermediate risk categories, the majority of patients with biochemical persistence (ie, abnormal Tg level) will not develop structural disease.<sup>1003</sup>

TC subtype is also an important prognostic variable, particularly with the 2016 terminology reclassification of a subset of encapsulated FVPTC with very low risk histologic features as NIFTP (see “Perioperative Tissue Diagnosis”) (Table 13).<sup>311</sup> NIFTP diagnosis following lobectomy does not necessitate completion thyroidectomy; however, the diagnosis can be only made after histologic evaluation. Thus initial surgical management is still needed.<sup>311,1005,1006</sup> Among PTCs, there is a wide range of biologic behavior and aggressiveness (Table 13).<sup>1007–1012</sup> Poorer prognoses are seen with rare variants such as diffuse sclerosing, tall-cell, hobnail, and PDTC (including insular). FTC is subclassified by the WHO as either minimally or widely invasive (see “Perioperative Tissue Diagnosis”).<sup>1013</sup>

Nodal metastasis in FTC and HCC is rare but PTC nodal metastasis (including micrometastasis) is reported in up to 80% of patients, at rates highly reliant on detection method.<sup>483</sup> The prognostic contribution of LNM also depends on patient age, volume of nodal disease, and presence of extranodal extension (see “Nodal Dissection”).<sup>3</sup> As discussed (“Nodal Dissection”) in the 8th edition of the AJCC TNM staging system, the prognostic impact of LNM on

**TABLE 18.** AJCC TNM 8th Edition for DTC

Tumor (T) Category	Criteria
Tx	Cannot be assessed
T1	Size ≤2 cm limited to the thyroid
T1a	Size ≤1 cm limited to the thyroid
T1b	Size >1–2 cm limited to the thyroid
T2	Size >2–4 cm limited to the thyroid
T3	Size >4 cm limited to the thyroid, or tumor of any size with gross extrathyroidal extension invading only strap muscles
T3a	Size >4 cm limited to the thyroid
T3b	Tumor of any size with gross extrathyroidal extension invading only strap muscles
T4	Tumor of any size with gross extrathyroidal extension
T4a	Gross extrathyroidal extension invading subcutaneous tissues, larynx, trachea, esophagus, or RLN
T4b	Gross extrathyroidal extension invading prevertebral fascia, encasing carotid artery or mediastinal vessels
<b>Regional lymph node (N) category</b>	
Nx	Cannot be assessed
N0	No evidence of locoregional LNM
N0a	≥1 cytologically or histologically confirmed benign lymph nodes
N0b	No radiologic or clinical evidence of LNM
N1	LNM present
N1a	LNM to level VI or VII
N1b	LNM to lateral neck (levels I, II, III, IV, or V)
<b>Distant metastasis (M) category</b>	
M0	No DM
M1	DM present
<b>Staging</b>	
<b>Age &lt;55 yrs</b>	
I	T(any) N(any) M0
II	T(any) N(any) M1
<b>Age ≥55 yrs</b>	
I	T1 N0/Nx M0
II	T1/T2 N1 M0 T3 N(any) M0
III	T4a N(any) M0
IVA	T4b N(any) M0
IVB	T(any) N(any) M1

overall survival for all small (<4 cm) primary cancers has been diminished. In a statistical modeling study using NCDB TC data, the predicted number of LN required to achieve 90% confidence of having no occult central LNM was 6, 9, and 18 for patients with T1b, T2, and T3 disease respectively (by the 7th edition TNM system).<sup>453</sup>

Although these estimates are useful, the clinical consequence of having low volume LNM (≤5 involved LN, <2 mm in greatest dimension) is likely minimal as only a small proportion (<6%) will develop clinically-significant disease.<sup>3</sup> At presentation, LNM is clinically apparent in ~20% to 30% of PTC patients and is associated

**TABLE 19.** ATA Risk Stratification Definitions and Treatment

Risk Category	Characteristics	Likelihood of NED After TT and RAI Ablation, %	Minimal Extent of Thyroidectomy	RAI?	Goal TSH, mU/L
Low	Intrathyroidal, completely resected PTC or encapsulated FV-PTC No local or distant metastasis No aggressive histology (tall cell, hobnail, or columnar cell) Intrathyroidal FTC with capsular and/or <4 foci vascular invasion Clinical N0 or ≤5 pathologic N1 micrometastasis (<2 mm)	78–91	Lobectomy	Usually no	0.5–2
Intermediate	PTC with microscopic extrathyroidal extension, vascular invasion Incomplete response to treatment Clinical N1 or >5 pathologic N1 <3 cm	52–64	Total	Strongly considered esp with aggressive histologies, older age, and/or lateral LNM	0.1–0.5
High	Gross extrathyroidal extension Incomplete tumor resection Distant metastases Nodal metastasis ≥3 cm FTC with extensive vascular invasion	31–32	Total	Yes	<0.1

NED indicates no evidence of disease, for example, Tg undetectable and no radiographic evidence of disease.

with an increased risk of local recurrence of up to 30%. The recurrence risk is higher in patients with >5 LNM, and/or if extranodal extension is seen.<sup>483</sup> Volume of LN disease is incorporated into the 2015 ATA Risk stratification (Table 19) but not the AJCC TNM 8th edition (Table 18).

Specific somatic genetic mutations also modify risk. In meta-analysis, *BRAF* V600E is associated with LNM (pooled OR 1.45, 95% CI 1.24–1.69), recurrence (pooled OR 2.20, 95% CI 1.57–3.09), and overall survival (pooled OR 4.61, 95% CI 2.69–7.9).<sup>1014</sup> Risk stratification improved when *BRAF* V600E status was considered in conventional staging systems such as AMES, MACIS, TNM, and ATA Risk.<sup>1015</sup> However, it remains unclear whether *BRAF* V600E independent of histologic factors is still predictive of poor prognosis.<sup>297,1016</sup> In retrospective studies, TERT promoter mutations are an independent predictor of poor disease-related outcomes including recurrence and overall survival.<sup>300,301,304,1017,1018</sup> In a recent study that stratified DTC patients by response to therapy and TERT mutation status, prediction of mortality and recurrence was improved.<sup>302</sup> In another study, TERT mutation status improved prognostication for patients already stratified by conventional staging systems; although TERT in conjunction with *BRAF* or *RAS* had the highest risk of recurrence and disease-specific mortality, the dataset was too small to stratify further by dual mutations.<sup>1017</sup> In FTC, a higher somatic mutational burden has been associated with poor prognosis independent of histologic features.<sup>1019</sup> Tumor prognostication using miRNA has undergone preliminary investigation, but more study is needed.<sup>1020</sup>

### Completion Thyroidectomy

When DTC is confirmed or diagnosed after initial lobectomy, the first oncologic consideration is whether a completion thyroidectomy (see “Reoperation”) is needed; this decision is primarily dependent on disease stage and risk of recurrence. In DTC, current indications for completion thyroidectomy include consideration for postoperative RAI therapy or concern for multifocal disease,<sup>3</sup> but completion thyroidectomy is not necessarily indicated for all histologic DTC as lobectomy can be considered appropriate extent of surgery for low-risk tumors ≤4 cm (see “Indications, Extent, and Outcomes of Surgery”). Histologic features are often what distinguish low- from intermediate risk cancers, but this information is only available postoperatively. In recent studies examining initial lobectomy for PTC ≤4 cm, completion thyroidectomy would potentially be required for high risk features diagnosed postoperatively (eg, aggressive histology, ETE, or multiple involved lymph nodes) in 40% to 50% of patients.<sup>336,1021</sup> Improved preoperative risk stratification may eventually be achieved using US findings, patient variables, and/or tumor molecular profile (see “Molecular Testing”). Multidisciplinary communication to establish a risk-modified plan for surveillance is a key component in determining if completion thyroidectomy is needed.<sup>393</sup>

If MTC is diagnosed preoperatively, TT with central compartment ND is the minimum initial recommended procedure (see, “FNAB diagnosis,” “Indications, Extent, and Outcomes of Surgery,” “Familial TC”). However, if MTC is diagnosed postoperatively, completion thyroidectomy is recommended if multifocal or residual MTC is suspected, typically manifesting as persistent elevations in calcitonin and/or CEA levels or by imaging findings.<sup>56</sup> Hereditary MTC and a detected germline *RET* mutation should also be treated with completion thyroidectomy as the incidence of bilateral MTC is nearly 100%.<sup>56</sup>

Voice assessment should always occur prior to completion thyroidectomy, and if there is any concern for voice dysfunction a preoperative laryngeal exam should be performed (see “Laryngology”). If RLN dysfunction is present, that is, from the initial surgery,

the options include deferring completion thyroidectomy until function has returned or 2-stage ablation of the remaining lobe with RAI (below). If completion thyroidectomy is needed immediately for local control, the risk of permanent bilateral RLN injury should be specifically discussed with the patient (see “Postoperative Care and Complications”).<sup>3,95</sup>

In the absence of imaged structural disease, there is no indication for reoperative prophylactic CND for any TC histology.

**Recommendation 64: Consider completion thyroidectomy for high risk disease and/or when postoperative RAI therapy is indicated. (Strong recommendation, moderate-quality evidence)**

**Recommendation 65: Total thyroidectomy should be performed for patients undergoing prophylactic thyroidectomy for medullary thyroid cancer. (Strong recommendation, moderate-quality evidence)**

### Postoperative Treatment

When indicated, RAI ablation is administered for DTC at least 4 weeks after surgery and can be given either after T4 withdrawal or recombinant TSH administration; both management protocols function to raise TSH and increase absorption of iodine.<sup>3</sup> RAI is given for remnant ablation to facilitate surveillance (~30 mCi), as adjuvant therapy to treat microscopic disease (<150 mCi), and to treat distant metastasis if not surgically resectable and for this purpose is given either as an empiric fixed dose or by dosimetry. Indications for adjuvant RAI ablation include: DTC considered high risk or intermediate risk especially with aggressive histologies, and lateral LNM at presentation (Table 19).<sup>3,332,1022</sup> Regardless of use in staging, consideration for RAI ablation may be triggered when nonstimulated postoperative serum Tg levels are elevated postoperatively which is concerning for either persistent TC or inadequate thyroid resection (see “Initial Thyroidectomy”). Two-stage RAI administration is occasionally necessary if large volume remnant tissue requires ablation but reoperation is not possible (ie, due to contralateral RLN paralysis). Low iodine diets are encouraged before RAI ablation, and a urine iodine level may help ensure clearance of the iodine load if iodinated contrast was used for imaging within 2 to 3 months of planned treatment.

TSH receptors are expressed in DTC and when stimulated by TSH, can cause DTC growth; thus, the use of T4 to suppress TSH is a strategy routinely used to reduce the risk of DTC recurrence.<sup>3,1022</sup> Long-term TSH suppression even to subclinical levels can increase the risks of atrial fibrillation, angina, and osteoporosis.<sup>13</sup> As a result, the need for and degree of TSH suppression should follow established guidelines and be adjusted both for recurrence risk and patient comorbidities. There is no indication for TSH suppression in MTC or ATC.

If complete surgical resection for DTC was performed, there is no indication for external beam radiation therapy (EBRT) except in highly selected cases such as aerodigestive involvement; although EBRT may improve locoregional recurrence in this setting, overall survival is unchanged.<sup>1023,1024</sup> Similarly, EBRT for locally advanced MTC may reduce locoregional recurrence, although not all studies have demonstrated a benefit;<sup>1025,1026</sup> recent guidelines recommend consideration in selected high risk MTC patients with multiple cervical recurrences.<sup>56</sup> EBRT does have a role in the palliative management of ATC to improve local control and in some cases survival.<sup>54</sup> More precise radiation at potentially higher doses can be delivered by IMRT and has been utilized for thyroid cancer patients with access to specialized facilities.<sup>1027</sup> Dose-limiting and late toxicities may be lower with IMRT compared with EBRT.<sup>1028,1029</sup> The risks associated with EBRT are potentially significant. Late toxicities can include hoarseness, osteoradionecrosis, trismus, and brain/central nerve injury.



There is no role for systemic adjuvant therapy for DTC or MTC. Tyrosine kinase inhibitors and small molecule inhibitors are reserved for patients with RAI nonavid and progressive metastatic disease. Based on phase 3 trial data demonstrating superiority in prolonging progression-free survival, the FDA has approved vandetanib and cabozantinib for advanced MTC and lenvatinib and sorafenib for advanced DTC patients. In ATC, systemic chemotherapy and EBRT may improve outcomes.<sup>54</sup> Typically, paclitaxel or docetaxel (which are radiosensitizing) are combined with doxorubicin and/or cisplatin or carboplatin; data are limited to case series with some survival up to 5-years.<sup>54</sup> For BRAF V600E positive ATC, a phase 2 trial demonstrated that combination therapy with a BRAF inhibitor (dabrafenib) and a MEK inhibitor (trametinib) resulted in an overall response rate of ~69% which appeared to be durable and resulted in FDA approval for this treatment regimen.<sup>1030</sup> Early palliative care intervention improves quality of life, optimizes resource utilization and reduces costs, and is recommended.<sup>1031</sup>

With biochemical cure, MTC 10-year survival is 97.7% and the risk of recurrence is 5%.<sup>56</sup> MTC patients should have a CEA and calcitonin levels checked at least 2 to 3 months after surgery although levels may take up to 6 months to reach nadir. If levels are still detectable, surveillance includes serial tumor markers and US every 6 to 12 months. Calcitonin doubling time is independently and directly correlated to survival.<sup>106,552</sup> Rapidly increasing CEA levels may indicate MTC dedifferentiation.<sup>56</sup>

Surveillance for DTC patients should include Tg and TgAb levels and US every 6 to 12 months.<sup>3</sup> Patients with negative imaging and a suppressed Tg <0.2 ng/mL are considered to have an excellent response with a 1% to 4% risk of recurrence.<sup>3</sup> In this cohort, cervical recurrences are the most common, and routine RAI whole body scans are not needed. Detectable Tg levels are common, and when imaging is negative, ~30% will eventually have undetectable levels without intervention, and only ~20% will eventually develop imageable disease.<sup>3</sup> The highest risk of DTC relapse occurs with imaging- or clinically-evident disease after initial treatment. Despite additional treatment including resection, up to 85% of such patients will continue to have biochemical and/or imaging evidence of persistent disease, with low disease-specific survival requiring close interval follow-up.<sup>3</sup> In patients with Tg levels >10 ng/mL, CT of the chest and/or 18FDG-PET imaging can be considered (see “Imaging”). Serum Tg doubling time can be an important prognostic variable,<sup>1032,1033</sup> and in a single-institution study, Tg doubling time <1 year was associated with 50% cause specific survival at 10 years.<sup>1034</sup>

## REOPERATION

Thyroid reoperation has been variously defined to mean thyroid resection after previous thyroid surgery, or as thyroidectomy in a previously dissected cervical compartment, including after tracheostomy, parathyroidectomy, anterior cervical discectomy, or carotid endarterectomy. This document uses the latter definition.

Although most patients undergoing thyroidectomy will require only an initial operation for definitive treatment, reoperation may be needed in 3 categories: central or lateral resection of persistent/recurrent TC or LNM, resection of remnant ipsilateral thyroid tissue resection after prior partial thyroidectomy, and completion total thyroidectomy after previous contralateral lobectomy.

## Indications

A common indication for thyroid reoperation is persistent or recurrent TC. Approximately 30% of patients with DTC will have persistent or recurrent anatomically structural LNM, 66% within 10 years of initial surgery<sup>1035</sup> (see “Nodal Dissection”). A less common manifestation (<5% of DTC cases in a 2017 series)<sup>1036</sup> is persistent or recurrent TC in remnant thyroid tissue, typically near the tubercle of Zuckerkandl in the previous resection bed. When evaluating a patient with persistent or recurrent TC, it is important to differentiate between nodal versus remnant thyroid tissue recurrence by careful review of imaging studies and FNAB results, as this may impact decision-making and planning for surgical intervention.

When persistent or recurrent TC is identified, decision-making regarding observation versus reoperation or other therapy, requires specific evaluation, risk-stratification and patient counseling (Table 20). Many subclinical, radiographically detected LNM or thyroid bed nodules will not exhibit growth or aggressive behavior during long-term observation. As 2011 study of 191 patients with US-identified central compartment nodules or LN after initial thyroidectomy reported stable disease in 91%; in the 9% with progression, growth occurred slowly (mean 1.3 mm/yr) with no observed adverse outcomes such as local invasion or distant spread.<sup>1037</sup> A similar 2012 study evaluated 166 patients with suspicious lateral compartment LN after initial thyroidectomy for DTC; during a mean 3.5-year follow-up period, 29% had interval progression (20% had LNM growth of ≥3 mm, 9% of ≥5 mm), with no adverse outcomes.<sup>511</sup> Two 2015 reports concluded that DTC patients with radiographically-detected recurrent LNM may be candidates for observation for a central compartment LN ≤8 mm or lateral compartment node ≤10 mm and minimal (<3–5 mm/yr) or no growth on serial imaging.<sup>3,1038</sup> In addition, patients with a strong preference to avoid further operation, significant comorbidities, or progressive systemic disease also may be selected for observation.

In addition to LN size, an additional criterion for determining need for reoperation is the trend of serial serum Tg levels. In a 2011 study Tg doubling time was a strong prognostic indicator in DTC,<sup>1036</sup> suggesting that progressive increase in Tg level is an indication for reoperation for clinically or radiologically apparent disease.

**Recommendation 66:** *Selected patients with stable, low-volume persistent or recurrent LNM can undergo active surveillance. (Weak recommendation, low-quality evidence)*

The management of persistent or recurrent MTC follows many of the same principles as for DTC, although patients with MTC are

**TABLE 20.** Criteria for Patient Selection for Active Surveillance Versus Reoperation for Persistent or Recurrent Nodal Metastases of DTC

Active Surveillance	Reoperation
Central neck node ≤8 mm	Central neck node >8 mm
Lateral neck node ≤10 mm	Lateral neck node >10 mm
No/minimal nodal growth on serial imaging	Nodal growth of >3–5 mm/yr on serial imaging
Thyroglobulin levels stable	Thyroglobulin levels increasing
Patient/endocrinologist preference for continued observation	Patient/endocrinologist preference for reoperation
Significant comorbidities	Able to tolerate reoperation

not candidates for RAI therapy. Nodal recurrence of MTC requiring reoperation occurs in 12% to 27% of patients.<sup>1039–1041</sup> Serial cervical imaging and measurements of calcitonin and CEA allow the clinician to track disease progression and recurrence (see “Cancer Management”). Calcitonin and CEA doubling times strongly correlate with MTC disease progression and clinical outcomes<sup>1042,1043</sup> suggesting that patients with radiographically detectable MTC LNM and progressive rise in calcitonin or CEA levels should be considered for reoperation.

Although typically undesirable (see “Initial Thyroidectomy”), partial initial thyroidectomy may occur unilaterally or bilaterally in management of TC, requiring later remnant resection of tissue left in situ (ie, at the superior pole, isthmus, pyramidal lobe, or even subinternally). Patients without a history of TC may also require reoperation after partial thyroidectomy.<sup>1044</sup> Inadequate preoperative imaging may be a root cause of incomplete initial thyroidectomy. In reoperation, review of the previous operative and pathology reports is key to understanding the extent of prior dissection and resection.

Contralateral thyroid reoperation may be required after initial diagnostic lobectomy with a final histopathologic diagnosis of clinically significant TC. Completion thyroidectomy (removal of the contralateral lobe) is recommended for patients with TC exhibiting intermediate to high-risk pathologic features, especially if RAI ablation is planned (see “Cancer Management”). If VFD is present or the RLN was transected due to tumor involvement, the patient and surgeon should have a detailed discussion regarding the risks and benefits of completion thyroidectomy versus other options such as 2 stage RAI ablation or observation (see “Cancer Management”). No prospective data exist regarding the optimal timing of completion thyroidectomy, and there is considerable variability in the recommended interval. We suggest that, if possible, it is best either to return to the operating room within 1 to 2 weeks of initial surgery, or to wait until considerably more time has passed (typically 8 to 12 wks) due to the likelihood of encountering significant inflammation during the interim period of healing.

### Preoperative Management

In thyroid reoperation, one of the first priorities is to obtain all possible documentation from the patient’s prior operation(s). The operative and pathology reports can detail the extent of previous dissection, the structures identified and/or removed, the gross extent of disease, and any injuries or complications that may have been recognized. The actual pathology specimens and slides should be requested for review, as there are often discrepancies in diagnosis or staging on repeat evaluation by a pathologist with endocrine expertise.<sup>1045</sup> Other key data include radiology reports, images, perioperative clinic records, and FNAB results for LN or suspicious remnant tissue.

Current imaging is another critical component of assessment, helping the surgeon to form a clear picture of the planned reoperative field, the target(s) of resection, and adjacent vital structures. High-resolution US is the most commonly utilized study and can be performed during office evaluation, immediately preceding reoperation, and/or in the operating room.<sup>1046,1047</sup> CT with intravenous contrast can provide detailed cross-sectional images of the relationships of enlarged LNs and soft tissue disease to adjacent structures and major blood vessels.<sup>1048</sup> MRI is an alternative to CT but it is more costly and its accuracy varies depending on institutional expertise (see “Imaging”).<sup>1049</sup>

PET-CT is not often required, but in the setting of elevated Tg levels may be of value in patients with DTC that is refractory to RAI. In addition, patients with higher-risk TC subtypes (such as tall cell variant or PDTC) may be candidates for PET-CT prior to

reoperation,<sup>1050</sup> which not only highlights cervical disease, but may also identify other sites of distant metastasis, possibly altering treatment. RAI scanning may be useful in identifying foci of persistent or recurrent TC (see “Cancer Management”), but the resolution of this modality is not high enough to allow for its use as a stand-alone study for preoperative planning.

Prior to any thyroid reoperation, a TSH level should be evaluated, current medications should be reviewed, and a serum calcium level should also be checked, as parathyroid glands may have been injured or removed during the previous operation. The prior operative report and pathology report should be reviewed to confirm if any parathyroids were removed previously.

In patients with DTC who have undergone prior total thyroidectomy, a Tg level with anti-Tg antibodies is also advised. Similarly, patients with MTC who are planned for reoperation should undergo preoperative calcitonin and CEA measurements, and also should be screened for pheochromocytoma and hyperparathyroidism as appropriate (see “Familial TC”).

In elective thyroid reoperation, at minimum a preoperative voice assessment should occur, and if there is concern for voice dysfunction, formal laryngeal evaluation should be performed to evaluate vocal fold mobility (see “Laryngology”).<sup>800</sup> This also applies to any patient with prior cervical or thoracic surgery associated with risk for RLN injury.

### Risks

Due to scarring and altered anatomy, the risks of thyroid reoperation are higher than for initial surgery. A 2007 study of 685 reoperations for both benign and malignant thyroid disease reported significantly higher permanent complication rates (2.5% permanent hypocalcemia, 1.5% permanent VFD) compared with initial thyroidectomy.<sup>1051</sup> Reoperation specifically for TC confers even higher risks;<sup>1052–1056</sup> a 2009 review reported 9.5% permanent hypoparathyroidism and 6.4% permanent VFD, with both rates significantly higher than for initial thyroidectomy.<sup>1054</sup> The parathyroid glands are at especially high risk in reoperation; a 2010 study reported a 31% rate of inadvertent partial or complete parathyroid resection on histology.<sup>1057</sup> Reoperation is also more technically challenging.<sup>514,1058,1059</sup>

### Operative Approach

When possible, the prior cervical incision should be utilized, although this may not be technically feasible if the target of reoperation is located several cm away. In selected patients, to avoid dissection through scar (especially overlying the trachea in the midline), it may be useful in deeper layers to take a lateral approach to either the central or lateral compartments by entering the space between the SCM and the lateral edge of the strap muscles, with lateral retraction of the carotid sheath structures. During reoperation in the central compartment, scarring may impede identification of the aerodigestive structures and initial placement of a nasogastric/orogastric tube or esophageal temperature probe can facilitate palpation of the esophagus. The extent of encountered scar tissue should be noted and when possible, described in the operative report.

The extent of reoperative LN resection is determined by the degree of scar tissue; as with first-time operations, compartment-based node dissection is the optimal goal but may not be possible due to altered anatomy. For lateral LNM, if the previous operation did not involve the lateral neck then a compartment-based dissection should be performed; otherwise, a more focused resection of only the involved nodes may be needed to avoid injury to surrounding structures.<sup>1060</sup>

Although uncommon, there still exist situations today where a surgeon embarks upon a planned thyroid operation but ends up

removing little or no thyroid tissue, because of inability to find the gland, inexperience, or unexpected intraoperative findings such as severe inflammation or tumor invasion.<sup>1060–1062</sup> These outcomes should be avoided as they do not benefit the patient, carry risk, and create scarring that will make future thyroid operation more difficult with greater risk.

One of the primary challenges of reoperation is identifying and preventing injury to the RLN and in the reoperative setting, RLNM may aid in mapping and/or confirmation of a visually identified RLN.<sup>1063,1064</sup> A 2014 study of 854 patients undergoing thyroid reoperation demonstrated a significant decrease in paresis and a trend towards a decrease in permanent VFD using RLNM versus visual identification alone.<sup>1065</sup> A 2017 systematic review of RLNM during high-risk thyroidectomy (including reoperation) reported a trend towards decreased rates of temporary and permanent RLN injury (see “Adjuncts and Approaches”).<sup>743</sup>

Perioperative diagnostic evaluation of the reoperative patient often requires specialized radiologic and endocrine pathology expertise. Moreover, decision-making about optimal management of persistent or recurrent disease often requires the input not only of the thyroid surgeon and endocrinologist, but also of nuclear medicine, radiation oncology and medical oncology team members in a multidisciplinary setting.

## CONCLUDING REMARKS

*“In the ever-renewing society, what matures is a system or framework within which continuous innovation, renewal, and rebirth can occur.”<sup>1066</sup>*

Evolving over more than a century, thyroidectomy today is typically a definitive and often curative procedure with a low risk of morbidity. Medical and technological advances have required the creation of evidence-based guidelines to define practice, personalize care, stratify risk, reduce health care costs, improve outcomes, and identify rational challenges for future efforts. In the future, this work will certainly and rightly need to be done again. The current document is based on the existing published evidence and was informed by the clinical experience of 19 experts in thyroidology. The target audience is the practicing surgeon in a community hospital, academic center, or training program. Throughout the writing process, the authors’ intent was to advise surgeons about *the right thing to do for the patient*. We also learned a great deal from each other. In humility and conscientious humanism, we are proud to offer this consensus document to readers.

## ACKNOWLEDGMENTS

*The authors are indebted to Ms Lauren Santangelo at AMR Management Services, and to Ms Carol Bykowski for administrative help. The authors also thank Dr Kia Nicholson for expert assistance in preparing Figure 2, and Dr Richard L. Simmons for advice. The authors are grateful to AAES leadership for commissioning this work.*

## REFERENCES

- Sun GH, DeMonner S, Davis MM. Epidemiological and economic trends in inpatient and outpatient thyroidectomy in the United States, 1996–2006. *Thyroid*. 2013;23:727–733.
- Rubio GA, Koru-Sengal T, Vaghaiwalla TM, Parikh PP, Farra JC, Lew JJ. Postoperative outcomes in Graves’ disease patients: results from the nationwide inpatient sample database. *Thyroid*. 2017;27:825–831.
- Haugen BRM, Alexander EK, Bible KC, et al. 2015 American Thyroid Association Management Guidelines for adult patients with thyroid nodules and differentiated thyroid cancer. *Thyroid*. 2016;26:1–133.
- Gharib H, Papini E, Paschke R, et al. American Association of Clinical Endocrinologists, Associazione Medici Endocrinologi, and European Thyroid Association Medical guidelines for clinical practice for the diagnosis

and management of thyroid nodules: executive summary of recommendations. *J Endocrinol Invest*. 2010;33(5 suppl):51–56.

- Gharib H, Zeiger MA, Zini M, et al. AAACE/AME Task Force on Thyroid Nodules. American Association of Clinical Endocrinologists and Associazione Medici Endocrinologi medical guidelines for clinical practice for the diagnosis and management of thyroid nodules. *Endocr Pract*. 2006;12:63–102.
- Wilhelm SM, Wang TS, Ruan DT, et al. The American Association of Endocrine Surgeons Guidelines for definitive management of primary hyperparathyroidism. *JAMA Surg*. 2016;151:959–968.
- Sawka AM, Carty SE, Haugen BR, et al. American Thyroid Association Guidelines and Statements: past, present, and future. *Thyroid*. 2018;28:692–706.
- Qaseem A, Snow V, Owens DK, et al. The development of clinical practice guidelines and guidance statements of the American College of Physicians: summary of methods. *Ann Intern Med*. 2010;153:194–199.
- Lewis MH, Gohagan JK, Merenstein DJ. The locality rule and the physician’s dilemma: local medical practices vs the national standard of care. *JAMA*. 2007;297:2633–2637.
- De Leo S, Lee SY, Braverman LE. Hyperthyroidism. *Lancet*. 2016;388:906–918.
- Chaker L, Bianco AC, Jonklaas J, et al. Hypothyroidism. *Lancet*. 2017;390:1550–1562.
- Porterfield JR Jr, Thompson GB, Farley DR, et al. Evidence-based management of toxic multinodular goiter (Plummer’s Disease). *World J Surg*. 2008;32:1278–1284.
- Ross DS, Burch HB, Cooper DS, et al. 2016 American Thyroid Association Guidelines for diagnosis and management of hyperthyroidism and other causes of thyrotoxicosis. *Thyroid*. 2016;26:1343–1421.
- Smith TJ, Hegedus L. Graves’ disease. *N Engl J Med*. 2017;376:185.
- Berghout A, Wiersinga WM, Smits NJ, et al. Interrelationships between age, thyroid volume, thyroid nodularity, and thyroid function in patients with sporadic nontoxic goiter. *Am J Med*. 1990;89:602–608.
- Parma J, Duprez L, Van Sande J, et al. Somatic mutations in the thyrotropin receptor gene cause hyperfunctioning thyroid adenomas. *Nature*. 1993;365:649–651.
- Burch HB, Burman KD, Cooper DS. A 2011 survey of clinical practice patterns in the management of Graves’ disease. *J Clin Endocrinol Metab*. 2012;97:4549–4558.
- Hollowell JG, Staehling NW, Flanders WD, et al. Serum TSH, T(4), and thyroid antibodies in the United States population (1988 to 1994): National Health and Nutrition Examination Survey (NHANES III). *J Clin Endocrinol Metab*. 2002;87:489–499.
- Dahlgren M, Khosroshahi A, Nielsen GP, et al. Riedel’s thyroiditis and multifocal fibrosclerosis are part of the IgG4-related systemic disease spectrum. *Arthritis Care Res (Hoboken)*. 2010;62:1312–1318.
- Kakudo K, Li Y, Hirokawa M, et al. Diagnosis of Hashimoto’s thyroiditis and IgG4-related sclerosing disease. *Pathol Int*. 2011;61:175–183.
- Li Y, Bai Y, Liu Z, et al. Immunohistochemistry of IgG4 can help subclassify Hashimoto’s autoimmune thyroiditis. *Pathol Int*. 2009;59:636–641.
- Stan MN, Sonawane V, Sebo TJ, et al. Riedel’s thyroiditis association with IgG4-related disease. *Clin Endocrinol (Oxf)*. 2017;86:425–430.
- Lai X, Xia Y, Zhang B, et al. A meta-analysis of Hashimoto’s thyroiditis and papillary thyroid carcinoma risk. *Oncotarget*. 2017;8:62414–62424.
- Wormer BA, McHenry CR. Hashimoto’s thyroiditis: outcome of surgical resection for patients with thyromegaly and compressive symptoms. *Am J Surg*. 2011;201:416–419.
- Reiners C, Wegscheider K, Schicha H, et al. Prevalence of thyroid disorders in the working population of Germany: ultrasonography screening in 96,278 unselected employees. *Thyroid*. 2004;14:926–932.
- Kamran SC, Marqusee E, Kim MI, et al. Thyroid nodule size and prediction of cancer. *J Clin Endocrinol Metab*. 2013;98:564–570.
- Cavallo A, Johnson DN, White MG, et al. Thyroid nodule size at ultrasound as a predictor of malignancy and final pathologic size. *Thyroid*. 2017;27:641–650.
- Hammad AY, Noureldine SI, Hu T, et al. A meta-analysis examining the independent association between thyroid nodule size and malignancy. *Gland Surg*. 2016;5:312–317.
- McHenry CR, Huh ES, Machekano RN. Is nodule size an independent predictor of thyroid malignancy? *Surgery*. 2008;144:1062–1068.
- Noureldine SI, Tufano RP. Association of Hashimoto’s thyroiditis and thyroid cancer. *Curr Opin Oncol*. 2015;27:21–25.

31. Shin JJ, Caragacianu D, Randolph GW. Impact of thyroid nodule size on prevalence and post-test probability of malignancy: a systematic review. *Laryngoscope*. 2015;125:263–272.
32. Shrestha M, Crothers BA, Burch HB. The impact of thyroid nodule size on the risk of malignancy and accuracy of fine-needle aspiration: a 10-year study from a single institution. *Thyroid*. 2012;22:1251–1256.
33. Sippel RS, Elaraj DM, Khanafshar E, et al. Tumor size predicts malignant potential in Hurthle cell neoplasms of the thyroid. *World J Surg*. 2008;32:702–707.
34. Cibas ES, Ali SZ. The Bethesda system for reporting thyroid cytopathology. *Thyroid*. 2009;19:1159–1165.
35. Mai KT, Landry DC, Thomas J, et al. Follicular adenoma with papillary architecture: a lesion mimicking papillary thyroid carcinoma. *Histopathology*. 2001;39:25–32.
36. Shi H, Bobanga I, McHenry CR. Are large thyroid nodules classified as benign on fine needle aspiration more likely to harbor cancer? *Am J Surg*. 2017;213:464–466.
37. Tzen CY, Huang YW, Fu YS. Is atypical follicular adenoma of the thyroid a preinvasive malignancy? *Hum Pathol*. 2003;34:666–669.
38. Lloyd RV, Osamura RY, Klöppel G, Rosai J, eds. *WHO Classification of Tumours of Endocrine Organs* (IARC WHO Classification of Tumours). 4th ed. Lyon, France: IARC; 2017.
39. Asa SL, Giordano TJ, LiVolsi VA. Implications of the TCGA genomic characterization of papillary thyroid carcinoma for thyroid pathology: does follicular variant papillary thyroid carcinoma exist? *Thyroid*. 2015;25:1–2.
40. Davies L, Welch HG. Increasing incidence of thyroid cancer in the United States, 1973–2002. *JAMA*. 2006;295:2164–2167.
41. Davies L, Welch HG. Current thyroid cancer trends in the United States. *JAMA Otolaryngol Head Neck Surg*. 2014;140:317–322.
42. Chen AY, Jemal A, Ward EM. Increasing incidence of differentiated thyroid cancer in the United States, 1988–2005. *Cancer*. 2009;115:3801–3807.
43. Lin JS, Bowles EJA, Williams SB, et al. Screening for thyroid cancer: updated evidence report and systematic review for the US Preventive Services Task Force. *JAMA*. 2017;317:1888–1903.
44. Lim H, Devesa SS, Sosa JA, et al. Trends in thyroid cancer incidence and mortality in the United States, 1974–2013. *JAMA*. 2017;317:1338–1348.
45. Dionigi G, Kraimps JL, Schmid KW, et al. Minimally invasive follicular thyroid cancer (MIFTC): a consensus report of the European Society of Endocrine Surgeons (ESES). *Langenbecks Arch Surg*. 2014;399:165–184.
46. Chindris AM, Casler JD, Bernet VJ, et al. Clinical and molecular features of Hurthle cell carcinoma of the thyroid. *J Clin Endocrinol Metab*. 2015;100:55–62.
47. Ganly I, Makarov V, Deraje S, et al. Integrated genomic analysis of hurthle cell cancer reveals oncogenic drivers, recurrent mitochondrial mutations, and unique chromosomal landscapes. *Cancer Cell*. 2018;34:256–270.
48. Gopal RK, Kübler K, Calvo SE, et al. Widespread chromosomal losses and mitochondrial DNA alterations as genetic drivers in hurthle cell carcinoma. *Cancer Cell*. 2018;34:242–255.
49. Volante M, Landolfi S, Chiusa L, et al. Poorly differentiated carcinomas of the thyroid with trabecular, insular, and solid patterns: a clinicopathologic study of 183 patients. *Cancer*. 2004;100:950–957.
50. Volante M, Papotti M. Poorly differentiated thyroid carcinoma: 5 years after the 2004 WHO classification of endocrine tumours. *Endocr Pathol*. 2010;21:1–6.
51. Volante M, Collini P, Nikiforov YE, et al. Poorly differentiated thyroid carcinoma: the Turin proposal for the use of uniform diagnostic criteria and an algorithmic diagnostic approach. *Am J Surg Pathol*. 2007;31:1256–1264.
52. Hunt JL, Tometsko M, LiVolsi VA, et al. Molecular evidence of anaplastic transformation in coexisting well-differentiated and anaplastic carcinomas of the thyroid. *Am J Surg Pathol*. 2003;27:1559–1564.
53. Xu B, Ghossein R. Genomic landscape of poorly differentiated and anaplastic thyroid carcinoma. *Endocr Pathol*. 2016;27:205–212.
54. Smallridge RC, Ain KB, Asa SL, et al. American Thyroid Association guidelines for management of patients with anaplastic thyroid cancer. *Thyroid*. 2012;22:1104–1139.
55. Landa I, Ibrahimipasic T, Boucai L, et al. Genomic and transcriptomic hallmarks of poorly differentiated and anaplastic thyroid cancers. *J Clin Invest*. 2016;126:1052–1066.
56. Wells SA Jr, Asa SL, Dralle H, et al. Revised American Thyroid Association guidelines for the management of medullary thyroid carcinoma. *Thyroid*. 2015;25:567–610.
57. Baloch ZW, LiVolsi VA. C-cells and their associated lesions and conditions: a pathologists perspective. *Turk Patoloji Derg*. 2015;31(suppl 1):60–79.
58. Sharma A, Jasim S, Reading CC, et al. Clinical presentation and diagnostic challenges of thyroid lymphoma: a cohort study. *Thyroid*. 2016;26:1061–1067.
59. Holm LE, Blomgren H, Lowhagen T. Cancer risks in patients with chronic lymphocytic thyroiditis. *N Engl J Med*. 1985;312:601–604.
60. Rossi D. Thyroid lymphoma: beyond antigen stimulation. *Leuk Res*. 2009;33:607–609.
61. Matsuzuka F, Miyauchi A, Katayama S, et al. Clinical aspects of primary thyroid lymphoma: diagnosis and treatment based on our experience of 119 cases. *Thyroid*. 1993;3:93–99.
62. Schneider AB, Ron E, Lubin J, et al. Dose-response relationships for radiation-induced thyroid cancer and thyroid nodules: evidence for the prolonged effects of radiation on the thyroid. *J Clin Endocrinol Metab*. 1993;77:362–369.
63. Ron E. Cancer risks from medical radiation. *Health Phys*. 2003;85:47–59.
64. Iglesias ML, Schmidt A, Ghuzlan AA, et al. Radiation exposure and thyroid cancer: a review. *Arch Endocrinol Metab*. 2017;61:180–187.
65. Nikiforov YE. Radiation-induced thyroid cancer: what we have learned from Chernobyl. *Endocr Pathol*. 2006;17:307–317.
66. Tronko MD, Howe GR, Bogdanova TI, et al. A cohort study of thyroid cancer and other thyroid diseases after the chornobyl accident: thyroid cancer in Ukraine detected during first screening. *J Natl Cancer Inst*. 2006;98:897–903.
67. Ohira T, Takahashi H, Yasumura S, et al. Comparison of childhood thyroid cancer prevalence among 3 areas based on external radiation dose after the Fukushima Daiichi nuclear power plant accident: The Fukushima health management survey. *Medicine (Baltimore)*. 2016;95:e4472.
68. Ohira T, Takahashi H, Yasumura S, et al. Associations between childhood thyroid cancer and external radiation dose after the Fukushima Daiichi Nuclear Power Plant Accident. *Epidemiology*. 2018;29:e32–e34.
69. Levin RJ, De Simone NF, Slotkin JF, et al. Incidence of thyroid cancer surrounding Three Mile Island nuclear facility: the 30-year follow-up. *Laryngoscope*. 2013;123:2064–2071.
70. Sinnott B, Ron E, Schneider AB. Exposing the thyroid to radiation: a review of its current extent, risks, and implications. *Endocr Rev*. 2010;31:756–773.
71. de Vathaire F, Haddy N, Allodji RS, et al. Thyroid radiation dose and other risk factors of thyroid carcinoma following childhood cancer. *J Clin Endocrinol Metab*. 2015;100:4282–4290.
72. Bhatti P, Veiga LH, Ronckers CM, et al. Risk of second primary thyroid cancer after radiotherapy for a childhood cancer in a large cohort study: an update from the childhood cancer survivor study. *Radiat Res*. 2010;174:741–752.
73. Veiga LH, Holmberg E, Anderson H, et al. Thyroid cancer after childhood exposure to external radiation: an updated pooled analysis of 12 studies. *Radiat Res*. 2016;185:473–484.
74. Grantzau T, Overgaard J. Risk of second non-breast cancer among patients treated with and without postoperative radiotherapy for primary breast cancer: a systematic review and meta-analysis of population-based studies including 522,739 patients. *Radiother Oncol*. 2016;121:402–413.
75. Metzger R, Milas M. Inherited cancer syndromes and the thyroid: an update. *Curr Opin Oncol*. 2014;26:51–61.
76. Milas M, Mester J, Metzger R, et al. Should patients with Cowden syndrome undergo prophylactic thyroidectomy? *Surgery*. 2012;152:1201–1210.
77. Brauckhoff M, Machens A, Lorenz K, et al. Surgical curability of medullary thyroid cancer in multiple endocrine neoplasia 2B: a changing perspective. *Ann Surg*. 2014;259:800–806.
78. Straccia P, Mosseri C, Brunelli C, et al. Diagnosis and treatment of metastases to the thyroid gland: a meta-analysis. *Endocr Pathol*. 2017;28:112–120.
79. Romero Arenas MA, Ryu H, Lee S, et al. The role of thyroidectomy in metastatic disease to the thyroid gland. *Ann Surg Oncol*. 2014;21:434–439.
80. Chen AY, Bernet VJ, Carty SE, et al. American Thyroid Association statement on optimal surgical management of goiter. *Thyroid*. 2014;24:181–189.
81. Vansant MB, Kunduk M, McWhorter AJ. A review of postsurgical dysphagia in nonmalignant disease. *Curr Opin Otolaryngol Head Neck Surg*. 2016;24:477–482.
82. Holler T, Anderson J. Prevalence of voice & swallowing complaints in Pre-operative thyroidectomy patients: a prospective cohort study. *J Otolaryngol Head Neck Surg*. 2014;43:28.

83. Greenblatt DY, Sippel R, Levenson G, et al. Thyroid resection improves perception of swallowing function in patients with thyroid disease. *World J Surg.* 2009;33:255–260.
84. Burns P, Timon C. Thyroid pathology and the globus symptom: are they related? A two year prospective trial. *J Laryngol Otol.* 2007;121:242–245.
85. Nam IC, Choi H, Kim ES, et al. Characteristics of thyroid nodules causing globus symptoms. *Eur Arch Otorhinolaryngol.* 2015;272:1181–1188.
86. Shen WT, Kebebew E, Duh QY, et al. Predictors of airway complications after thyroidectomy for substernal goiter. *Arch Surg.* 2004;139:656–659.
87. Stang MT, Armstrong MJ, Ogilvie JB, et al. Positional dyspnea and tracheal compression as indications for goiter resection. *Arch Surg.* 2012;147:621–626.
88. Jonklaas J, Bianco AC, Bauer AJ, et al. Guidelines for the treatment of hypothyroidism: prepared by the american thyroid association task force on thyroid hormone replacement. *Thyroid.* 2014;24:1670–1751.
89. Caulley L, Johnson-Obaseki S, Luo L, Javidnia H. Risk factors for postoperative complications in total thyroidectomy: a retrospective, risk-adjusted analysis from the National Surgical Quality Improvement Program. *Medicine (Baltimore).* 2017;96:e5752.
90. Abraham CR, Ata A, Carsello CB, Chan TL, Stain SC, Beyer TD. A NSQIP risk assessment for thyroid surgery based on comorbidities. *J Am Coll Surg.* 2014;218:1231–1237.
91. Schmid D, Ricci C, Behrens G, Leitzmann MF. Adiposity and risk of thyroid cancer: a systematic review and meta-analysis. *Obes Rev.* 2015;16:1042–1054.
92. Kitahara CM, McCullough ML, Franceschi S, et al. Anthropometric factors and thyroid cancer risk by histological subtype: pooled analysis of 22 prospective studies. *Thyroid.* 2016;26:306–318.
93. Tan GH, Gharib H, Reading CC. Solitary thyroid nodule. Comparison between palpation and ultrasonography. *Arch Intern Med.* 1995;155:2418–2423.
94. De Filippis EA, Sabet A, Sun MR, Garber JR. Pemberton's sign: explained nearly 70 years later. *J Clin Endocrinol Metab.* 2014;99:1949–1954.
95. Chandrasekhar SS, Randolph GW, Seidman MD, et al. Clinical practice guideline: improving voice outcomes after thyroid surgery. *Otolaryngol Head Neck Surg.* 2013;148(6 suppl):S1–S37.
96. Zanocco K, Kaltman DJ, Wu JX, et al. Cost effectiveness of routine laryngoscopy in the surgical treatment of differentiated thyroid cancer. *Ann Surg Oncol.* 2018;25:949–956.
97. Choong KC, McHenry CR. Thyroid cancer in patients with toxic nodular goiter: is the incidence increasing? *Am J Surg.* 2015;209:974–976.
98. Smith JJ, Chen X, Schneider DF, et al. Toxic nodular goiter and cancer: a compelling case for thyroidectomy. *Ann Surg Oncol.* 2013;20:1336–1340.
99. Morita SY, Somervell H, Umbricht CB, et al. Evaluation for concomitant thyroid nodules and primary hyperparathyroidism in patients undergoing parathyroidectomy or thyroidectomy. *Surgery.* 2008;144:862–866.
100. Murray SE, Sippel RS, Chen H. Incidence of concomitant hyperparathyroidism in patients with thyroid disease requiring surgery. *J Surg Res.* 2012;178:264–267.
101. Jovanovic MD, Zivaljevic VR, Diklic AD, Rovcanin BR, V Zoric G, Paunovic IR. Surgical treatment of concomitant thyroid and parathyroid disorders: analysis of 4882 cases. *Eur Arch Otorhinolaryngol.* 2017;274:997–1004.
102. Prinz RA, Paloyan E, Lawrence AM, Barbato AL, Braithwaite SS, Brooks MH. Unexpected parathyroid disease discovered at thyroidectomy in irradiated patients. *Am J Surg.* 1981;142:355–357.
103. Elisei R, Bottici V, Luchetti F, et al. Impact of routine measurement of serum calcitonin on the diagnosis and outcome of medullary thyroid cancer: experience in 10,864 patients with nodular thyroid disorders. *J Clin Endocrinol Metab.* 2004;89:163–168.
104. Costante G, Durante C, Francis Z, et al. Determination of calcitonin levels in C-cell disease: clinical interest and potential pitfalls. *Nat Clin Pract Endocrinol Metab.* 2009;5:35–44.
105. Network, N.C.C. Thyroid Carcinoma (Version 2.2015). [http://www.nccn.org/professionals/physician\\_gls/pdf/thyroid.pdf](http://www.nccn.org/professionals/physician_gls/pdf/thyroid.pdf). Accessed July 19, 2019
106. Machens A, Dralle H. Biomarker-based risk stratification for previously untreated medullary thyroid cancer. *J Clin Endocrinol Metab.* 2010;95:2655–2663.
107. Machens A, Schneyer U, Holzhausen HJ, et al. Prospects of remission in medullary thyroid carcinoma according to basal calcitonin level. *J Clin Endocrinol Metab.* 2005;90:2029–2034.
108. Yeh MW, Bauer AJ, Bernet VA, et al. American Thyroid Association statement on preoperative imaging for thyroid cancer surgery. *Thyroid.* 2015;25:3–14.
109. Kouvaraki MA, Shapiro SE, Fornage BD, et al. Role of preoperative ultrasonography in the surgical management of patients with thyroid cancer. *Surgery.* 2003;134:946–954.
110. Kwak JY. Thyroid ultrasonography for personalized approach at thyroid nodules. *Endocrine.* 2016;52:181–182.
111. Kwak JY, Han KH, Yoon JH, et al. Thyroid imaging reporting and data system for US features of nodules: a step in establishing better stratification of cancer risk. *Radiology.* 2011;260:892–899.
112. Moon HG, Jung EJ, Park ST, et al. Role of ultrasonography in predicting malignancy in patients with thyroid nodules. *World J Surg.* 2007;31:1410–1416.
113. Moon HJ, Kim EK, Kwak JY. Malignancy risk stratification in thyroid nodules with benign results on cytology: combination of thyroid imaging reporting and data system and Bethesda system. *Ann Surg Oncol.* 2014;21:1898–1903.
114. Salmasliloglu A, Erbil Y, Dural C, et al. Predictive value of sonographic features in preoperative evaluation of malignant thyroid nodules in a multinodular goiter. *World J Surg.* 2008;32:1948–1954.
115. Moon HJ, Kwak JY, Kim MJ, et al. Can vascularity at power Doppler US help predict thyroid malignancy? *Radiology.* 2010;255:260–269.
116. Papini E, Guglielmi R, Bianchini A, et al. Risk of malignancy in non-palpable thyroid nodules: predictive value of ultrasound and color-Doppler features. *J Clin Endocrinol Metab.* 2002;87:1941–1946.
117. Gul K, Ersoy R, Dirikoc A, et al. Ultrasonographic evaluation of thyroid nodules: comparison of ultrasonographic, cytological, and histopathological findings. *Endocrine.* 2009;36:464–472.
118. Cappelli C, Pirola I, Cumetti D, et al. Is the anteroposterior and transverse diameter ratio of nonpalpable thyroid nodules a sonographic criteria for recommending fine-needle aspiration cytology? *Clin Endocrinol (Oxf).* 2005;63:689–693.
119. Tang AL, Falciglia M, Yang H, et al. Validation of American Thyroid Association ultrasound risk assessment of thyroid nodules selected for ultrasound fine-needle aspiration. *Thyroid.* 2017;27:1077–1082.
120. Horvath E, Majlis S, Rossi R, et al. An ultrasonogram reporting system for thyroid nodules stratifying cancer risk for clinical management. *J Clin Endocrinol Metab.* 2009;94:1748–1751.
121. Tae HJ, Lim DJ, Baek KH, et al. Diagnostic value of ultrasonography to distinguish between benign and malignant lesions in the management of thyroid nodules. *Thyroid.* 2007;17:461–466.
122. Ito Y, Amino N, Yokozawa T, et al. Ultrasonographic evaluation of thyroid nodules in 900 patients: comparison among ultrasonographic, cytological, and histological findings. *Thyroid.* 2007;17:1269–1276.
123. Moon WJ, Baek JH, Jung SL, et al. Ultrasonography and the ultrasound-based management of thyroid nodules: consensus statement and recommendations. *Korean J Radiol.* 2011;12:1–14.
124. Moon WJ, Jung SL, Lee JH, et al. Benign and malignant thyroid nodules: US differentiation—multicenter retrospective study. *Radiology.* 2008;247:762–770.
125. Brito JP, Gionfriddo MR, Al Nofal A, et al. The accuracy of thyroid nodule ultrasound to predict thyroid cancer: systematic review and meta-analysis. *J Clin Endocrinol Metab.* 2014;99:1253–1263.
126. Kim DS, Kim JH, Na DG, et al. Sonographic features of follicular variant papillary thyroid carcinomas in comparison with conventional papillary thyroid carcinomas. *J Ultrasound Med.* 2009;28:1685–1692.
127. Yang GC, Fried KO. Most thyroid cancers detected by sonography lack intranodular vascularity on color doppler imaging: review of the literature and sonographic-pathologic correlations for 698 thyroid neoplasms. *J Ultrasound Med.* 2017;36:89–94.
128. Jeh SK, Jung SL, Kim BS, Lee YS. Evaluating the degree of conformity of papillary carcinoma and follicular carcinoma to the reported ultrasonographic findings of malignant thyroid tumor. *Korean J Radiol.* 2007;8:192–197.
129. Iared W, Shigueoka DC, Cristófoli JC, et al. Use of color Doppler ultrasonography for the prediction of malignancy in follicular thyroid neoplasms: systematic review and meta-analysis. *J Ultrasound Med.* 2010;29:419–425.
130. Khadra H, Bakeer M, Hauch A, Hu T, Kandil E. Is vascular flow a predictor of malignant thyroid nodules? A meta-analysis. *Gland Surg.* 2016;5:576–582.
131. Grant EG, Tessler FN, Hoang JK, et al. Thyroid ultrasound reporting lexicon: white paper of the ACR Thyroid Imaging, Reporting and Data

- System (TIRADS) Committee. *J Am Coll Radiol*. 2015;12(12 pt A):1272–1279.
132. Tessler FN, Middleton WD, Grant EG, et al. ACR Thyroid Imaging, Reporting and Data System (TI-RADS): White Paper of the ACR TI-RADS Committee. *J Am Coll Radiol*. 2017;14:587–595.
  133. Choi YJ, Baek JH, Baek SH, et al. Web-based malignancy risk estimation for thyroid nodules using ultrasonography characteristics: development and validation of a predictive model. *Thyroid*. 2015;25:1306–1312.
  134. Zhang J, Liu BJ, Xu HX, et al. Prospective validation of an ultrasound-based thyroid imaging reporting and data system (TI-RADS) on 3980 thyroid nodules. *Int J Clin Exp Med*. 2015;8:5911–5917.
  135. Kwak JY, Kim EK, Moon HJ, et al. Parathyroid incidentalomas detected on routine ultrasound-directed fine-needle aspiration biopsy in patients referred for thyroid nodules and the role of parathyroid hormone analysis in the samples. *Thyroid*. 2009;19:743–748.
  136. Ghervan C, Silaghi A, Nemes C. Parathyroid incidentaloma detected during thyroid sonography—prevalence and significance beyond images. *Med Ultrason*. 2012;14:187–191.
  137. Cho M, Oweity T, Brandler TC, Fried K, Levine P. Distinguishing parathyroid and thyroid lesions on ultrasound-guided fine-needle aspiration: a correlation of clinical data, ancillary studies, and molecular analysis. *Cancer Cytopathol*. 2017;125:674–682.
  138. Langer JE, Mandel SJ. Sonographic imaging of cervical lymph nodes in patients with thyroid cancer. *Neuroimaging Clin N Am*. 2008;18:479–489.
  139. Leboulleux S, Girard E, Rose M, et al. Ultrasound criteria of malignancy for cervical lymph nodes in patients followed up for differentiated thyroid cancer. *J Clin Endocrinol Metab*. 2007;92:3590–3594.
  140. Ito Y, Higashiyama T, Takamura Y, et al. Risk factors for recurrence to the lymph node in papillary thyroid carcinoma patients without preoperatively detectable lateral node metastasis: validity of prophylactic modified radical neck dissection. *World J Surg*. 2007;31:2085–2091.
  141. Choi JS, Kim J, Kwak JY, Kim MJ, Chang HS, Kim EK. Preoperative staging of papillary thyroid carcinoma: comparison of ultrasound imaging and CT. *AJR Am J Roentgenol*. 2009;193:871–878.
  142. Hwang HS, Orloff LA. Efficacy of preoperative neck ultrasound in the detection of cervical lymph node metastasis from thyroid cancer. *Laryngoscope*. 2011;121:487–491.
  143. Solbiati L, Osti V, Cova L, Tonolini M. Ultrasound of thyroid, parathyroid glands and neck lymph nodes. *Eur Radiol*. 2001;11:2411–2424.
  144. Popadich A, Levin O, Lee JC, et al. A multicenter cohort study of total thyroidectomy and routine central lymph node dissection for cN0 papillary thyroid cancer. *Surgery*. 2011;150:1048–1057.
  145. Gimm O, Rath FW, Dralle H. Pattern of lymph node metastases in papillary thyroid carcinoma. *Br J Surg*. 1998;85:252–254.
  146. Wu G, Fraser S, Pai SI, Farrag TY, Ladenson PW, Tufano RP. Determining the extent of lateral neck dissection necessary to establish regional disease control and avoid reoperation after previous total thyroidectomy and radioactive iodine for papillary thyroid cancer. *Head Neck*. 2012;34:1418–1421.
  147. Farrag T, Lin F, Brownlee N, Kim M, Sheth S, Tufano RP. Is routine dissection of level II-B and V-A necessary in patients with papillary thyroid cancer undergoing lateral neck dissection for FNA-confirmed metastases in other levels. *World J Surg*. 2009;33:1680–1683.
  148. Kuna SK, Bracic I, Tesic V, Kuna K, Hecceg GH, Dodig D. Ultrasonographic differentiation of benign from malignant neck lymphadenopathy in thyroid cancer. *J Ultrasound Med*. 2006;25:1531–1537.
  149. Gorges R, Eising EG, Fotescu D, et al. Diagnostic value of high-resolution B-mode and power-mode sonography in the follow-up of thyroid cancer. *Eur J Ultrasound*. 2003;16:191–206.
  150. Sipsos JA. Advances in ultrasound for the diagnosis and management of thyroid cancer. *Thyroid*. 2009;19:1363–1372.
  151. Wunderbaldinger P, Harisinghani MG, Hahn PF, et al. Cystic lymph node metastases in papillary thyroid carcinoma. *AJR Am J Roentgenol*. 2002;178:693–697.
  152. Ahuja AT, King W, Metreweli C. Role of ultrasonography in thyroid metastases. *Clin Radiol*. 1994;49:627–629.
  153. Ahuja AT, Ying M, Ho SS, Metreweli C. Distribution of intranodal vessels in differentiating benign from metastatic neck nodes. *Clin Radiol*. 2001;56:197–201.
  154. American Thyroid Association Surgery Working Group, American Association of Endocrine Surgeons, American Academy of Otolaryngology-Head and Neck Surgery, et al. Consensus statement on the terminology and classification of central neck dissection for thyroid cancer. *Thyroid*. 2009;19:1153–1158.
  155. Al-azawi D, Mann GB, Judson RT, Miller JA. Endocrine surgeon-performed US guided thyroid FNAC is accurate and efficient. *World J Surg*. 2012;36:1947–1952.
  156. Kumbhar SS, O'Malley RB, Robinson TJ, et al. Why thyroid surgeons are frustrated with radiologists: lessons learned from pre- and postoperative US. *Radiographics*. 2016;36:2141–2153.
  157. Monteiro R, Han A, Etiwy M, et al. Importance of surgeon-performed ultrasound in the preoperative nodal assessment of patients with potential thyroid malignancy. *Surgery*. 2018;163:112–117.
  158. Wong KP, Au KP, Lam S, Lang BH. Lessons learned after 1000 cases of transcatheter laryngeal ultrasound (TLUSG) with laryngoscopic validation: is there a role of TLUSG in patients indicated for laryngoscopic examination before thyroidectomy? *Thyroid*. 2017;27:88–94.
  159. Kandil E, Deniwar A, Noureldine SI, et al. Assessment of vocal fold function using transcatheter laryngeal ultrasonography and flexible laryngoscopy. *JAMA Otolaryngol Head Neck Surg*. 2016;142:74–78.
  160. Parangi S. Editorial: Translaryngeal vocal cord ultrasound: Ready for prime time. *Surgery*. 2016;159:67–69.
  161. Carneiro-Pla D, Miller BS, Wilhelm SM, et al. Feasibility of surgeon-performed transcatheter vocal cord ultrasonography in identifying vocal cord mobility: a multi-institutional experience. *Surgery*. 2014;156:1597–1602.
  162. Carneiro-Pla D, Solorzano CC, Wilhelm SM. Impact of vocal cord ultrasonography on endocrine surgery practices. *Surgery*. 2016;159:58–64.
  163. Moon HJ, Kim EK, Yoon JH, Kwak JY. Differences in the diagnostic performances of staging US for thyroid malignancy according to experience. *Ultrasound Med Biol*. 2012;38:568–573.
  164. Bhatki AM, Brewer B, Robinson-Smith T, Nikiforov Y, Steward DL. Adequacy of surgeon-performed ultrasound-guided thyroid fine-needle aspiration biopsy. *Otolaryngol Head Neck Surg*. 2008;139:27–31.
  165. Jeong HS, Baek CH, Son YI, et al. Integrated 18F-FDG PET/CT for the initial evaluation of cervical node level of patients with papillary thyroid carcinoma: comparison with ultrasound and contrast-enhanced CT. *Clin Endocrinol (Oxf)*. 2006;65:402–407.
  166. Padovani RP, Kasamatsu TS, Nakabashi CCD, et al. One month is sufficient for urinary iodine to return to its baseline value after the use of water-soluble iodinated contrast agents in post-thyroidectomy patients requiring radioiodine therapy. *Thyroid*. 2012;22:926–930.
  167. Rago T, Santini F, Scutari M, Pinchera A, Vitti P. Elastography: new developments in ultrasound for predicting malignancy in thyroid nodules. *J Clin Endocrinol Metab*. 2007;92:2917–2922.
  168. Moon HJ, Sung JM, Kim EK, Yoon JH, Youk JH, Kwak JY. Diagnostic performance of gray-scale US and elastography in solid thyroid nodules. *Radiology*. 2012;262:1002–1013.
  169. Azizi G, Keller J, Lewis M, Puett D, Rivenbark K, Malchoff C. Performance of elastography for the evaluation of thyroid nodules: a prospective study. *Thyroid*. 2013;23:734–740.
  170. Are C, Hsu JF, Schoder H, et al. FDG-PET detected thyroid incidentalomas: need for further investigation? *Ann Surg Oncol*. 2007;14:239–247.
  171. Katz SC, Shaha A. PET-associated incidental neoplasms of the thyroid. *J Am Coll Surg*. 2008;207:259–264.
  172. Barrio M, Czernin J, Yeh MW, et al. The incidence of thyroid cancer in focal hypermetabolic thyroid lesions: an 18F-FDG PET/CT study in more than 6000 patients. *Nucl Med Commun*. 2016;37:1290–1296.
  173. Hari Kumar KV, Pasupuleti V, Jayaraman M, Abhyuday V, Rayudu BR, Modi KD. Role of thyroid Doppler in differential diagnosis of thyrotoxicosis. *Endocr Pract*. 2009;15:6–9.
  174. Rosario PW, Santos JB, Nunes NS, da Silva AL, Calsolari MR. Color flow Doppler sonography for the etiologic diagnosis of thyrotoxicosis. *Horm Metab Res*. 2014;46:505–509.
  175. Avram AM. Radioiodine scintigraphy with SPECT/CT: an important diagnostic tool for thyroid cancer staging and risk stratification. *J Nucl Med Technol*. 2014;42:170–180.
  176. Grünwald F, Källicke T, Feine U, Lietzenmayer R, et al. Fluorine-18 fluorodeoxyglucose positron emission tomography in thyroid cancer: results of a multicenter study. *Eur J Nucl Med*. 1999;26:1547–1552.
  177. Francis CL, Nalley C, Fan C, Bodenner D, Stack BC Jr. 18F-fluorodeoxyglucose and 131I radioguided surgical management of thyroid cancer. *Otolaryngol Head Neck Surg*. 2012;146:26–32.
  178. Schlüter B, Bohuslavizki KH, Beyer W, Plotkin M, Buchert R, Clausen M. Impact of FDG PET on patients with differentiated thyroid cancer who present with elevated thyroglobulin and negative 131I scan. *J Nucl Med*. 2001;42:71–76.

179. Wang W, Macapinlac H, Larson SM, et al. [18F]-2-fluoro-2-deoxy-D-glucose positron emission tomography localizes residual thyroid cancer in patients with negative diagnostic (131)I whole body scans and elevated serum thyroglobulin levels. *J Clin Endocrinol Metab.* 1999;84:2291–2302.
180. Robbins RJ, Wan Q, Grewal RK, et al. Real-time prognosis for metastatic thyroid carcinoma based on 2-[18F]fluoro-2-deoxy-D-glucose-positron emission tomography scanning. *J Clin Endocrinol Metab.* 2006;91:498–505.
181. Finkelstein SE, Grigsby PW, Siegel BA, Dehdashti F, Moley JF, Hall BL. Combined [18F]Fluorodeoxyglucose positron emission tomography and computed tomography (FDG-PET/CT) for detection of recurrent, 131I-negative thyroid cancer. *Ann Surg Oncol.* 2008;15:286–292.
182. Kim SJ, Lee TH, Kim JJ, Kim YK. Clinical implication of F-18 FDG PET/CT for differentiated thyroid cancer in patients with negative diagnostic iodine-123 scan and elevated thyroglobulin. *Eur J Radiol.* 2009;70:17–24.
183. Mirallicé E, Guillan T, Bridji B, et al. Therapeutic impact of 18FDG-PET/CT in the management of iodine-negative recurrence of differentiated thyroid carcinoma. *Surgery.* 2007;142:952–958.
184. Shamma A, Degirmenci B, Mountz JM, et al. 18F-FDG PET/CT in patients with suspected recurrent or metastatic well-differentiated thyroid cancer. *J Nucl Med.* 2007;48:221–226.
185. Robbins RJ, Srivastava S, Shaha A, et al. Factors influencing the basal and recombinant human thyrotropin-stimulated serum thyroglobulin in patients with metastatic thyroid carcinoma. *J Clin Endocrinol Metab.* 2004;89:6010–6016.
186. Agrawal A, Hall NC, Ringel MD, Povoski SP, Martin EW Jr. Combined use of perioperative TSH-stimulated (18)F-FDG PET/CT imaging and gamma probe radioguided surgery to localize and verify resection of iodine scan-negative recurrent thyroid carcinoma. *Laryngoscope.* 2008;118:2190–2194.
187. Leboulleux S, Schroeder PR, Busaidy NL, et al. Assessment of the incremental value of recombinant thyrotropin stimulation before 2-[18F]-Fluoro-2-deoxy-D-glucose positron emission tomography/computed tomography imaging to localize residual differentiated thyroid cancer. *J Clin Endocrinol Metab.* 2009;94:1310–1316.
188. Miller JM, Hamburger JI, Kini S. Diagnosis of thyroid nodules. Use of fine-needle aspiration and needle biopsy. *JAMA.* 1979;241:481–484.
189. Wetzig NR, Giddings AE. Solitary thyroid nodule: audit shows improved care requires cytological diagnosis. *Ann R Coll Surg Engl.* 1989;71:316–319.
190. Sosa JA, Hanna JW, Robinson KA, Lanman RB. Increases in thyroid nodule fine-needle aspirations, operations, and diagnoses of thyroid cancer in the United States. *Surgery.* 2013;154:1420–1426.
191. Machens A, Holzhausen HJ, Dralle H. The prognostic value of primary tumor size in papillary and follicular thyroid carcinoma. *Cancer.* 2005;103:2269–2273.
192. Cavallo A, Johnson DN, White MG, et al. Thyroid nodule size at ultrasound as a predictor of malignancy and final pathologic size. *Thyroid.* 2017;27:641–650.
193. Cappelli C, Pirola I, Agosti B, et al. Complications after fine-needle aspiration cytology: a retrospective study of 7449 consecutive thyroid nodules. *Br J Oral Maxillofac Surg.* 2017;55:266–269.
194. Abu-Yousef MM, Larson JH, Kuehn DM, Wu AS, Laroia AT. Safety of ultrasound-guided fine needle aspiration biopsy of neck lesions in patients taking antithrombotic/anticoagulant medications. *Ultrasound Q.* 2011;27:157–159.
195. Lyle MA, Dean DS. Ultrasound-guided fine-needle aspiration biopsy of thyroid nodules in patients taking novel oral anticoagulants. *Thyroid.* 2015;25:373–376.
196. Pitman MB, Abele J, Ali SZ, et al. Techniques for thyroid FNA: a synopsis of the National Cancer Institute Thyroid Fine-Needle Aspiration State of the Science Conference. *Diagn Cytopathol.* 2008;36:407–424.
197. Guo HQ, Zhang ZH, Zhao H, Niu LJ, Chang Q, Pan QJ. Factors influencing the reliability of thyroid fine-needle aspiration: analysis of thyroid nodule size, guidance mode for aspiration and preparation method. *Acta Cytol.* 2015;59:169–174.
198. Izquierdo R, Arekat MR, Knudson PE, et al. Comparison of palpation-guided versus ultrasound-guided fine-needle aspiration biopsies of thyroid nodules in an outpatient endocrinology practice. *Endocr Pract.* 2006;12:609–614.
199. Can AS, Peker K. Comparison of palpation-versus ultrasound-guided fine-needle aspiration biopsies in the evaluation of thyroid nodules. *BMC Res Notes.* 2008;1:12.
200. Can AS. Cost-effectiveness comparison between palpation- and ultrasound-guided thyroid fine-needle aspiration biopsies. *BMC Endocr Disord.* 2009;9:14.
201. Cibas ES, Alexander EK, Benson CB, et al. Indications for thyroid FNA and pre-FNA requirements: a synopsis of the National Cancer Institute Thyroid Fine-Needle Aspiration State of the Science Conference. *Diagn Cytopathol.* 2008;36:390–399.
202. Lee YH, Baek JH, Jung SL, et al. Ultrasound-guided fine needle aspiration of thyroid nodules: a consensus statement by the Korean society of thyroid radiology. *Korean J Radiol.* 2015;16:391–401.
203. Lalzad A, Ristitsch D, Downey W, Little AF, Schneider-Kolsky ME. Effect of ultrasound transmission gel on ultrasound-guided fine needle aspiration cytological specimens of thyroid. *Cytopathology.* 2012;23:330–333.
204. Grani G, Fumarola A. Thyroglobulin in lymph node fine-needle aspiration washout: a systematic review and meta-analysis of diagnostic accuracy. *J Clin Endocrinol Metab.* 2014;99:1970–1982.
205. Bof F, Baghino G, Atzeni F, Lai ML, Faa G, Mariotti S. The diagnostic value for differentiated thyroid carcinoma metastases of thyroglobulin (Tg) measurement in washout fluid from fine-needle aspiration biopsy of neck lymph nodes is maintained in the presence of circulating anti-Tg antibodies. *J Clin Endocrinol Metab.* 2006;91:1364–1369.
206. Shin JH, Baek JH, Chung J, et al. Ultrasonography diagnosis and imaging-based management of thyroid nodules: revised Korean Society of Thyroid Radiology Consensus Statement and Recommendations. *Korean J Radiol.* 2016;17:370–395.
207. Witt BL, Schmidt RL. Rapid onsite evaluation improves the adequacy of fine-needle aspiration for thyroid lesions: a systematic review and meta-analysis. *Thyroid.* 2013;23:428–435.
208. Baloch ZW, Cibas ES, Clark DP, et al. The National Cancer Institute Thyroid fine needle aspiration state of the science conference: a summation. *Cytojournal.* 2008;5:6.
209. de Koster EJ, Kist JW, Vriens MR, Borel Rinkes IH, Valk GD, de Keizer B. Thyroid ultrasound-guided fine-needle aspiration: the positive influence of on-site adequacy assessment and number of needle passes on diagnostic cytology rate. *Acta Cytol.* 2016;60:39–45.
210. Cristo AP, Goldstein HF, Faccin CS, Maia AL, Graudenz MS. Increasing diagnostic effectiveness of thyroid nodule evaluation by implementation of cell block preparation in routine US-FNA analysis. *Arch Endocrinol Metab.* 2016;60:367–373.
211. Grani G, Calvanese A, Carbotta G, et al. Intrinsic factors affecting adequacy of thyroid nodule fine-needle aspiration cytology. *Clin Endocrinol (Oxf).* 2013;78:141–144.
212. Baloch ZW, LiVolsi VA, Asa SL, et al. Diagnostic terminology and morphologic criteria for cytologic diagnosis of thyroid lesions: a synopsis of the National Cancer Institute Thyroid Fine-Needle Aspiration State of the Science Conference. *Diagn Cytopathol.* 2008;36:425–437.
213. Cibas ES, Ali SZ. The 2017 Bethesda System for Reporting Thyroid Cytopathology. *Thyroid.* 2017;27:1341–1346.
214. Faquin WC, Wong LQ, Afrogheh AH, et al. Impact of reclassifying noninvasive follicular variant of papillary thyroid carcinoma on the risk of malignancy in The Bethesda System for Reporting Thyroid Cytopathology. *Cancer Cytopathol.* 2016;124:181–187.
215. Strickland KC, Howitt BE, Marqusee E, et al. The impact of noninvasive follicular variant of papillary thyroid carcinoma on rates of malignancy for fine-needle aspiration diagnostic categories. *Thyroid.* 2015;25:987–992.
216. Baloch ZW, Seethala RR, Faquin WC, et al. Noninvasive follicular thyroid neoplasm with papillary-like nuclear features (NIFTP): a changing paradigm in thyroid surgical pathology and implications for thyroid cytopathology. *Cancer Cytopathol.* 2016;124:616–620.
217. Bongiovanni M, Spitale A, Faquin WC, Mazzucchelli L, Baloch ZW. The Bethesda System for Reporting Thyroid Cytopathology: a meta-analysis. *Acta Cytol.* 2012;56:333–339.
218. McCoy KL, Jabbour N, Ogilvie JB, Otori NP, Carty SE, Yim JH. The incidence of cancer and rate of false-negative cytology in thyroid nodules greater than or equal to 4 cm in size. *Surgery.* 2007;142:837–844.
219. Wharry LI, McCoy KL, Stang MT, et al. Thyroid nodules (>= 4 cm): can ultrasound and cytology reliably exclude cancer? *World J Surg.* 2014;38:614–621.
220. Albuja-Cruz MB, Goldfarb M, Gondek SS, Allan BJ, Lew JI. Reliability of fine-needle aspiration for thyroid nodules greater than or equal to 4 cm. *J Surg Res.* 2013;181:6–10.
221. Pusztaszeri MP, Bongiovanni M, Faquin WC. Update on the cytologic and molecular features of medullary thyroid carcinoma. *Adv Anat Pathol.* 2014;21:26–35.

222. Manning AM, Yang H, Falciglia M, Mark JR, Steward DL. Thyroid ultrasound-guided fine-needle aspiration cytology results: observed increase in indeterminate rate over the past decade. *Otolaryngol Head Neck Surg*. 2017;156:611–615.
223. Chen JC, Pace SC, Chen BA, Khiyami A, McHenry CR. Yield of repeat fine-needle aspiration biopsy and rate of malignancy in patients with atypia or follicular lesion of undetermined significance: the impact of the Bethesda System for Reporting Thyroid Cytopathology. *Surgery*. 2012;152:1037–1044.
224. Gweon HM, Son EJ, Youk JH, Kim JA. Thyroid nodules with Bethesda system III cytology: can ultrasonography guide the next step? *Ann Surg Oncol*. 2013;20:3083–3088.
225. Méndez W, Rodgers SE, Lew JI, Montano R, Solórzano CC. Role of surgeon-performed ultrasound in predicting malignancy in patients with indeterminate thyroid nodules. *Ann Surg Oncol*. 2008;15:2487–2492.
226. Gan TR, Nga ME, Lum JH, et al. Thyroid cytology-nuclear versus architectural atypia within the “Atypia of undetermined significance/follicular lesion of undetermined significance” Bethesda category have significantly different rates of malignancy. *Cancer*. 2017;125:245–256.
227. Chen JC, Pace SC, Khiyami A, McHenry CR. Should atypia of undetermined significance be subclassified to better estimate risk of thyroid cancer? *Am J Surg*. 2014;207:331–336.
228. Zhang W, Policarpio-Nicolas ML. Aspiration cytology of primary thyroid paraganglioma. *Diagn Cytopathol*. 2015;43:838–843.
229. Cibas ES, Baloch ZW, Fellegara G, et al. A prospective assessment defining the limitations of thyroid nodule pathologic evaluation. *Ann Intern Med*. 2013;159:325–332.
230. Gerhard R, Boerner SL. The value of second opinion in thyroid cytology: a review. *Cancer Cytopathol*. 2014;122:611–619.
231. Olson MT, Boonyaarunnate T, Aragon Han P, Umbricht CB, Ali SZ, Zeiger MA. A tertiary center’s experience with second review of 3885 thyroid cytopathology specimens. *J Clin Endocrinol Metab*. 2013;98:1450–1457.
232. Trimboli P, Treglia G, Guidobaldi L, et al. Detection rate of FNA cytology in medullary thyroid carcinoma: a meta-analysis. *Clin Endocrinol (Oxf)*. 2015;82:280–285.
233. Trimboli P, Cremonini N, Ceriani L, et al. Calcitonin measurement in aspiration needle washout fluids has higher sensitivity than cytology in detecting medullary thyroid cancer: a retrospective multicentre study. *Clin Endocrinol (Oxf)*. 2014;80:135–140.
234. Liu X, Medici M, Kwong N, et al. Bethesda categorization of thyroid nodule cytology and prediction of thyroid cancer type and prognosis. *Thyroid*. 2016;26:256–261.
235. Rago T, Scutari M, Latrofa F, et al. The large majority of 1520 patients with indeterminate thyroid nodule at cytology have a favorable outcome, and a clinical risk score has a high negative predictive value for a more cumbersome cancer disease. *J Clin Endocrinol Metab*. 2014;99:3700–3707.
236. Kleiman DA, Beninato T, Soni A, Shou Y, Zarnegar R, Fahey TJ 3rd. Does Bethesda category predict aggressive features in malignant thyroid nodules? *Ann Surg Oncol*. 2013;20:3484–3490.
237. Nishino M, Nikiforova M. Update on molecular testing for cytologically indeterminate thyroid nodules. *Arch Pathol Lab Med*. 2018;142:446–457.
238. Cancer Genome Atlas Research Network. Integrated genomic characterization of papillary thyroid carcinoma. *Cell*. 2014;159:676–690.
239. National Comprehensive Cancer Network. Thyroid Carcinoma (Version 2.2017). [http://www.nccn.org/professionals/physician\\_gls/pdf/thyroid.pdf](http://www.nccn.org/professionals/physician_gls/pdf/thyroid.pdf). Accessed July 19, 2019.
240. Aragon Han P, Olson MT, Fazeli R, et al. The impact of molecular testing on the surgical management of patients with thyroid nodules. *Ann Surg Oncol*. 2014;21:1862–1869.
241. U.S. Department of Health and Human Services. ACCE Model Process for Evaluating Genetic Tests. <https://www.cdc.gov/genomics/gtesting/ACCE/>. Accessed July 19, 2019.
242. Ferris RL, Baloch Z, Bernet V, et al. American thyroid association statement on surgical application of molecular profiling for thyroid nodules: current impact on perioperative decision making. *Thyroid*. 2015;25:760–768.
243. Nikiforov YE, Steward DL, Robinson-Smith TM, et al. Molecular testing for mutations in improving the fine-needle aspiration diagnosis of thyroid nodules. *J Clin Endocrinol Metab*. 2009;94:2092–2098.
244. Cantara S, Capezone M, Marchisotta S, et al. Impact of proto-oncogene mutation detection in cytological specimens from thyroid nodules improves the diagnostic accuracy of cytology. *J Clin Endocrinol Metab*. 2010;95:1365–1369.
245. Yip L, Farris C, Kabaker AS, et al. Cost impact of molecular testing for indeterminate thyroid nodule fine-needle aspiration biopsies. *J Clin Endocrinol Metab*. 2012;97:1905–1912.
246. Nikiforov YE, Otori NP, Hodak SP, et al. Impact of mutational testing on the diagnosis and management of patients with cytologically indeterminate thyroid nodules: a prospective analysis of 1056 FNA samples. *J Clin Endocrinol Metab*. 2011;96:3390–3397.
247. Beaudenon-Huibregtse S, Alexander EK, Guttler RB, et al. Centralized molecular testing for oncogenic gene mutations complements the local cytopathologic diagnosis of thyroid nodules. *Thyroid*. 2014;24:1479–1487.
248. Eszlinger M, Hegedus L, Paschke R. Ruling in or ruling out thyroid malignancy by molecular diagnostics of thyroid nodules. *Best Pract Res Clin Endocrinol Metab*. 2014;28:545–557.
249. Eszlinger M, Krogdahl A, Münz S, et al. Impact of molecular screening for point mutations and rearrangements in routine air-dried fine-needle aspiration samples of thyroid nodules. *Thyroid*. 2014;24:305–313.
250. Krane JF, Cibas ES, Alexander EK, Paschke R, Eszlinger M. Molecular analysis of residual ThinPrep material from thyroid FNAs increases diagnostic sensitivity. *Cancer Cytopathol*. 2015;123:356–361.
251. Eszlinger M, Böhme K, Ullmann M, et al. Evaluation of a two-year routine application of molecular testing of thyroid fine-needle aspirations using a seven-gene panel in a primary referral setting in Germany. *Thyroid*. 2017;27:402–411.
252. Yip L, Wharry LI, Armstrong MJ, et al. A clinical algorithm for fine-needle aspiration molecular testing effectively guides the appropriate extent of initial thyroidectomy. *Ann Surg*. 2014;260:163–168.
253. Labourier E, Shifrin A, Busseniers AE, et al. Molecular testing for miRNA, mRNA, and DNA on fine-needle aspiration improves the preoperative diagnosis of thyroid nodules with indeterminate cytology. *J Clin Endocrinol Metab*. 2015;100:2743–2750.
254. Valderrabano P, Leon ME, Centeno BA, et al. Institutional prevalence of malignancy of indeterminate thyroid cytology is necessary but insufficient to accurately interpret molecular marker tests. *Eur J Endocrinol*. 2016;174:621–629.
255. Partyka KL, Randolph ML, Lawrence KA, Cramer H, Wu HH. Utilization of direct smears of thyroid fine-needle aspirates for ancillary molecular testing: a comparison of two proprietary testing platforms. *Diagn Cytopathol*. 2018;46:320–325.
256. Nikiforova MN, Mercurio S, Wald AI, et al. Analytical performance of the ThyroSeq v3 genomic classifier for cancer diagnosis in thyroid nodules. *Cancer*. 2018;124:1682–1690.
257. Valderrabano P, Khazai L, Leon ME, et al. Evaluation of ThyroSeq v2 performance in thyroid nodules with indeterminate cytology. *Endocr Relat Cancer*. 2017;24:127–136.
258. Taye A, Gurciullo D, Miles BA, et al. Clinical performance of a next-generation sequencing assay (ThyroSeq v2) in the evaluation of indeterminate thyroid nodules. *Surgery*. 2018;163:97–103.
259. Nikiforov YE, Carty SE, Chiosea SI, et al. Highly accurate diagnosis of cancer in thyroid nodules with follicular neoplasm/suspicious for a follicular neoplasm cytology by ThyroSeq v2 next-generation sequencing assay. *Cancer*. 2014;120:3627–3634.
260. Steward DL, Carty SE, Sippel RS, et al. Performance of a multigene genomic classifier in thyroid nodules with indeterminate cytology: a prospective blinded multicenter study. *JAMA Oncol*. 2019;5:204–212.
261. Chudova D, Wilde JI, Wang ET, et al. Molecular classification of thyroid nodules using high-dimensionality genomic data. *J Clin Endocrinol Metab*. 2010;95:5296–5304.
262. Kloos RT, Reynolds JD, Walsh PS, et al. Does addition of BRAF V600E mutation testing modify sensitivity or specificity of the Afirma Gene Expression Classifier in cytologically indeterminate thyroid nodules? *J Clin Endocrinol Metab*. 2013;98:E761–E768.
263. Pankratz DG, Hu Z, Kim SY, et al. Analytical performance of a gene expression classifier for medullary thyroid carcinoma. *Thyroid*. 2016;26:1573–1580.
264. Patel KN, Angell TE, Babiarczyk J, et al. Performance of a genomic sequencing classifier for the preoperative diagnosis of cytologically indeterminate thyroid nodules. *JAMA Surg*. 2018;153:817–824.
265. Alexander EK, Kennedy GC, Baloch ZW, et al. Preoperative diagnosis of benign thyroid nodules with indeterminate cytology. *N Engl J Med*. 2012;367:705–715.
266. McIver B, Castro MR, Morris JC, et al. An independent study of a gene expression classifier (Afirma) in the evaluation of cytologically indeterminate thyroid nodules. *J Clin Endocrinol Metab*. 2014;99:4069–4077.



267. Chaudhary S, Hou Y, Shen R, Hooda S, Li Z. Impact of the Afirma gene expression classifier result on the surgical management of thyroid nodules with category III/IV cytology and its correlation with surgical outcome. *Acta Cytol.* 2016;60:205–210.
268. Wu JX, Young S, Hung ML, et al. Clinical factors influencing the performance of gene expression classifier testing in indeterminate thyroid nodules. *Thyroid.* 2016;26:916–922.
269. Samulski TD, LiVolsi VA, Wong LQ, Baloch Z. Usage trends and performance characteristics of a “gene expression classifier” in the management of thyroid nodules: an institutional experience. *Diagn Cytopathol.* 2016;44:867–873.
270. Al-Qurayshi Z, Deniwar A, Thethi T, et al. Association of malignancy prevalence with test properties and performance of the gene expression classifier in indeterminate thyroid nodules. *JAMA Otolaryngol Head Neck Surg.* 2017;143:403–408.
271. Noureldine SI, Olson MT, Agrawal N, Prescott JD, Zeiger MA, Tufano RP. Effect of gene expression classifier molecular testing on the surgical decision-making process for patients with thyroid nodules. *JAMA Otolaryngol Head Neck Surg.* 2015;141:1082–1088.
272. Harrell RM, Bimston DN. Surgical utility of Afirma: effects of high cancer prevalence and oncocytic cell types in patients with indeterminate thyroid cytology. *Endocr Pract.* 2014;20:364–369.
273. Duh QY, Busaidy NL, Rahilly-Tierney C, Gharib H, Randolph G. A systematic review of the methods of diagnostic accuracy studies of the Afirma Gene Expression Classifier. *Thyroid.* 2017;27:1215–1222.
274. Celik B, Whetsell CR, Nassar A. Afirma GEC and thyroid lesions: an institutional experience. *Diagn Cytopathol.* 2015;43:966–970.
275. Dhingra JK. Office-based ultrasound-guided FNA with molecular testing for thyroid nodules. *Otolaryngol Head Neck Surg.* 2016;155:564–567.
276. Marti JL, Avadhani V, Donatelli LA, et al. Wide inter-institutional variation in performance of a molecular classifier for indeterminate thyroid nodules. *Ann Surg Oncol.* 2015;22:3996–4001.
277. Roychoudhury S, Klein M, Souza F, et al. How “suspicious” is that nodule? Review of “suspicious” Afirma gene expression classifier in high risk thyroid nodules. *Diagn Cytopathol.* 2017;45:308–311.
278. Baca SC, Wong KS, Strickland KC, et al. Qualifiers of atypia in the cytologic diagnosis of thyroid nodules are associated with different Afirma gene expression classifier results and clinical outcomes. *Cancer Cytopathol.* 2017;125:313–322.
279. Harrison G, Sosa JA, Jiang X. Evaluation of the Afirma gene expression classifier in repeat indeterminate thyroid nodules. *Arch Pathol Lab Med.* 2017;141:985–989.
280. Kay-Rivest E, Tibbo J, Bouhabel S, et al. The first Canadian experience with the Afirma(R) gene expression classifier test. *J Otolaryngol Head Neck Surg.* 2017;46:25.
281. Li H, Robinson KA, Anton B, Saldanha IJ, Ladenson PW. Cost-effectiveness of a novel molecular test for cytologically indeterminate thyroid nodules. *J Clin Endocrinol Metab.* 2011;96:E1719–E1726.
282. Duick DS, Klopper JP, Diggans JC, et al. The impact of benign gene expression classifier test results on the endocrinologist-patient decision to operate on patients with thyroid nodules with indeterminate fine-needle aspiration cytopathology. *Thyroid.* 2012;22:996–1001.
283. Lee L, How J, Tabah RJ, Mitmaker EJ. Cost-effectiveness of molecular testing for thyroid nodules with atypia of undetermined significance cytology. *J Clin Endocrinol Metab.* 2014;99:2674–2682.
284. Wu JX, Lam R, Levin M, Rao J, Sullivan PS, Yeh MW. Effect of malignancy rates on cost-effectiveness of routine gene expression classifier testing for indeterminate thyroid nodules. *Surgery.* 2016;159:118–126.
285. Dedhia PH, Rubio GA, Cohen MS, Miller BS, Gauger PG, Hughes DT. Potential effects of molecular testing of indeterminate thyroid nodule fine needle aspiration biopsy on thyroidectomy volume. *World J Surg.* 2014;38:634–638.
286. Sipos JA, Blevins TC, Shea HC, et al. Long-term nonoperative rate of thyroid nodules with benign results on the afirma gene expression classifier. *Endocr Pract.* 2016;22:666–672.
287. Ganly I, Ricarte Filho J, Eng S, et al. Genomic dissection of Hurthle cell carcinoma reveals a unique class of thyroid malignancy. *J Clin Endocrinol Metab.* 2013;98:E962–E972.
288. Brauner E, Holmes BJ, Krane JF, et al. Performance of the afirma gene expression classifier in hurthle cell thyroid nodules differs from other indeterminate thyroid nodules. *Thyroid.* 2015;25:789–796.
289. Noureldine SI, Najafian A, Aragon Han P, et al. Evaluation of the effect of diagnostic molecular testing on the surgical decision-making process for patients with thyroid nodules. *JAMA Otolaryngol Head Neck Surg.* 2016;142:676–682.
290. Livhits MJ, Kuo EJ, Leung AM, et al. Gene expression classifier versus targeted next-generation sequencing in the management of indeterminate thyroid nodules. *J Clin Endocrinol Metab.* 2018;103:2261–2268.
291. Yip L, Nikiforova MN, Yoo JY, et al. Tumor genotype determines phenotype and disease-related outcomes in thyroid cancer: a study of 1510 patients. *Ann Surg.* 2015;262:519–525.
292. Howell GM, Nikiforova MN, Carty SE, et al. BRAF V600E mutation independently predicts central compartment lymph node metastasis in patients with papillary thyroid cancer. *Ann Surg Oncol.* 2013;20:47–52.
293. Li C, Lee KC, Schneider EB, Zeiger MA. BRAF V600E mutation and its association with clinicopathological features of papillary thyroid cancer: a meta-analysis. *J Clin Endocrinol Metab.* 2012;97:4559–4570.
294. Xing M, Alzahrani AS, Carson KA, et al. Association between BRAF V600E mutation and recurrence of papillary thyroid cancer. *J Clin Oncol.* 2015;33:42–50.
295. Chen Y, Sadow PM, Suh H, et al. BRAF(V600E) is correlated with recurrence of papillary thyroid microcarcinoma: a systematic review, multi-institutional primary data analysis, and meta-analysis. *Thyroid.* 2016;26:248–255.
296. Huang Y, Qu S, Zhu G, et al. BRAF V600E mutation-assisted risk stratification of solitary intrathyroidal papillary thyroid cancer for precision treatment. *J Natl Cancer Inst.* 2018;110:362–370.
297. Xing M, Alzahrani AS, Carson KA, et al. Association between BRAF V600E mutation and mortality in patients with papillary thyroid cancer. *JAMA.* 2013;309:1493–1501.
298. Tufano RP, Teixeira GV, Bishop J, Carson KA, Xing M. BRAF mutation in papillary thyroid cancer and its value in tailoring initial treatment: a systematic review and meta-analysis. *Medicine (Baltimore).* 2012;91:274–286.
299. Afkhami M, Karunamurthy A, Chiosea S, et al. Histopathologic and clinical characterization of thyroid tumors carrying the BRAF(K601E) Mutation. *Thyroid.* 2016;26:242–247.
300. Liu X, Qu S, Liu R, et al. TERT promoter mutations and their association with BRAF V600E mutation and aggressive clinicopathological characteristics of thyroid cancer. *J Clin Endocrinol Metab.* 2014;99:E1130–E1136.
301. Melo M, da Rocha AG, Vinagre J, et al. TERT promoter mutations are a major indicator of poor outcome in differentiated thyroid carcinomas. *J Clin Endocrinol Metab.* 2014;99:E754–E765.
302. Kim TH, Ki CS, Kim HS, et al. Refining dynamic risk stratification and prognostic groups for differentiated thyroid cancer with TERT promoter mutations. *J Clin Endocrinol Metab.* 2017;102:1757–1764.
303. Shrestha RT, Karunamurthy A, Amin K, et al. Multiple mutations detected preoperatively may predict aggressive behavior of papillary thyroid cancer and guide management: a case report. *Thyroid.* 2015;25:1375–1378.
304. Moon S, Song YS, Kim YA, et al. Effects of coexistent BRAF(V600E) and TERT promoter mutations on poor clinical outcomes in papillary thyroid cancer: a meta-analysis. *Thyroid.* 2017;27:651–660.
305. Patel SG, Carty SE, McCoy KL, et al. Preoperative detection of RAS mutation may guide extent of thyroidectomy. *Surgery.* 2017;161:168–175.
306. Kim M, Jeon MJ, Oh HS, et al. BRAF and RAS mutational status in non-invasive follicular thyroid neoplasm with papillary-like nuclear features and invasive subtype of encapsulated follicular variant of papillary thyroid carcinoma in Korea. *Thyroid.* 2018;28:504–510.
307. Elsheikh TM, Asa SL, Chan JK, et al. Interobserver and intraobserver variation among experts in the diagnosis of thyroid follicular lesions with borderline nuclear features of papillary carcinoma. *Am J Clin Pathol.* 2008;130:736–744.
308. Balentine CJ, Vanness DJ, Schneider DF. Cost-effectiveness of lobectomy versus genetic testing (Afirma(R)) for indeterminate thyroid nodules: considering the costs of surveillance. *Surgery.* 2018;163:88–96.
309. Rivas AM, Nassar A, Zhang J, et al. ThyroSeq(R)V2.0 molecular testing: a cost-effective approach for the evaluation of indeterminate thyroid nodules. *Endocr Pract.* 2018;24:780–788.
310. Vargas-Salas S, Martínez JR, Urrea S, et al. Genetic testing for indeterminate thyroid cytology: review and meta-analysis. *Endocr Relat Cancer.* 2018;25:R163–R177.
311. Nikiforov YE, Seethala RR, Tallini G, et al. Nomenclature revision for encapsulated follicular variant of papillary thyroid carcinoma: a paradigm shift to reduce overtreatment of indolent tumors. *JAMA Oncol.* 2016;2:1023–1029.

312. Jug RC, Datto MB, Jiang XS. Molecular testing for indeterminate thyroid nodules: performance of the Afirma gene expression classifier and ThyroSeq panel. *Cancer Cytopathol.* 2018;126:471–480.
313. Eng OS, Potdevin L, Davidov T, et al. Does nodule size predict compressive symptoms in patients with thyroid nodules? *Gland Surg.* 2014;3:232–236.
314. Bakkar S, Poma AM, Corsini C, et al. Underestimated risk of cancer in solitary thyroid nodules >1=3 cm reported as benign. *Langenbecks Arch Surg.* 2017;402:1089–1094.
315. Tee YY, Lowe AJ, Brand CA, Judson RT. Fine-needle aspiration may miss a third of all malignancy in palpable thyroid nodules: a comprehensive literature review. *Ann Surg.* 2007;246:714–720.
316. Shaha AR, Burnett C, Alfonso A, Jaffe BM. Goiters and airway problems. *Am J Surg.* 1989;158:378–380.
317. Hedayati N, McHenry CR. The clinical presentation and operative management of nodular and diffuse substernal thyroid disease. *Am Surg.* 2002;68:245–251.
318. McManus C, Luo J, Sippel R, Chen H. Should patients with symptomatic Hashimoto's thyroiditis pursue surgery? *J Surg Res.* 2011;170:52–55.
319. Mittendorf EA, McHenry CR. Thyroidectomy for selected patients with thyrotoxicosis. *Arch Otolaryngol Head Neck Surg.* 2001;127:61–65.
320. O'Brien T, Gharib H, Suman VJ, van Heerden JA. Treatment of toxic solitary thyroid nodules: surgery versus radioactive iodine. *Surgery.* 1992;112:1166–1170.
321. Hay ID. Management of patients with low-risk papillary thyroid carcinoma. *Endocr Pract.* 2007;13:521–533.
322. Mazzaferri EL. Management of low-risk differentiated thyroid cancer. *Endocr Pract.* 2007;13:498–512.
323. Pavlidis ET, Pavlidis TE. A review of primary thyroid lymphoma: molecular factors, diagnosis and management. *J Invest Surg.* 2017;1–6.
324. Molinaro E, Romei C, Biagini A, et al. Anaplastic thyroid carcinoma: from clinicopathology to genetics and advanced therapies. *Nat Rev Endocrinol.* 2017;13:644–660.
325. Matsuzo K, Sugino K, Masudo K, et al. Thyroid lobectomy for papillary thyroid cancer: long-term follow-up study of 1,088 cases. *World J Surg.* 2014;38:68–79.
326. Mendelsohn AH, Elashoff DA, Abemayor E, St John MA. Surgery for papillary thyroid carcinoma: is lobectomy enough? *Arch Otolaryngol Head Neck Surg.* 2010;136:1055–1061.
327. Nixon IJ, Ganly I, Patel SG, et al. Thyroid lobectomy for treatment of well differentiated intrathyroid malignancy. *Surgery.* 2012;151:571–579.
328. Gartland RM, Lubitz CC. Impact of extent of surgery on tumor recurrence and survival for papillary thyroid cancer patients. *Ann Surg Oncol.* 2018;25:2520–2525.
329. Adam MA, Pura J, Gu L, et al. Extent of surgery for papillary thyroid cancer is not associated with survival: an analysis of 61,775 patients. *Ann Surg.* 2014;260:601–605.
330. Rajjoub SR, Yan H, Calcaterra NA, et al. Thyroid lobectomy is not sufficient for T2 papillary thyroid cancers. *Surgery.* 2018;163:1134–1143.
331. Bilimoria KY, Bentrem DJ, Ko CY, et al. Extent of surgery affects survival for papillary thyroid cancer. *Ann Surg.* 2007;246:375–381.
332. Carhill AA, Litofsky DR, Ross DS, et al. Long-term outcomes following therapy in differentiated thyroid carcinoma: NTCTCS registry analysis 1987–2012. *J Clin Endocrinol Metab.* 2015;100:3270–3279.
333. Hay ID, Grant CS, Bergstrahl EJ, et al. Unilateral total lobectomy: is it sufficient surgical treatment for patients with AMES low-risk papillary thyroid carcinoma? *Surgery.* 1998;124:958–964.
334. Kim MJ, Lee MC, Lee GH, et al. Extent of surgery did not affect recurrence during 7-years follow-up in papillary thyroid cancer sized 1–4 cm: Preliminary results. *Clin Endocrinol (Oxf).* 2017;87:80–86.
335. Guo K, Wang Z. Risk factors influencing the recurrence of papillary thyroid carcinoma: a systematic review and meta-analysis. *Int J Clin Exp Pathol.* 2014;7:5393–5403.
336. Kluijfhout WP, Pasternak JD, Lim J, et al. Frequency of high-risk characteristics requiring total thyroidectomy for 1–4 cm well-differentiated thyroid cancer. *Thyroid.* 2016;26:820–824.
337. Hirshoren N, Kaganov K, Weinberger JM, et al. Thyroidectomy practice after implementation of the 2015 American Thyroid Association Guidelines on Surgical options for patients with well-differentiated thyroid carcinoma. *JAMA Otolaryngol Head Neck Surg.* 2018;144:427–432.
338. Abu-Ghanem S, Cohen O, Raz Yarkoni T, Fliss DM, Yehuda M. Intraoperative frozen section in “suspicious for papillary thyroid carcinoma” after adoption of the Bethesda system. *Otolaryngol Head Neck Surg.* 2016;155:779–786.
339. Nagarkatti SS, Faquin WC, Lubitz CC, et al. Management of thyroid nodules with atypical cytology on fine-needle aspiration biopsy. *Ann Surg Oncol.* 2013;20:60–65.
340. Cohen O, et al. Selection of atypia/follicular lesion of unknown significance patients for surgery versus active surveillance, without using genetic testing: a single institute experience, prospective analysis, and recommendations. *Thyroid.* 2017;27:928–935.
341. Coorough N, Hudak K, Jaume JC, et al. Nondiagnostic fine-needle aspirations of the thyroid: is the risk of malignancy higher? *J Surg Res.* 2013;184:746–750.
342. Eun NL, Yoo MR, Gweon HM, et al. Thyroid nodules with nondiagnostic results on repeat fine-needle aspiration biopsy: which nodules should be considered for repeat biopsy or surgery rather than follow-up? *Ultrasonography.* 2016;35:234–243.
343. Woo SH, Kim KH, Kim RB. Thyroid nodules with repeat nondiagnostic cytologic results: the role of clinical and ultrasonographic findings. *World J Surg.* 2015;39:1721–1727.
344. McHenry CR, Slusarczyk SJ, Khyami A. Recommendations for management of cystic thyroid disease. *Surgery.* 1999;126:1167–1171.
345. McGill JF, Sturgeon C, Angelos P. Metastatic struma ovarii treated with total thyroidectomy and radioiodine ablation. *Endocr Pract.* 2009;15:167–173.
346. Sosa JA, Bowman HM, Tielsch JM, Powe NR, Gordon TA, Udelsman R. The importance of surgeon experience for clinical and economic outcomes from thyroidectomy. *Ann Surg.* 1998;228:320–330.
347. Stavrakis AI, Ituarte PH, Ko CY, Yeh MW. Surgeon volume as a predictor of outcomes in inpatient and outpatient endocrine surgery. *Surgery.* 2007;142:887–899.
348. Kandil E, Noureldine SI, Abbas A, Tufano RP. The impact of surgical volume on patient outcomes following thyroid surgery. *Surgery.* 2013;154:1346–1352.
349. Adkisson CD, Howell GM, McCoy KL, et al. Surgeon volume and adequacy of thyroidectomy for differentiated thyroid cancer. *Surgery.* 2014;156:1453–1459.
350. Adam MA, Thomas S, Youngworth L, et al. Is there a minimum number of thyroidectomies a surgeon should perform to optimize patient outcomes? *Ann Surg.* 2017;265:402–407.
351. Nouraei SA, Virk JS, Middleton SE, et al. A national analysis of trends, outcomes and volume-outcome relationships in thyroid surgery. *Clin Otolaryngol.* 2017;42:354–365.
352. Hauch A, Al-Qurayshi Z, Randolph G, Kandil E. The importance of surgical volume on outcomes in thyroid surgery revisited: old is in again: editorial response to “what's old is new again” by Julie Ann Sosa (doi: 10.1245/s10434-014-3850-z). *Ann Surg Oncol.* 2014;21:3721–3722.
353. Hauch A, Al-Qurayshi Z, Randolph G, Kandil E. Total thyroidectomy is associated with increased risk of complications for low- and high-volume surgeons. *Ann Surg Oncol.* 2014;21:3844–3852.
354. Sabaretnam M, Mishra A, Chand G. Assessment of swallowing function impairment in patients with benign goiters and impact of thyroidectomy: a case control study. *World J Surg.* 2012;36:1293–1299.
355. Reiher AE, Mazeh H, Schaefer S, et al. Thyroidectomy decreases snoring and sleep apnea symptoms. *Thyroid.* 2012;22:1160–1164.
356. Palit TK, Miller CC 3rd, Miltenburg DM. The efficacy of thyroidectomy for Graves' disease: a meta-analysis. *J Surg Res.* 2000;90:161–165.
357. Liu ZW, Masterson L, Fish B, Jani P, Chatterjee K. Thyroid surgery for Graves' disease and Graves' ophthalmopathy. *Cochrane Database Syst Rev.* 2015;(11):CD010576.
358. Uruno T, Masaki C, Suzuki A, et al. Antimicrobial prophylaxis for the prevention of surgical site infection after thyroid and parathyroid surgery: a prospective randomized trial. *World J Surg.* 2015;39:1282–1287.
359. Dionigi G, Rovera F, Boni L, Castano P, Dionigi R. Surgical site infections after thyroidectomy. *Surg Infect (Larchmt).* 2006;7(suppl 2):S117–S120.
360. ASHP Therapeutic Guidelines on Antimicrobial Prophylaxis in Surgery. American Society of Health-System Pharmacists. *Am J Health Syst Pharm.* 1999;56:1839–1888.
361. Gentile I, Rosato L, Avenia N, et al. Do Italian surgeons use antibiotic prophylaxis in thyroid surgery? Results from a national study (UEC—Italian Endocrine Surgery Units Association). *Ann Ital Chir.* 2014;85:33–37.
362. Moalem J, Ruan DT, Farkas RL, et al. Patterns of antibiotic prophylaxis use for thyroidectomy and parathyroidectomy: results of an international survey of endocrine surgeons. *J Am Coll Surg.* 2010;210:949–956.

363. Elfenbein DM, Schneider DF, Chen H, Sippel RS. Surgical site infection after thyroidectomy: a rare but significant complication. *J Surg Res*. 2014;190:170–176.
364. Cheng SP, Liu TP, Yang PS, Lee KS, Liu CL. Effect of perioperative dexamethasone on subjective voice quality after thyroidectomy: a meta-analysis and systematic review. *Langenbecks Arch Surg*. 2015;400:929–936.
365. Tarantino I, Warschkow R, Beutner U, et al. Efficacy of a single preoperative dexamethasone dose to prevent nausea and vomiting after thyroidectomy (the IPONV study): a randomized, double-blind, placebo-controlled clinical trial. *Ann Surg*. 2015;262:934–940.
366. Wang JJ, Ho ST, Tzeng JJ, Tang CS. The effect of timing of dexamethasone administration on its efficacy as a prophylactic antiemetic for postoperative nausea and vomiting. *Anesth Analg*. 2000;91:136–139.
367. Lachanas VA, Exarchos S, Tsiouvakas S, et al. Does perioperative dexamethasone affect voice-related quality of life after thyroidectomy? *Eur Arch Otorhinolaryngol*. 2014;271:3073–3076.
368. Schietroma M, Cecilia EM, Carlei F, et al. Dexamethasone for the prevention of recurrent laryngeal nerve palsy and other complications after thyroid surgery: a randomized double-blind placebo-controlled trial. *JAMA Otolaryngol Head Neck Surg*. 2013;139:471–478.
369. Worni M, Schudel HH, Seifert E, et al. Randomized controlled trial on single dose steroid before thyroidectomy for benign disease to improve postoperative nausea, pain, and vocal function. *Ann Surg*. 2008;248:1060–1066.
370. Erbil Y, Giriş M, Salmaslioglu A, et al. The effect of anti-thyroid drug treatment duration on thyroid gland microvessel density and intraoperative blood loss in patients with Graves' disease. *Surgery*. 2008;143:216–225.
371. Erbil Y, Ozluk Y, Giriş M, et al. Effect of lugol solution on thyroid gland blood flow and microvessel density in the patients with Graves' disease. *J Clin Endocrinol Metab*. 2007;92:2182–2189.
372. Ansaldo GL, Pretolesi F, Varaldo E, et al. Doppler evaluation of intrathyroid arterial resistances during preoperative treatment with Lugol's iodide solution in patients with diffuse toxic goiter. *J Am Coll Surg*. 2000;191:607–612.
373. Yilmaz Y, Kamer KE, Ureyen O, Sari E, Acar T, Karahalli O. The effect of preoperative Lugol's iodine on intraoperative bleeding in patients with hyperthyroidism. *Ann Med Surg (Lond)*. 2016;9:53–57.
374. Shinall MC Jr, Broome JT, Baker A, Solorzano CC. Is potassium iodide solution necessary before total thyroidectomy for Graves disease? *Ann Surg Oncol*. 2013;20:2964–2967.
375. Simsir IY, Ozdemir M, Duman S, Erdogan M, Donmez A, Ozgen AG. Therapeutic plasmapheresis in thyrotoxic patients. *Endocrine*. 2018;62:144–148.
376. Schafer AL, Weaver CM, Black DM, et al. Intestinal calcium absorption decreases dramatically after gastric bypass surgery despite optimization of vitamin D Status. *J Bone Miner Res*. 2015;30:1377–1385.
377. Goldenberg D, Ferris RL, Shindo ML, et al. Thyroidectomy in patients who have undergone gastric bypass surgery. *Head Neck*. 2018;40:1237–1244.
378. Campos GM, Ziemelis M, Pappas R, Ahmed M, Davis DB. Laparoscopic reversal of Roux-en-Y gastric bypass: technique and utility for treatment of endocrine complications. *Surg Obes Relat Dis*. 2014;10:36–43.
379. Gooi Z, Ward BK, Mener DJ, Ozgursoy OB, Pai SI. A staged thyroidectomy approach for gastric bypass patients. *Laryngoscope*. 2015;125:1028–1030.
380. Roh JL, Park CI. Routine oral calcium and vitamin D supplements for prevention of hypocalcemia after total thyroidectomy. *Am J Surg*. 2006;192:675–678.
381. Tartaglia F, Giuliani A, Sgueglia M, Biancari F, Juvonen T, Campana FP. Randomized study on oral administration of calcitriol to prevent symptomatic hypocalcemia after total thyroidectomy. *Am J Surg*. 2005;190:424–429.
382. Oltmann SC, Brekke AV, Schneider DF, Schaefer SC, Chen H, Sippel RS. Preventing postoperative hypocalcemia in patients with Graves disease: a prospective study. *Ann Surg Oncol*. 2015;22:952–958.
383. Efade O, Antakia R, Laskar N, Uttley L, Balasubramanian SP. Systematic review and meta-analysis of predictors of post-thyroidectomy hypocalcemia. *Br J Surg*. 2014;101:307–320.
384. Alexander EK, Heering JP, Benson CB, et al. Assessment of nondiagnostic ultrasound-guided fine needle aspirations of thyroid nodules. *J Clin Endocrinol Metab*. 2002;87:4924–4927.
385. Alsaffar H, Wilson L, Kamdar DP, Sultanov F, Enepekides D, Higgins KM. Informed consent: do information pamphlets improve post-operative risk-recall in patients undergoing total thyroidectomy: prospective randomized control study. *J Otolaryngol Head Neck Surg*. 2016;45:14.
386. Falagas ME, Korbila IP, Giannopoulou KP, Kondilis BK, Peppas G. Informed consent: how much and what do patients understand? *Am J Surg*. 2009;198:420–435.
387. Jefford M, Moore R. Improvement of informed consent and the quality of consent documents. *Lancet Oncol*. 2008;9:485–493.
388. Angelos P, DaRosa DA, Bentram D, Sherman H. Residents seeking informed consent: Are they adequately knowledgeable? *Curr Surg*. 2002;59:115–118.
389. Roy M, Rajamanickam V, Chen H, Sippel R. Is DVT prophylaxis necessary for thyroidectomy and parathyroidectomy? *Surgery*. 2010;148:1163–1168.
390. Limongelli P, Tolone S, Gubitosi A. Relationship between postoperative venous thromboembolism and hemorrhage in patients undergoing total thyroidectomy without preoperative prophylaxis. *Int J Surg*. 2014;12(suppl 1):S198–S201.
391. Macht R, Gardner I, Talutis S, Rosenkranz P, Doherty G, McAneny D. Evaluation of a standardized risk-based venous thromboembolism prophylaxis protocol in the setting of thyroid and parathyroid surgery. *J Am Coll Surg*. 2017;224:1029–1035.
392. Pardo-Refoyo JL, Cuellar-Azcarate JJ, Santiago-Pena LF. Development of a checklist in risk management in thyroidectomy. *Endocrinol Nutr*. 2014;61:445–454.
393. Carty SE, Doherty GM, Inabnet WB, 3rd, et al. American Thyroid Association statement on the essential elements of interdisciplinary communication of perioperative information for patients undergoing thyroid cancer surgery. *Thyroid*. 2012;22:395–399.
394. Miller BS, Doherty GM. An examination of recently revised differentiated thyroid cancer guidelines. *Curr Opin Oncol*. 2011;23:1–6.
395. Zeuren R, Biagini A, Grewal RK, et al. RAI thyroid bed uptake after total thyroidectomy: a novel SPECT-CT anatomic classification system. *Laryngoscope*. 2015;125:2417–2424.
396. Molina G, Jiang W, Edmondson L, et al. Implementation of the surgical safety Checklist in South Carolina Hospitals is associated with improvement in perceived perioperative safety. *J Am Coll Surg*. 2016;222:725–736.
397. Haynes AB, Weiser TG, Berry WR, et al. A surgical safety checklist to reduce morbidity and mortality in a global population. *N Engl J Med*. 2009;360:491–499.
398. Lang BH, Ng SH, Wong KP. Pain and surgical outcomes with and without neck extension in standard open thyroidectomy: a prospective randomized trial. *Head Neck*. 2015;37:407–412.
399. Chiang FY, Lu IC, Kuo WR, Lee KW, Chang NC, Wu CW. The mechanism of recurrent laryngeal nerve injury during thyroid surgery—the application of intraoperative neuromonitoring. *Surgery*. 2008;143:743–749.
400. Dralle H, Sekulla C, Haerting J, et al. Risk factors of paralysis and functional outcome after recurrent laryngeal nerve monitoring in thyroid surgery. *Surgery*. 2004;136:1310–1322.
401. Portinari M, Carcoforo P. The application of drains in thyroid surgery. *Gland Surg*. 2017;6:563–573.
402. Tandon S, Shahab R, Benton JJ, Ghosh SK, Sheard J, Jones TM. Fine-needle aspiration cytology in a regional head and neck cancer center: comparison with a systematic review and meta-analysis. *Head Neck*. 2008;30:1246–1252.
403. Ha EJ, Baek JH, Lee JH, et al. Complications following US-guided core-needle biopsy for thyroid lesions: a retrospective study of 6,169 consecutive patients with 6,687 thyroid nodules. *Eur Radiol*. 2017;27:1186–1194.
404. Na DG, Kim JH, Sung JY, et al. Core-needle biopsy is more useful than repeat fine-needle aspiration in thyroid nodules read as nondiagnostic or atypia of undetermined significance by the Bethesda system for reporting thyroid cytopathology. *Thyroid*. 2012;22:468–475.
405. Novoa E, Gürtler N, Arnoux A, Kraft M. Role of ultrasound-guided core-needle biopsy in the assessment of head and neck lesions: a meta-analysis and systematic review of the literature. *Head Neck*. 2012;34:1497–1503.
406. Wolinski K, Stangierski A, Ruchala M. Comparison of diagnostic yield of core-needle and fine-needle aspiration biopsies of thyroid lesions: systematic review and meta-analysis. *Eur Radiol*. 2017;27:431–436.
407. Sharma A, et al. Presenting features of thyroid lymphoma: the mayo clinic experience. *Thyroid*. 2015;25:A197.
408. Ha EJ, Baek JH, Lee JH, et al. Core needle biopsy could reduce diagnostic surgery in patients with anaplastic thyroid cancer or thyroid lymphoma. *Eur Radiol*. 2016;26:1031–1036.
409. Swerdlow SH, CE, Harris NL, Jaffe ES, Pileri SA, Stein H, Thiele J, Vardiman JW, WHO Classification of Tumours of Haematopoietic and Lymphoid Tissues. 4 ed. Vol. 2. 2008, Lyon, France: IARC Press. 439.

410. Peng Y, Wang HH. A meta-analysis of comparing fine-needle aspiration and frozen section for evaluating thyroid nodules. *Diagnostic Cytopathol.* 2008;36:916–920.
411. Udelsman R, Westra WH, Donovan PI, et al. Randomized prospective evaluation of frozen-section analysis for follicular neoplasms of the thyroid. *Ann Surg.* 2001;233:716–722.
412. LiVolsi VA, Baloch ZW. Use and abuse of frozen section in the diagnosis of follicular thyroid lesions. *Endocr Pathol.* 2005;16:285–293.
413. Park YM, Wang SG, Goh JY, Shin DH, Kim IJ, Lee BJ. Intraoperative frozen section for the evaluation of extrathyroidal extension in papillary thyroid cancer. *World J Surg.* 2015;39:187–193.
414. Balasubramanian SP, Harrison BJ. Systematic review and meta-analysis of sentinel node biopsy in thyroid cancer. *Br J Surg.* 2011;98:334–344.
415. Westra WH, Pritchett DD, Udelsman R. Intraoperative confirmation of parathyroid tissue during parathyroid exploration: a retrospective evaluation of the frozen section. *Am J Surg Pathol.* 1998;22:538–544.
416. Bian XH, Li SJ, Zhou L, et al. Applicability of rapid intraoperative parathyroid hormone assay through fine needle aspiration to identify parathyroid tissue in thyroid surgery. *Exp Ther Med.* 2016;12:4072–4076.
417. Su HK, Wenig BM, Haser GC, et al. Inter-observer variation in the pathologic identification of minimal extrathyroidal extension in papillary thyroid carcinoma. *Thyroid.* 2016;26:512–517.
418. Du E, Wenig BM, Su HK, et al. Inter-observer variation in the pathologic identification of extranodal extension in nodal metastasis from papillary thyroid carcinoma. *Thyroid.* 2016;26:816–819.
419. Hamady ZZ, Mather N, Lansdown MR, Davidson L, MacLennan KA. Surgical pathological second opinion in thyroid malignancy: impact on patients' management and prognosis. *Eur J Surg Oncol.* 2005;31:74–77.
420. Baloch ZW, Livolsi VA. Follicular-patterned lesions of the thyroid: the bane of the pathologist. *Am J Clin Pathol.* 2002;117:143–150.
421. DeLellis, RA, Lloyd RV, Heitz PU, Eng C, eds. World Health Organization Classification of Tumours. Pathology and Genetics of Tumours of Endocrine Organs. 2004. IARC Press: Lyon, France.
422. Liu J, Singh B, Tallini G, et al. Follicular variant of papillary thyroid carcinoma: a clinicopathologic study of a problematic entity. *Cancer.* 2006;107:1255–1264.
423. Lang W, Georgii A, Stauch G, Kienzle E. The differentiation of atypical adenomas and encapsulated follicular carcinomas in the thyroid gland. *Virchows Arch A Pathol Anat Histol.* 1980;385:125–141.
424. Yamashina M. Follicular neoplasms of the thyroid. Total circumferential evaluation of the fibrous capsule. *Am J Surg Pathol.* 1992;16:392–400.
425. Kim HJ, Sung JY, Oh YL, et al. Association of vascular invasion with increased mortality in patients with minimally invasive follicular thyroid carcinoma but not widely invasive follicular thyroid carcinoma. *Head Neck.* 2014;36:1695–1700.
426. O'Neill CJ, Vaughan L, Learoyd DL, et al. Management of follicular thyroid carcinoma should be individualised based on degree of capsular and vascular invasion. *Eur J Surg Oncol.* 2011;37:181–185.
427. D'Avanzo A, Treseler P, Ituarte PH, et al. Follicular thyroid carcinoma: histology and prognosis. *Cancer.* 2004;100:1123–1129.
428. Podda M, Saba A, Porru F, Reccia I, Pisanu A. Follicular thyroid carcinoma: differences in clinical relevance between minimally invasive and widely invasive tumors. *World J Surg Oncol.* 2015;13:193.
429. Ito Y, Hirokawa M, Masuoka H, et al. Prognostic factors of minimally invasive follicular thyroid carcinoma: extensive vascular invasion significantly affects patient prognosis. *Endocr J.* 2013;60:637–642.
430. Máximo V, Soares P, Lima J, Cameselle-Teijeiro J, Sobrinho-Simões M. Mitochondrial DNA somatic mutations (point mutations and large deletions) and mitochondrial DNA variants in human thyroid pathology: a study with emphasis on Hurthle cell tumors. *Am J Pathol.* 2002;160:1857–1865.
431. Lloyd RV, Osamura RY, Klöppel G, Rosai J. *World Health Organization Classification of Tumours of Endocrine Organs.* 4th ed. Lyon: IARC; 2017.
432. Ríos A, Rodríguez JM, Ferri B, Matínez-Barba E, Febrero B, Parrilla P. Are prognostic scoring systems of value in patients with follicular thyroid carcinoma? *Eur J Endocrinol.* 2013;169:821–827.
433. D'Avanzo A, Ituarte P, Treseler P, et al. Prognostic scoring systems in patients with follicular thyroid cancer: a comparison of different staging systems in predicting the patient outcome. *Thyroid.* 2004;14:453–458.
434. Kushchayeva Y, Duh QY, Kebebew E, Clark OH. Prognostic indications for Hurthle cell cancer. *World J Surg.* 2004;28:1266–1270.
435. Ruegemer JJ, Hay ID, Bergstralh EJ, Ryan JJ, Offord KP, Gorman CA. Distant metastases in differentiated thyroid carcinoma: a multivariate analysis of prognostic variables. *J Clin Endocrinol Metab.* 1988;67:501–508.
436. Hundahl SA, Fleming ID, Fremgen AM, Menck HR. A National Cancer Data Base report on 53,856 cases of thyroid carcinoma treated in the U.S., 1985–1995 [see comments]. *Cancer.* 1998;83:2638–2648.
437. Amin MB and Edge SB. *AJCC cancer staging manual.* Eighth ed. New York: Springer; 2017.
438. Seethala RR, Asa SL, Carty SE, et al. Protocol for the Examination of Specimens From Patients With Carcinomas of the Thyroid Gland. <http://www.cap.org/ShowProperty?nodePath=/UCMCon/ContributionFolders/WebContent/pdf/cp-thyroid-16protocol-3200.pdf>. Accessed July 19, 2019.
439. Kahn C, Simonella L, Sywak M, Boyages S, Ung O, O'Connell D. Postsurgical pathology reporting of thyroid cancer in New South Wales, Australia. *Thyroid.* 2012;22:604–610.
440. Cancer Protocol Templates. Cancer Protocol Templates 2017. <http://www.cap.org/ShowProperty?nodePath=/UCMCon/ContributionFolders/WebContent/pdf/cp-thyroid-17protocol-4000.pdf>. Accessed July 19, 2019.
441. Mainthia R, Wachtel H, Chen Y, et al. Evaluating the projected surgical impact of reclassifying noninvasive encapsulated follicular variant of papillary thyroid cancer as noninvasive follicular thyroid neoplasm with papillary-like nuclear features. *Surgery.* 2018;163:60–65.
442. Alves VAF, Kakudo K, LiVolsi V, et al. Noninvasive follicular thyroid neoplasm with papillary-like nuclear features (NIFTP): achieving better agreement by refining diagnostic criteria. *Clinics (Sao Paulo).* 2018;73:e576.
443. Johnson DN, Furtado LV, Long BC, et al. Noninvasive follicular thyroid neoplasms with papillary-like nuclear features are genetically and biologically similar to adenomatous nodules and distinct from papillary thyroid carcinomas with extensive follicular growth. *Arch Pathol Lab Med.* 2018;142:838–850.
444. Chen J, Tward JD, Shrieve DC, Hitchcock YJ. Surgery and radiotherapy improves survival in patients with anaplastic thyroid carcinoma: analysis of the surveillance, epidemiology, and end results 1983–2002. *Am J Clin Oncol.* 2008;31:460–464.
445. McIver B, Hay ID, Giuffrida DF, et al. Anaplastic thyroid carcinoma: a 50-year experience at a single institution. *Surgery.* 2001;130:1028–1034.
446. Yoshida A, Kamma H, Asaga T, et al. Proliferative activity in thyroid tumors. *Cancer.* 1992;69:2548–2552.
447. Mete O, Asa SL. Precursor lesions of endocrine system neoplasms. *Pathology.* 2013;45:316–330.
448. Perry A, Molberg K, Albores-Saavedra J. Physiologic versus neoplastic C-cell hyperplasia of the thyroid: separation of distinct histologic and biologic entities. *Cancer.* 1996;77:750–756.
449. Phitayakorn R, Faquin W, Wei N, Barbesino G, Stephen AE. Thyroid-associated paragangliomas. *Thyroid.* 2011;21:725–733.
450. Moley JF, DeBenedetti MK. Patterns of nodal metastases in palpable medullary thyroid carcinoma: recommendations for extent of node dissection. *Ann Surg.* 1999;229:880–887.
451. Robinson TJ, Thomas S, Dinan MA, Roman S, Sosa JA, Hyslop T. How many lymph nodes are enough? assessing the adequacy of lymph node yield for papillary thyroid cancer. *J Clin Oncol.* 2016;34:3434–3439.
452. Randle RW, Balentine CJ, Levenson GE, et al. Trends in the presentation, treatment, and survival of patients with medullary thyroid cancer over the past 30 years. *Surgery.* 2017;161:137–146.
453. Kouvaraki MA, Lee JE, Shapiro SE, Sherman SI, Evans DB. Preventable reoperations for persistent and recurrent papillary thyroid carcinoma. *Surgery.* 2004;136:1183–1191.
454. Lee DW, Ji YB, Sung ES, et al. Roles of ultrasonography and computed tomography in the surgical management of cervical lymph node metastases in papillary thyroid carcinoma. *Eur J Surg Oncol.* 2013;39:191–196.
455. Stack BC Jr, Ferris RL, Goldenberg D, et al. American Thyroid Association consensus review and statement regarding the anatomy, terminology, and rationale for lateral neck dissection in differentiated thyroid cancer. *Thyroid.* 2012;22:501–508.
456. Fraser S, Zaidi N, Norlén O, et al. Incidence and risk factors for occult level 3 lymph node metastases in papillary thyroid cancer. *Ann Surg Oncol.* 2016;23:3587–3592.
457. Moo TA, Umunna B, Kato M, et al. Ipsilateral versus bilateral central neck lymph node dissection in papillary thyroid carcinoma. *Ann Surg.* 2009;250:403–408.

458. Chae BJ, Jung CK, Lim DJ, et al. Performing contralateral central lymph node dissection in papillary thyroid carcinoma: a decision approach. *Thyroid*. 2011;21:873–877.
459. Song CM, Lee DW, Ji YB, et al. Frequency and pattern of central lymph node metastasis in papillary carcinoma of the thyroid isthmus. *Head Neck*. 2016;38(suppl 1):E412–E416.
460. Scollo C, Baudin E, Travaglini JP, et al. Rationale for central and bilateral lymph node dissection in sporadic and hereditary medullary thyroid cancer. *J Clin Endocrinol Metab*. 2003;88:2070–2075.
461. Lang BH, Lee GC, Ng CP, et al. Evaluating the morbidity and efficacy of reoperative surgery in the central compartment for persistent/recurrent papillary thyroid carcinoma. *World J Surg*. 2013;37:2853–2859.
462. Khokhar MT, Day KM, Sangal RB, et al. Preoperative high-resolution ultrasound for the assessment of malignant central compartment lymph nodes in papillary thyroid cancer. *Thyroid*. 2015;25:1351–1354.
463. Moreno MA, Edeiken-Monroe BS, Siegel ER, et al. In papillary thyroid cancer, preoperative central neck ultrasound detects only macroscopic surgical disease, but negative findings predict excellent long-term regional control and survival. *Thyroid*. 2012;22:347–355.
464. Shen WT, Ogawa L, Ruan D, Suh I, Duh QY, Clark OH. Central neck lymph node dissection for papillary thyroid cancer: the reliability of surgeon judgment in predicting which patients will benefit. *Surgery*. 2010;148:398–403.
465. Mazzaferri EL, Doherty GM, Steward DL. The pros and cons of prophylactic central compartment lymph node dissection for papillary thyroid carcinoma. *Thyroid*. 2009;19:683–689.
466. Wang TS, Evans DB, Fareau GG, Carroll T, Yen TW. Effect of prophylactic central compartment neck dissection on serum thyroglobulin and recommendations for adjuvant radioactive iodine in patients with differentiated thyroid cancer. *Ann Surg Oncol*. 2012;19:4217–4222.
467. Wang TS, Cheung K, Farrokhyar F, Roman SA, Sosa JA. A meta-analysis of the effect of prophylactic central compartment neck dissection on locoregional recurrence rates in patients with papillary thyroid cancer. *Ann Surg Oncol*. 2013;20:3477–3483.
468. Zhao WJ, Luo H, Zhou YM, Dai WY, Zhu JQ. Evaluating the effectiveness of prophylactic central neck dissection with total thyroidectomy for cN0 papillary thyroid carcinoma: an updated meta-analysis. *Eur J Surg Oncol*. 2017;43:1989–2000.
469. Hall CM, Snyder SK, Maldonado YM, Lairmore TC. Routine central lymph node dissection with total thyroidectomy for papillary thyroid cancer potentially minimizes level VI recurrence. *Surgery*. 2016;160:1049–1058.
470. Hughes DT, Rosen JE, Evans DB, Grubbs E, Wang TS, Solórzano CC. Prophylactic central compartment neck dissection in papillary thyroid cancer and effect on locoregional recurrence. *Ann Surg Oncol*. 2018;25:2526–2534.
471. Viola D, Materazzi G, Valerio L, et al. Prophylactic central compartment lymph node dissection in papillary thyroid carcinoma: clinical implications derived from the first prospective randomized controlled single institution study. *J Clin Endocrinol Metab*. 2015;100:1316–1324.
472. Nixon IJ, Wang LY, Ganly I, et al. Outcomes for patients with papillary thyroid cancer who do not undergo prophylactic central neck dissection. *Br J Surg*. 2016;103:218–225.
473. Kim SK, Woo JW, Lee JH, et al. Prophylactic central neck dissection might not be necessary in papillary thyroid carcinoma: analysis of 11,569 cases from a single institution. *J Am Coll Surg*. 2016;222:853–864.
474. Tuttle RM, Haugen B, Perrier ND. Updated American Joint Committee on Cancer/Tumor-Node-Metastasis Staging System for Differentiated and Anaplastic Thyroid Cancer (Eighth Edition): what changed and why? *Thyroid*. 2017;27:751–756.
475. Tisell LE, Nilsson B, Mölne J, et al. Improved survival of patients with papillary thyroid cancer after surgical microdissection. *World J Surg*. 1996;20:854–859.
476. Dobrinja C, Troian M, Cipolat Mis T, et al. Rationality in prophylactic central neck dissection in clinically node-negative (cN0) papillary thyroid carcinoma: is there anything more to say? A decade experience in a single-center. *Int J Surg*. 2017;41(suppl 1):S40–S47.
477. Said M, Fujimoto M, Franken C, Woo S, Vuong B, Haigh PI. Preferential use of total thyroidectomy without prophylactic central lymph node dissection for early-stage papillary thyroid cancer: oncologic outcomes in an integrated health plan. *Perm J*. 2016;20:22–26.
478. Suman P, Wang CH, Abadian SS, Moo-Young TA, Prinz RA, Winchester DJ. Risk factors for central lymph node metastasis in papillary thyroid carcinoma: a National Cancer Data Base (NCDB) study. *Surgery*. 2016;159:31–39.
479. Sun W, Lan X, Zhang H, et al. Risk factors for central lymph node metastasis in CN0 papillary thyroid carcinoma: a systematic review and meta-analysis. *PLoS One*. 2015;10:e0139021.
480. Cabrera RN, Chone CT, Zantut-Wittmann D, et al. Value of sentinel lymph node biopsy in papillary thyroid cancer: initial results of a prospective trial. *Eur Arch Otorhinolaryngol*. 2015;272:971–979.
481. Iyer NG, Shaha AR, Ferlito A, et al. Delphian node metastasis in head and neck cancers—oracle or myth? *J Surg Oncol*. 2010;102:354–358.
482. Kim WW, Yang SI, Kim JH, Choi YS, Park YH, Kwon SK. Experience and analysis of Delphian lymph node metastasis in patients with papillary thyroid carcinoma. *World J Surg Oncol*. 2012;10:226.
483. Randolph GW, Duh QY, Heller KS, et al. The prognostic significance of nodal metastases from papillary thyroid carcinoma can be stratified based on the size and number of metastatic lymph nodes, as well as the presence of extranodal extension. *Thyroid*. 2012;22:1144–1152.
484. Javid M, Graham E, Malinowski J, et al. Dissection of levels II through V is required for optimal outcomes in patients with lateral neck lymph node metastasis from papillary thyroid carcinoma. *J Am Coll Surg*. 2016;222:1066–1073.
485. McNamara WF, Wang LY, Palmer FL, et al. Pattern of neck recurrence after lateral neck dissection for cervical metastases in papillary thyroid cancer. *Surgery*. 2016;159:1565–1571.
486. Welch K, McHenry CR. Selective lateral compartment neck dissection for thyroid cancer. *J Surg Res*. 2013;184:193–199.
487. Eskander A, Merdad M, Freeman JL, Witterick IJ. Pattern of spread to the lateral neck in metastatic well-differentiated thyroid cancer: a systematic review and meta-analysis. *Thyroid*. 2013;23:583–592.
488. Caron NR, Tan YY, Ogilvie JB, et al. Selective modified radical neck dissection for papillary thyroid cancer—is level I, II and V dissection always necessary? *World J Surg*. 2006;30:833–840.
489. Merdad M, Eskander A, Kroeker T, Freeman JL. Metastatic papillary thyroid cancer with lateral neck disease: pattern of spread by level. *Head Neck*. 2013;35:1439–1442.
490. Bardet S, Malville E, Rame JP, et al. Macroscopic lymph-node involvement and neck dissection predict lymph-node recurrence in papillary thyroid carcinoma. *Eur J Endocrinol*. 2008;158:551–560.
491. Sugitani I, Fujimoto Y, Yamada K, Yamamoto N. Prospective outcomes of selective lymph node dissection for papillary thyroid carcinoma based on preoperative ultrasonography. *World J Surg*. 2008;32:2494–2502.
492. Ito Y, Miyauchi A, Kudo T, Kihara M, Fukushima M, Miya A. The effectiveness of prophylactic modified neck dissection for reducing the development of lymph node recurrence of papillary thyroid carcinoma. *World J Surg*. 2017;41:2283–2289.
493. Tuttle RM, Ball DW, Byrd D, et al. Medullary carcinoma. *J Natl Compr Canc Netw*. 2010;8:512–530.
494. Glenn JA, Yen TW, Fareau GG, Carr AA, Evans DB, Wang TS. Institutional experience with lateral neck dissections for thyroid cancer. *Surgery*. 2015;158:972–978.
495. Polistena A, Monacelli M, Lucchini R, et al. Surgical morbidity of cervical lymphadenectomy for thyroid cancer: a retrospective cohort study over 25 years. *Int J Surg*. 2015;21:128–134.
496. McMullen C, Rocke D, Freeman J. Complications of bilateral neck dissection in thyroid cancer from a single high-volume center. *JAMA Otolaryngol Head Neck Surg*. 2017;143:376–381.
497. Delaney SW, Shi H, Shokrani A, Sinha UK. Management of chyle leak after head and neck surgery: review of current treatment strategies. *Int J Otolaryngol*. 2017;2017:8362874.
498. Mekel M, Stephen AE, Gaz RD, et al. Surgical drains can be safely avoided in lateral neck dissections for papillary thyroid cancer. *Am J Surg*. 2010;199:485–490.
499. Abboud B, Tannoury J, Sleilaty G, Daher R, Abadjian G, Ghorra C. Cervical neck dissection without drainage in papillary thyroid carcinoma. *J Laryngol Otol*. 2013;127:299–302.
500. Jain A, Singh SN, Singhal P, Sharma MP, Grover M. A prospective study on the role of octreotide in management of chyle fistula neck. *Laryngoscope*. 2015;125:1624–1627.
501. Merki V, Pichler J, Giger R, Mantokoudis G. Chylothorax in thyroid surgery: a very rare case and systematic review of the literature. *J Otolaryngol Head Neck Surg*. 2016;45:52.
502. Wang LY, Palmer FL, Nixon IJ, et al. Lateral neck lymph node characteristics prognostic of outcome in patients with clinically evident N1b papillary thyroid cancer. *Ann Surg Oncol*. 2015;22:3530–3536.
503. Lango M, Flieder D, Arrangoiz R, et al. Extranodal extension of metastatic papillary thyroid carcinoma: correlation with biochemical endpoints, nodal

- persistence, and systemic disease progression. *Thyroid*. 2013;23:1099–1105.
504. Suh S, Pak K, Seok JW, Kim IJ. Prognostic value of extranodal extension in thyroid cancer: a meta-analysis. *Yonsei Med J*. 2016;57:1324–1328.
  505. Sugitani I, Kasai N, Fujimoto Y, Yanagisawa A. A novel classification system for patients with PTC: addition of the new variables of large (3 cm or greater) nodal metastases and reclassification during the follow-up period. *Surgery*. 2004;135:139–148.
  506. Zaydfudim V, Feurer ID, Griffin MR, Phay JE. The impact of lymph node involvement on survival in patients with papillary and follicular thyroid carcinoma. *Surgery*. 2008;144:1070–1077.
  507. Adam MA, Pura J, Goffredo P, et al. Presence and number of lymph node metastases are associated with compromised survival for patients younger than age 45 years with papillary thyroid cancer. *J Clin Oncol*. 2015;33:2370–2375.
  508. Esfandiari NH, Hughes DT, Yin H, Banerjee M, Haymart MR. The effect of extent of surgery and number of lymph node metastases on overall survival in patients with medullary thyroid cancer. *J Clin Endocrinol Metab*. 2014;99:448–454.
  509. Hughes DT, Laird AM, Miller BS, Gauger PG, Doherty GM. Reoperative lymph node dissection for recurrent papillary thyroid cancer and effect on serum thyroglobulin. *Ann Surg Oncol*. 2012;19:2951–2957.
  510. Al-Saif O, Farrar WB, Bloomston M, Porter K, Ringel MD, Kloos RT. Long-term efficacy of lymph node reoperation for persistent papillary thyroid cancer. *J Clin Endocrinol Metab*. 2010;95:2187–2194.
  511. Robenshtok E, Fish S, Bach A, Domínguez JM, Shaha A, Tuttle RM. Suspicious cervical lymph nodes detected after thyroidectomy for papillary thyroid cancer usually remain stable over years in properly selected patients. *J Clin Endocrinol Metab*. 2012;97:2706–2713.
  512. Hay ID, Lee RA, Davidge-Pitts C, Reading CC, Charboneau JW. Long-term outcome of ultrasound-guided percutaneous ethanol ablation of selected “recurrent” neck nodal metastases in 25 patients with TNM stages III or IVA papillary thyroid carcinoma previously treated by surgery and 1311 therapy. *Surgery*. 2013;154:1448–1454.
  513. Heilo A, Sigstad E, Fagerlid KH, et al. Efficacy of ultrasound-guided percutaneous ethanol injection treatment in patients with a limited number of metastatic cervical lymph nodes from papillary thyroid carcinoma. *J Clin Endocrinol Metab*. 2011;96:2750–2755.
  514. Tufano RP, Clayman G, Heller KS, et al. Management of recurrent/persistent nodal disease in patients with differentiated thyroid cancer: a critical review of the risks and benefits of surgical intervention versus active surveillance. *Thyroid*. 2015;25:15–27.
  515. Wagner B, Begic-Karup S, Raber W, Schneider B, Waldhäusl W, Vierhapper H. Prevalence of primary hyperparathyroidism in 13387 patients with thyroid diseases, newly diagnosed by screening of serum calcium. *Exp Clin Endocrinol Diabetes*. 1999;107:457–461.
  516. Del Rio P, Arcuri MF, Bezer L, Cataldo S, Robuschi G, Sianesi M. Association between primary hyperparathyroidism and thyroid disease. Role of preoperative PTH. *Ann Ital Chir*. 2009;80:435–438.
  517. Zanooco K, Angelos P, Sturgeon C. Cost-effectiveness analysis of parathyroidectomy for asymptomatic primary hyperparathyroidism. *Surgery*. 2006;140:874–881.
  518. Zanooco K, Heller M, Sturgeon C. Cost-effectiveness of parathyroidectomy for primary hyperparathyroidism. *Endocr Pract*. 2011;17(suppl 1):69–74.
  519. Zanooco K, Sturgeon C. How should age at diagnosis impact treatment strategy in asymptomatic primary hyperparathyroidism? A cost-effectiveness analysis. *Surgery*. 2008;144:290–298.
  520. Elliott DD, Monroe DP, Perrier ND. Parathyroid histopathology: is it of any value today? *J Am Coll Surg*. 2006;203:758–765.
  521. Agrawal K, Esmail AA, Gnanasegaran G, Navalkisoor S, Mittal BR, Fogelman I. Pitfalls and limitations of radionuclide imaging in endocrinology. *Semin Nucl Med*. 2015;45:440–457.
  522. Barbaros U, Erbil Y, Salmashoğlu A, et al. The characteristics of concomitant thyroid nodules cause false-positive ultrasonography results in primary hyperparathyroidism. *Am J Otolaryngol*. 2009;30:239–243.
  523. Chang MC, Tsai SC, Lin WY. Dual-phase 99mTc-MIBI parathyroid imaging reveals synchronous parathyroid adenoma and papillary thyroid carcinoma: a case report. *Kaohsiung J Med Sci*. 2008;24:542–547.
  524. Monroe DP, Edeiken-Monroe BS, Lee JE, Evans DB, Perrier ND. Impact of preoperative thyroid ultrasonography on the surgical management of primary hyperparathyroidism. *Br J Surg*. 2008;95:957–960.
  525. Sippel RS, Ozgöl O, Hartig GK, Mack EA, Chen H. Risks and consequences of incidental parathyroidectomy during thyroid resection. *ANZ J Surg*. 2007;77:33–36.
  526. Hone RW, Tikka T, Kaleva AI, et al. Analysis of the incidence and factors predictive of inadvertent parathyroidectomy during thyroid surgery. *J Laryngol Otol*. 2016;130:669–673.
  527. Lin YS, Hsueh C, Wu HY, Yu MC, Chao TC. Incidental parathyroidectomy during thyroidectomy increases the risk of postoperative hypocalcemia. *Laryngoscope*. 2017;127:2194–2200.
  528. Strichartz SD, Giuliano AE. The operative management of coexisting thyroid and parathyroid disease. *Arch Surg*. 1990;125:1327–1331.
  529. Hellstrom J. Primary hyperparathyroidism; observations in a series of 50 cases. *Acta Endocrinol (Copenh)*. 1954;16:30–58.
  530. Kissin M, Bakst H. Co-existing myxedema and hyperparathyroidism; case report. *J Clin Endocrinol Metab*. 1947;7:152–158.
  531. Ogburn PL, Black BM. Primary hyperparathyroidism and papillary adenocarcinoma of the thyroid; report of four cases. *Proc Staff Meet Mayo Clin*. 1956;31:295–298.
  532. Sitges-Serra A, Gallego-Otaegui L, Suárez S, Lorente-Poch L, Munné A, Sancho JJ. Inadvertent parathyroidectomy during total thyroidectomy and central neck dissection for papillary thyroid carcinoma. *Surgery*. 2017;161:712–719.
  533. Applewhite MK, White MG, Xiong M, et al. Incidence, risk factors, and clinical outcomes of incidental parathyroidectomy during thyroid surgery. *Ann Surg Oncol*. 2016;23:4310–4315.
  534. Zhou HY, He JC, McHenry CR. Inadvertent parathyroidectomy: incidence, risk factors, and outcomes. *J Surg Res*. 2016;205:70–75.
  535. Goodman A, Politz D, Lopez J, Norman J. Intrathyroid parathyroid adenoma: incidence and location—the case against thyroid lobectomy. *Otolaryngol Head Neck Surg*. 2011;144:867–871.
  536. Herden U, Seiler CA, Candinas D, Schmid SW. Intrathyroid adenomas in primary hyperparathyroidism: are they frequent enough to guide surgical strategy? *Surg Innov*. 2011;18:373–378.
  537. Miani C, Bracale AM, Bresadola V, Motz E. Concomitant primary hyperparathyroidism, Graves’ disease and vitamin D deficiency. *Acta Otorhinolaryngol Ital*. 2003;23:199–202.
  538. Riss P, Kammer M, Selberherr A, Scheuba C, Niederle B. Morbidity associated with concomitant thyroid surgery in patients with primary hyperparathyroidism. *Ann Surg Oncol*. 2015;22:2707–2713.
  539. Bilezikian JP, Brandi ML, Eastell R, et al. Guidelines for the management of asymptomatic primary hyperparathyroidism: summary statement from the Fourth International Workshop. *J Clin Endocrinol Metab*. 2014;99:3561–3569.
  540. Kiernan CM, Schlegel C, Kavalukas S, Isom C, Peters MF, Solórzano CC. Does concomitant thyroidectomy increase risks of parathyroidectomy? *J Surg Res*. 2016;203:34–39.
  541. Abboud B, Sleilaty G, Braidy C, et al. Enlarged parathyroid glands discovered in normocalcemic patients during thyroid surgery. *Am J Surg*. 2008;195:30–33.
  542. Abboud B, Sleilaty G, Mansour E, et al. Prevalence and risk factors for primary hyperparathyroidism in hyperthyroid patients. *Head Neck*. 2006;28:420–426.
  543. Arem R, Lim-Abraham MA, Mallette LE, et al. Graves’ disease and primary hyperparathyroidism. Influence of hyperthyroidism on serum calcium and parathyroid hormone. *Am J Med*. 1986;80:693–698.
  544. Hundley JC, Woodrum DT, Saunders BD, Doherty GM, Gauger PG. Revisiting lithium-associated hyperparathyroidism in the era of intraoperative parathyroid hormone monitoring. *Surgery*. 2005;138:1027–1031.
  545. Saunders BD, Saunders EF, Gauger PG. Lithium therapy and hyperparathyroidism: an evidence-based assessment. *World J Surg*. 2009;33:2314–2323.
  546. Meehan AD, Humble MB, Yazarloo P, Järhult J, Wallin G. The prevalence of lithium-associated hyperparathyroidism in a large Swedish population attending psychiatric outpatient units. *J Clin Psychopharmacol*. 2015;35:279–285.
  547. Ibrahim Y, Mohamed SE, Deniwar A, Al-Qurayshi ZH, Kandil E. Lithium-associated hyperparathyroidism: a pooled analysis. *ORL J Otorhinolaryngol Relat Spec*. 2015;77:273–280.
  548. Marti JL, Yang CS, Carling T, et al. Surgical approach and outcomes in patients with lithium-associated hyperparathyroidism. *Ann Surg Oncol*. 2012;19:3465–3471.
  549. Wade TJ, Yen TW, Amin AL, et al. Focused parathyroidectomy with intraoperative parathyroid hormone monitoring in patients with lithium-associated primary hyperparathyroidism. *Surgery*. 2013;153:718–722.
  550. Akerstrom G, Stalberg P. Surgical management of MEN-1 and -2: state of the art. *Surg Clin North Am*. 2009;89:1047–1068.

551. Brandi ML, Gagel RF, Angeli A, et al. Guidelines for diagnosis and therapy of MEN type 1 and type 2. *J Clin Endocrinol Metab*. 2001;86:5658–5671.
552. American Thyroid Association Guidelines Task Force, Kloos RT, Eng C, et al. Medullary thyroid cancer: management guidelines of the American Thyroid Association. *Thyroid*. 2009;19:565–612.
553. Vaidya B, Pearce SH. Diagnosis and management of thyrotoxicosis. *BMJ*. 2014;349:g5128.
554. Samarasinghe S, Meah F, Singh V, et al. Biotin interference with routine clinical immunoassays: understand the causes and mitigate the risks. *Endocr Pract*. 2017;23:989–998.
555. Snyder S, Govednik C, Lairmore T, et al. Total thyroidectomy as primary definitive treatment for Graves' hyperthyroidism. *Am Surg*. 2013;79:1283–1288.
556. Genovese BM, Noureldine SI, Gleeson EM, et al. What is the best definitive treatment for Graves' disease? A systematic review of the existing literature. *Ann Surg Oncol*. 2013;20:660–667.
557. Rivkees SA. 63 years and 715 days to the "boxed warning": unmasking of the propylthiouracil problem. *Int J Pediatr Endocrinol*. 2010;2010:658267.
558. Huang SM, Liao WT, Lin CF, et al. Effectiveness and mechanism of preoperative lugol solution for reducing thyroid blood flow in patients with euthyroid Graves' Disease. *World J Surg*. 2016;40:505–509.
559. Whalen G, Sullivan M, Maranda L, Quinlan R, Larkin A. Randomized trial of a short course of preoperative potassium iodide in patients undergoing thyroidectomy for Graves' disease. *Am J Surg*. 2017;213:805–809.
560. Zanocco K, Heller M, Elaraj D, Sturgeon C. Is subtotal thyroidectomy a cost-effective treatment for Graves disease? A cost-effectiveness analysis of the medical and surgical treatment options. *Surgery*. 2012;152:164–172.
561. Donovan PJ, McLeod DS, Little R, Gordon L. Cost-utility analysis comparing radioactive iodine, anti-thyroid drugs and total thyroidectomy for primary treatment of Graves' disease. *Eur J Endocrinol*. 2016;175:595–603.
562. Burch HB, Cooper DS. Management of Graves disease: a review. *JAMA*. 2015;314:2544–2554.
563. Hookham J, Truran P, Allahabadia A, Balasubramanian SP. Patients' perceptions and views of surgery and radioiodine ablation in the definitive management of Graves' disease. *Postgrad Med J*. 2017;93:266–270.
564. Maia AL, Scheffel RS, Meyer EL, et al. The Brazilian consensus for the diagnosis and treatment of hyperthyroidism: recommendations by the Thyroid Department of the Brazilian Society of Endocrinology and Metabolism. *Arq Bras Endocrinol Metabol*. 2013;57:205–232.
565. Negro R, Attanasio R, Grimaldi F, et al. A 2015 Italian survey of clinical practice patterns in the management of Graves' disease: comparison with European and North American Surveys. *Eur Thyroid J*. 2016;5:112–119.
566. Sundaresh V, Brito JP, Wang Z, et al. Comparative effectiveness of therapies for Graves' hyperthyroidism: a systematic review and network meta-analysis. *J Clin Endocrinol Metab*. 2013;98:3671–3677.
567. Sundaresh V, Brito JP, Thapa P, Bahn RS, Stan MN. Comparative effectiveness of treatment choices for Graves' hyperthyroidism: a historical cohort study. *Thyroid*. 2017;27:497–505.
568. Happel C, Korkusuz H, Kranert WT, Grünwald F. Combination of ultrasound guided percutaneous microwave ablation and radioiodine therapy for treatment of hyper- and hypofunctioning thyroid nodules. *Nuklearmedizin*. 2014;53:N48–N49.
569. Bojic T, Paunovic I, Diklic A, et al. Total thyroidectomy as a method of choice in the treatment of Graves' disease—analysis of 1432 patients. *BMC Surg*. 2015;15:39.
570. Liu J, Sun W, Dong W, et al. Risk factors for post-thyroidectomy haemorrhage: a meta-analysis. *Eur J Endocrinol*. 2017;176:591–602.
571. Phitayakorn R, Morales-Garcia D, Wanderer J, et al. Surgery for Graves' disease: a 25-year perspective. *Am J Surg*. 2013;206:669–673.
572. Quérat C, Germain N, Dumollard JM, Estour B, Peoc'h M, Prades JM. Surgical management of hyperthyroidism. *Eur Ann Otorhinolaryngol Head Neck Dis*. 2015;132:63–66.
573. Yamanouchi K, Minami S, Hayashida N, Sakimura C, Kuroki T, Eguchi S. Predictive factors for intraoperative excessive bleeding in Graves' disease. *Asian J Surg*. 2015;38:1–5.
574. Yamanouchi K, Minami S, Kuba S, et al. Evaluation of the operative methods for Graves' disease. *Minerva Chir*. 2015;70:77–81.
575. Pierret C, Tourtier JP, Pons Y, Merat S, Duverger V, Perrier E. Total thyroidectomy for amiodarone-associated thyrotoxicosis: should surgery always be delayed for pre-operative medical preparation? *J Laryngol Otol*. 2012;126:701–705.
576. Huang CJ, Tseng CL, Chu CH, Huang DF, Huang CC, Lin LY. Adherence to guidelines in monitoring amiodarone-induced thyroid dysfunction. *J Eval Clin Pract*. 2017;23:108–113.
577. McManus C, Luo J, Sippel R, Chen H. Is thyroidectomy in patients with Hashimoto thyroiditis more risky? *J Surg Res*. 2012;178:529–532.
578. Shih ML, Lee JA, Hsieh CB, et al. Thyroidectomy for Hashimoto's thyroiditis: complications and associated cancers. *Thyroid*. 2008;18:729–734.
579. Liu J, Bargren A, Schaefer S, Chen H, Sippel RS. Total thyroidectomy: a safe and effective treatment for Graves' disease. *J Surg Res*. 2011;168:1–4.
580. Guo Z, Yu P, Liu Z, Si Y, Jin M. Total thyroidectomy vs bilateral subtotal thyroidectomy in patients with Graves' diseases: a meta-analysis of randomized clinical trials. *Clin Endocrinol (Oxf)*. 2013;79:739–746.
581. Tezelman S, Borucu I, Senyurek Giles Y, Tunca F, Terzioglu T. The change in surgical practice from subtotal to near-total or total thyroidectomy in the treatment of patients with benign multinodular goiter. *World J Surg*. 2009;33:400–405.
582. Kus LH, Hopman WM, Witterick IJ, Freeman JL. Quality-of-life outcomes in Graves disease patients after total thyroidectomy. *Ear Nose Throat J*. 2017;96:E8–E15.
583. Piga M, Serra A, Boi F, Tanda ML, Martino E, Mariotti S. Amiodarone-induced thyrotoxicosis. A review. *Minerva Endocrinol*. 2008;33:213–228.
584. Houghton SG, Farley DR, Brennan MD, van Heerden JA, Thompson GB, Grant CS. Surgical management of amiodarone-associated thyrotoxicosis: Mayo Clinic experience. *World J Surg*. 2004;28:1083–1087.
585. Kaderli RM, Fahrner R, Christ ER, et al. Total thyroidectomy for amiodarone-induced thyrotoxicosis in the hyperthyroid state. *Exp Clin Endocrinol Diabetes*. 2016;124:45–48.
586. Lorberboym M, Schachter P. Drug-induced thyrotoxicosis: the surgical option. *Isr Med Assoc J*. 2007;9:79–82.
587. Franzese CB, Fan CY, Stack BC Jr. Surgical management of amiodarone-induced thyrotoxicosis. *Otolaryngol Head Neck Surg*. 2003;129:565–570.
588. Williams M, Lo Gerfo P. Thyroidectomy using local anesthesia in critically ill patients with amiodarone-induced thyrotoxicosis: a review and description of the technique. *Thyroid*. 2002;12:523–525.
589. Perumal B, Meyer DR. Treatment of severe thyroid eye disease: a survey of the American Society of Ophthalmic Plastic and Reconstructive Surgery (ASOPRS). *Ophthal Plast Reconstr Surg*. 2015;31:127–131.
590. Smith TJ, Hegedus L. Graves' disease. *N Engl J Med*. 2016;375:1552–1565.
591. Bartalena L, Baldeschi L, Dickinson AJ, et al. Consensus statement of the European group on Graves' orbitopathy (EUGOGO) on management of Graves' orbitopathy. *Thyroid*. 2008;18:333–346.
592. Mourits MP, Koornneef L, Wiersinga WM, Prummel MF, Berghout A, van der Gaag R. Clinical criteria for the assessment of disease activity in Graves' ophthalmopathy: a novel approach. *Br J Ophthalmol*. 1989;73:639–644.
593. Mourits MP, Prummel MF, Wiersinga WM, Koornneef L. Clinical activity score as a guide in the management of patients with Graves' ophthalmopathy. *Clin Endocrinol (Oxf)*. 1997;47:9–14.
594. Wakelkamp IM, Baldeschi L, Saed P, Mourits MP, Prummel MF, Wiersinga WM. Surgical or medical decompression as a first-line treatment of optic neuropathy in Graves' ophthalmopathy? A randomized controlled trial. *Clin Endocrinol (Oxf)*. 2005;63:323–328.
595. Stein JD, Childers D, Gupta S, et al. Risk factors for developing thyroid-associated ophthalmopathy among individuals with Graves disease. *JAMA Ophthalmol*. 2015;133:290–296.
596. Abe Y, Sato H, Noguchi M, et al. Effect of subtotal thyroidectomy on natural history of ophthalmopathy in Graves' disease. *World J Surg*. 1998;22:714–717.
597. Youngwirth LM, Adam MA, Scheri RP, Roman SA, Sosa JA. Patients treated at low-volume centers have higher rates of incomplete resection and compromised outcomes: analysis of 31,129 patients with papillary thyroid cancer. *Ann Surg Oncol*. 2016;23:403–409.
598. Campbell MJ, McCoy KL, Shen WT, et al. A multi-institutional international study of risk factors for hematoma after thyroidectomy. *Surgery*. 2013;154:1283–1289.
599. Quimby AE, McCoy KL, Shen Wells ST, Hearn M, Javidnia H, Johnson-Obaseki S. Is there a group of patients at greater risk for hematoma following thyroidectomy? A systematic review and meta-analysis. *Laryngoscope*. 2017;127:1483–1490.
600. Marcinkowska M, Sniecikowska B, Zygmunt A, Brzezinski J, Dedejusz M, Lewinski A. Postoperative hypoparathyroidism in patients after total thyroidectomy—retrospective analysis. *Neuro Endocrinol Lett*. 2017;38:488–494.

601. Miah MS, Mahendran S, Mak C, Leese G, Smith D. Pre-operative serum alkaline phosphatase as a predictive indicator of post-operative hypocalcaemia in patients undergoing total thyroidectomy. *J Laryngol Otol*. 2015;129:1128–1132.
602. Burnett HF, Mabry CD, Westbrook KC. Hypocalcemia after thyroidectomy: mechanisms and management. *South Med J*. 1977;70:1045–1048.
603. See AC, Soo KC. Hypocalcaemia following thyroidectomy for thyrotoxicosis. *Br J Surg*. 1997;84:95–97.
604. Velentzas C, Oreopoulos DG. Thyrotoxic osteodystrophy: a perplexing type of metabolic bone disease. *Clin Invest Med*. 1978;1:53–55.
605. Wilkin TJ, Isles TE, Paterson CR, Crooks J, Beck J. Post-thyroidectomy hypocalcaemia: a feature of the operation or the thyroid disorder? *Lancet*. 1977;1:621–623.
606. Bisbocci D, Gallo V, Damiano P, et al. Spontaneous release of interleukin 1 beta from human blood monocytes in thyrotoxic osteodystrophy. *J Endocrinol Invest*. 1996;19:511–515.
607. Vidal-Trecan GM, Stahl JE, Eckman MH. Radioiodine or surgery for toxic thyroid adenoma: dissecting an important decision. A cost-effectiveness analysis. *Thyroid*. 2004;14:933–945.
608. Schabram J, Vorlander C, Wahl RA. Differentiated operative strategy in minimally invasive, video-assisted thyroid surgery results in 196 patients. *World J Surg*. 2004;28:1282–1286.
609. van Soestbergen MJ, van der Vijver JC, Graafland AD. Recurrence of hyperthyroidism in multinodular goiter after long-term drug therapy: a comparison with Graves' disease. *J Endocrinol Invest*. 1992;15:797–800.
610. Chiang FY, Lin JC, Wu CW, et al. Morbidity after total thyroidectomy for benign thyroid disease: comparison of Graves' disease and non-Graves' disease. *Kaohsiung J Med Sci*. 2006;22:554–559.
611. Enomoto K, Uchino S, Watanabe S, Enomoto Y, Noguchi S. Recurrent laryngeal nerve palsy during surgery for benign thyroid diseases: risk factors and outcome analysis. *Surgery*. 2014;155:522–528.
612. Joliat GR, Guarnero V, Demartines N, Schweizer V, Matter M. Recurrent laryngeal nerve injury after thyroid and parathyroid surgery: Incidence and postoperative evolution assessment. *Medicine (Baltimore)*. 2017;96:e6674.
613. Welch KC, McHenry CR. Total thyroidectomy: is morbidity higher for Graves' disease than nontoxic goiter? *J Surg Res*. 2011;170:96–99.
614. Akamizu T. Thyroid storm: A Japanese perspective. *Thyroid*. 2018;28:32–40.
615. Angell TE, Lechner MG, Nguyen CT, Salvato VL, Nicoloff JT, LoPresti JS. Clinical features and hospital outcomes in thyroid storm: a retrospective cohort study. *J Clin Endocrinol Metab*. 2015;100:451–459.
616. Bacuzzi A, Dionigi G, Guzzetti L, De Martino AI, Severgnini P, Cuffari S. Predictive features associated with thyrotoxic storm and management. *Gland Surg*. 2017;6:546–551.
617. Chiha M, Samarasinghe S, Kabaker AS. Thyroid storm: an updated review. *J Intensive Care Med*. 2015;30:131–140.
618. Ono Y, Ono S, Yasunaga H, Matsui H, Fushimi K, Tanaka Y. Factors associated with mortality of thyroid storm: analysis using a National Inpatient Database in Japan. *Medicine (Baltimore)*. 2016;95:e2848.
619. Satoh T, Isozaki O, Suzuki A, et al. 2016 Guidelines for the management of thyroid storm from The Japan Thyroid Association and Japan Endocrine Society (First edition). *Endocr J*. 2016;63:1025–1064.
620. Strowd SM, Majewski MB, Asteris J. Malignant hyperthermia versus thyroid storm in a patient with symptomatic Graves Disease: a case report. *A A Case Rep*. 2018;10: 97–99.
621. Rosenberg H, Pollock N, Schiemann A, Bulger T, Stowell K. Malignant hyperthermia: a review. *Orphanet J Rare Dis*. 2015;10:93.
622. Cooper DS, Laurberg P. Hyperthyroidism in pregnancy. *Lancet Diabetes Endocrinol*. 2013;1:238–249.
623. Andersen SL, Lönn S, Vestergaard P, Törring O. Birth defects after use of antithyroid drugs in early pregnancy: a Swedish nationwide study. *Eur J Endocrinol*. 2017;177:369–378.
624. Andersen SL, Olsen J, Wu CS, Laurberg P. Birth defects after early pregnancy use of antithyroid drugs: a Danish nationwide study. *J Clin Endocrinol Metab*. 2013;98:4373–4381.
625. Laurberg P, Andersen SL. Graves'-Basedow disease in pregnancy. New trends in the management and guidance to reduce the risk of birth defects caused by antithyroid drugs. *Nuklearmedizin*. 2015;54:106–111.
626. Laurberg P, Andersen SL. Antithyroid drug use in pregnancy and birth defects: why some studies find clear associations, and some studies report none. *Thyroid*. 2015;25:1185–1190.
627. Milham S Jr. Scalp defects in infants of mothers treated for hyperthyroidism with methimazole or carbimazole during pregnancy. *Teratology*. 1985;32:321.
628. Wolf D, Foulds N, Daya H. Antenatal carbimazole and choanal atresia: a new embryopathy. *Arch Otolaryngol Head Neck Surg*. 2006;132:1009–1011.
629. Yoshihara A, Noh J, Yamaguchi T, et al. Treatment of graves' disease with antithyroid drugs in the first trimester of pregnancy and the prevalence of congenital malformation. *J Clin Endocrinol Metab*. 2012;97:2396–2403.
630. Yoshihara A, Noh JY, Watanabe N, et al. Substituting potassium iodide for methimazole as the treatment for Graves' disease during the first trimester may reduce the incidence of congenital anomalies: a retrospective study at a single medical institution in Japan. *Thyroid*. 2015;25:1155–1161.
631. Jenkins TM, Mackey SF, Benzoni EM, Tolosa JE, Sciscione AC. Non-obstetric surgery during gestation: risk factors for lower birthweight. *Aust N Z J Obstet Gynaecol*. 2003;43:27–31.
632. Kuy S, Roman SA, Desai R, Sosa JA. Outcomes following thyroid and parathyroid surgery in pregnant women. *Arch Surg*. 2009;144:399–406.
633. ACOG Committee Opinion No. 474: nonobstetric surgery during pregnancy. *Obstet Gynecol* 2011; 117(2 pt 1): 420–1.
634. Alamdari S, Azizi F, Delshad H, Sarvghadi F, Amouzegar A, Mehran L. Management of hyperthyroidism in pregnancy: comparison of recommendations of american thyroid association and endocrine society. *J Thyroid Res*. 2013;2013:878467.
635. Alexander EK, Pearce EN, Brent GA, et al. 2017 Guidelines of the American Thyroid Association for the diagnosis and management of thyroid disease during pregnancy and the postpartum. *Thyroid*. 2017;27:315–389.
636. De Groot L, Abalovich M, Alexander EK, et al. Management of thyroid dysfunction during pregnancy and postpartum: an Endocrine Society clinical practice guideline. *J Clin Endocrinol Metab*. 2012;97:2543–2565.
637. Hamilton NT, Paterson PJ, Bredahl HD. Thyroidectomy during pregnancy. *Med J Aust*. 1968;1:431–433.
638. Cohen-Kerem R, Railton C, Oren D, Lishner M, Koren G. Pregnancy outcome following non-obstetric surgical intervention. *Am J Surg*. 2005;190:467–473.
639. Weingold AB. Appendicitis in pregnancy. *Clin Obstet Gynecol*. 1983;26:801–809.
640. Polak M, Luton D. Fetal thyroidology. *Best Pract Res Clin Endocrinol Metab*. 2014;28:161–173.
641. Ferianec V, Papcun P, Grochal F, Schenková K, Bártošová M. Prenatal diagnosis and successful intrauterine treatment of severe congenital hypothyroidism associated with fetal goiter. *J Obstet Gynaecol Res*. 2017;43:232–237.
642. Fujii S, Nagaishi J, Mukuda N, et al. Evaluation of fetal thyroid with 3D gradient echo T1-weighted MR imaging. *Magn Reson Med Sci*. 2017; 16:203–208.
643. Gietka-Czernel M, Dębska M, Kretowicz P, Jastrzębska H, Zgliczyński W. Increased size and vascularisation, plus decreased echogenicity, of foetal thyroid in two-dimensional ultrasonography caused by maternal Graves' disease. *Endokrynol Pol*. 2014;65:64–68.
644. Gietka-Czernel M, Dębska M, Kretowicz P, Zgliczyński W, Oltarzewski M. Hyperthyroidism during pregnancy—the role of measuring maternal TSH receptor antibodies and foetal ultrasound monitoring. *Endokrynol Pol*. 2014;65:259–268.
645. Zielinski R, Respondek-Liberska M. The role of prenatal ultrasound assessment in management of fetal cervicofacial tumors. *Arch Med Sci*. 2016;12:850–855.
646. Reitman E, Flood P. Anaesthetic considerations for non-obstetric surgery during pregnancy. *Br J Anaesth*. 2011;107(suppl 1):i72–i78.
647. Van De Velde M, De Buck F. Anesthesia for non-obstetric surgery in the pregnant patient. *Minerva Anestesiol*. 2007;73:235–240.
648. Sorensen JR, Sørensen JR, Hegedüs L, Kruse-Andersen S, Godballe C, Bonnema SJ. The impact of goitre and its treatment on the trachea, airflow, oesophagus and swallowing function. A systematic review. *Best Pract Res Clin Endocrinol Metab*. 2014;28:481–494.
649. Gerber D. [Thyroid weights and iodized salt prophylaxis: a comparative study from autopsy material from the Institute of Pathology, University of Zurich]. *Schweiz Med Wochenschr*. 1980;110:2010–2017.
650. Matovinovic J. Endemic goiter and cretinism at the dawn of the third millennium. *Annu Rev Nutr*. 1983;3:341–412.
651. Mortenson JD, Woolner LB, Bennett WA. Gross and microscopic findings in clinically normal thyroid glands. *J Clin Endocrinol Metab*. 1955;15:1270–1280.
652. Pankow BG, Michalak J, McGee MK. Adult human thyroid weight. *Health Phys*. 1985;49:1097–1103.



653. Langer P. Minireview: discussion about the limit between normal thyroid goiter. *Endocr Regul.* 1999;33:39–45.
654. Derwahl M, Studer H. Nodular goiter and goiter nodules: where iodine deficiency falls short of explaining the facts. *Exp Clin Endocrinol Diabetes.* 2001;109:250–260.
655. Pearce EN, Andersson M, Zimmermann MB. Global iodine nutrition: where do we stand in 2013? *Thyroid.* 2013;23:523–528.
656. Carle A, Krejbjerg A, Laurberg P. Epidemiology of nodular goitre. Influence of iodine intake. *Best Pract Res Clin Endocrinol Metab.* 2014;28:465–479.
657. Krohn K, Führer D, Bayer Y, et al. Molecular pathogenesis of euthyroid and toxic multinodular goiter. *Endocr Rev.* 2005;26:504–524.
658. Paschke R, Ludgate M. The thyrotropin receptor in thyroid diseases. *N Engl J Med.* 1997;337:1675–1681.
659. Krohn K, Paschke R. Clinical review 133: progress in understanding the etiology of thyroid autonomy. *J Clin Endocrinol Metab.* 2001;86:3336–3345.
660. Medeiros-Neto G, Camargo RY, Tomimori EK. Approach to and treatment of goiters. *Med Clin North Am.* 2012;96:351–368.
661. Hegedus L, Bonnema SJ, Bennedbaek FN. Management of simple nodular goiter: current status and future perspectives. *Endocr Rev.* 2003;24:102–132.
662. Duprez L, Parma J, Van Sande J, et al. Germline mutations in the thyrotropin receptor gene cause non-autoimmune autosomal dominant hyperthyroidism. *Nat Genet.* 1994;7:396–401.
663. White ML, Doherty GM, Gauger PG. Evidence-based surgical management of substernal goiter. *World J Surg.* 2008;32:1285–1300.
664. Shin JJ, Grillo HC, Mathisen D, et al. The surgical management of goiter: Part I. Preoperative evaluation. *Laryngoscope.* 2011;121:60–67.
665. Gutierrez T, Leong AC, Pang L, Chevretton E, Jeannon JP, Simo R. Multinodular thyroid goitre causing obstructive sleep apnoea syndrome. *J Laryngol Otol.* 2012;126:190–195.
666. Menon SK, Jagtap VS, Sarathi V, et al. Prevalence of upper airway obstruction in patients with apparently asymptomatic euthyroid multinodular goitre. *Indian J Endocrinol Metab.* 2011;15(suppl 2):S127–S131.
667. Thusoo TK, Gupta U, Kochhar K, Hira HS. Upper airway obstruction in patients with goiter studies by flow volume loops and effect of thyroidectomy. *World J Surg.* 2000;24:1570–1572.
668. Miller MR, Pincock AC, Oates GD, Wilkinson R, Skene-Smith H. Upper airway obstruction due to goitre: detection, prevalence and results of surgical management. *Q J Med.* 1990;74:177–188.
669. Jauregui R, Lilker ES, Bayley A. Upper airway obstruction in euthyroid goiter. *JAMA.* 1977;238:2163–2166.
670. Albareda M, Viguera J, Santiveri C, et al. Upper airway obstruction in patients with endotheracic goiter enlargement: no relationship between flow-volume loops and radiological tests. *Eur J Endocrinol.* 2010;163:665–669.
671. Arici C, Dertsiz L, Altunbas H, Demircan A, Emek K. Operative management of substernal goiter: analysis of 52 patients. *Int Surg.* 2001;86:220–224.
672. Parra-Membrives P, Sánchez-Blanco JM, Gómez-Rubio D, Recio-Moyano G, Diaz-Roldán J. Retrosternal goiters: safety of surgical treatment. *Int Surg.* 2003;88:205–210.
673. Erbil Y, Bozboru A, Barbaros U, Ozarmağan S, Azezi A, Molvalilar S. Surgical management of substernal goiters: clinical experience of 170 cases. *Surg Today.* 2004;34:732–736.
674. Pieracci FM, Fahey TJ 3rd. Substernal thyroidectomy is associated with increased morbidity and mortality as compared with conventional cervical thyroidectomy. *J Am Coll Surg.* 2007;205:1–7.
675. Pemberton HS. Sign of submerged goitre. *Lancet.* 1946;248:509.
676. Zhou H, McHenry CR, Pemberton HS. Surgical endocrinopathies: clinical management and the founding figures, ed. Pasielka JL and L JA 2015, Switzerland: Springer International Publishing.
677. Hintze G, Emrich D, Kobberling J. Treatment of endemic goitre due to iodine deficiency with iodine, levothyroxine or both: results of a multicentre trial. *Eur J Clin Invest.* 1989;19:527–534.
678. Grussendorf M, Reiners C, Paschke R, Wegscheider K; LISA Investigators. Reduction of thyroid nodule volume by levothyroxine and iodine alone and in combination: a randomized, placebo-controlled trial. *J Clin Endocrinol Metab.* 2011;96:2786–2795.
679. Koc M, Ersoz HO, Akpınar I, Gogas-Yavuz D, Deyneli O, Akalin S. Effect of low- and high-dose levothyroxine on thyroid nodule volume: a crossover placebo-controlled trial. *Clin Endocrinol (Oxf).* 2002;57:621–628.
680. Berghout A, Wiersinga WM, Drexhage HA, Smits NJ, Touber JL. Comparison of placebo with L-thyroxine alone or with carbimazole for treatment of sporadic non-toxic goitre. *Lancet.* 1990;336:193–197.
681. Wesche MF, Tiel-V Buul MM, Lips P, Smits NJ, Wiersinga WM. A randomized trial comparing levothyroxine with radioactive iodine in the treatment of sporadic nontoxic goiter. *J Clin Endocrinol Metab.* 2001;86:998–1005.
682. Fast S, Bonnema SJ, Hegedus L. The majority of Danish nontoxic goitre patients are ineligible for Levothyroxine suppressive therapy. *Clin Endocrinol (Oxf).* 2008;69:653–658.
683. Schneider R, Schneider M, Reiners C, Schneider P. Effects of levothyroxine on bone mineral density, muscle force, and bone turnover markers: a cohort study. *J Clin Endocrinol Metab.* 2012;97:3926–3934.
684. Hegedus L, Nygaard B, Hansen JM. Is routine thyroxine treatment to hinder postoperative recurrence of nontoxic goiter justified? *J Clin Endocrinol Metab.* 1999;84:756–760.
685. Fast S, Nielsen VE, Grupe P, et al. Prestimulation with recombinant human thyrotropin (rhTSH) improves the long-term outcome of radioiodine therapy for multinodular nontoxic goiter. *J Clin Endocrinol Metab.* 2012;97:2653–2660.
686. Nieuwlaet WA, et al. Pretreatment with a single, low dose of recombinant human thyrotropin allows dose reduction of radioiodine therapy in patients with nodular goiter. *J Clin Endocrinol Metab.* 2003;88:3121–3129.
687. Huysmans DA, Huysmans DA, van den Bosch HC, et al. Administration of a single low dose of recombinant human thyrotropin significantly enhances thyroid radioiodide uptake in nontoxic nodular goiter. *J Clin Endocrinol Metab.* 2000;85:3592–3596.
688. Bonnema SJ, Hegedus L. Radioiodine therapy in benign thyroid diseases: effects, side effects, and factors affecting therapeutic outcome. *Endocr Rev.* 2012;33:920–980.
689. Cirocchi R, Trastulli S, Randolph J, et al. Total or near-total thyroidectomy versus subtotal thyroidectomy for multinodular non-toxic goitre in adults. *Cochrane Database Syst Rev.* 2015;(8):CD010370.
690. Giles Y, Boztepe H, Terzioglu T, Tezelman S. The advantage of total thyroidectomy to avoid reoperation for incidental thyroid cancer in multinodular goiter. *Arch Surg.* 2004;139:179–182.
691. Pappalardo G, Guadalajara A, Frattaroli FM, Illomei G, Falaschi P. Total compared with subtotal thyroidectomy in benign nodular diseases: personal series and review of published reports. *Eur J Surg.* 1998;164:501–506.
692. Barczynski M, Konturek A, Hubalewska-Dydejczyk A, Gólkowski F, Cichoń S, Nowak W. Five-year follow-up of a randomized clinical trial of total thyroidectomy versus Dunhill operation versus bilateral subtotal thyroidectomy for multinodular nontoxic goiter. *World J Surg.* 2010;34:1203–1213.
693. Yang W, Shao T, Ding J, et al. The feasibility of total or near-total bilateral thyroidectomy for the treatment of bilateral multinodular goiter. *J Invest Surg.* 2009;22:195–200.
694. Phitayakorn R, Narendra D, Bell S, McHenry CR. What constitutes adequate surgical therapy for benign nodular goiter? *J Surg Res.* 2009;154:51–55.
695. Attaallah W, Erel S, Canturk NZ, et al. Is hemithyroidectomy a rational management for benign nodular goitre? A multicentre retrospective single group study. *Neth J Med.* 2015;73:17–22.
696. Lang BH, Chu KK, Tsang RK, Wong KP, Wong BY. Evaluating the incidence, clinical significance and predictors for vocal cord palsy and incidental laryngopharyngeal conditions before elective thyroidectomy: is there a case for routine laryngoscopic examination? *World J Surg.* 2014;38:385–391.
697. Netterville JL, Coleman SC, Smith JC, Smith MM, Day TA, Burkey BB. Management of substernal goiter. *Laryngoscope.* 1998;108(1 pt 1):1611–1617.
698. Cooper JC, Nakielny R, Talbot CH. The use of computed tomography in the evaluation of large multinodular goitres. *Ann R Coll Surg Engl.* 1991;73:32–35.
699. Tsilimigras DI, Patrini D, Antonopoulou A, et al. Retrosternal goitre: the role of the thoracic surgeon. *J Thorac Dis.* 2017;9:860–863.
700. Mercante G, Gabrielli E, Pedroni C, et al. CT cross-sectional imaging classification system for substernal goiter based on risk factors for an extracervical surgical approach. *Head Neck.* 2011;33:792–799.
701. Pieracci FM, Fahey TJ 3rd. Effect of hospital volume of thyroidectomies on outcomes following substernal thyroidectomy. *World J Surg.* 2008;32:740–746.
702. Agarwal A, Agarwal S, Tewari P, et al. Clinicopathological profile, airway management, and outcome in huge multinodular goiters: an institutional experience from an endemic goiter region. *World J Surg.* 2012;36:755–760.

703. Gilfillan N, Ball CM, Myles PS, Serpell J, Johnson WR, Paul E. A cohort and database study of airway management in patients undergoing thyroidectomy for retrosternal goitre. *Anaesth Intensive Care*. 2014;42:700–708.
704. Randolph GW, Dralle H, International Intraoperative Monitoring Study Group, et al. Electrophysiologic recurrent laryngeal nerve monitoring during thyroid and parathyroid surgery: international standards guideline statement. *Laryngoscope*. 2011;121(suppl 1):S1–16.
705. Samraj K, Gurusamy KS. Wound drains following thyroid surgery. *Cochrane Database Syst Rev*. 2007;(4):CD006099.
706. Tian J, Li L, Liu P, Wang X. Comparison of drain versus no-drain thyroidectomy: a meta-analysis. *Eur Arch Otorhinolaryngol*. 2017;274:567–577.
707. Moten AS, Thibault DP, Willis AW, Willis AI. Demographics, disparities, and outcomes in substernal goiters in the United States. *Am J Surg*. 2016;211:703–709.
708. Findlay JM, Sadler GP, Bridge H, Mihai R. Post-thyroidectomy tracheomalacia: minimal risk despite significant tracheal compression. *Br J Anaesth*. 2011;106:903–906.
709. Chi SY, Wu SC, Hsieh KC, Sheen-Chen SM, Chou FF. Noninvasive positive pressure ventilation in the management of post-thyroidectomy tracheomalacia. *World J Surg*. 2011;35:1977–1983.
710. Kirdak T, Korun N, Ozguc H. Use of ligasure in thyroidectomy procedures: results of a prospective comparative study. *World J Surg*. 2005;29:771–774.
711. Saint Marc O, Cogliandolo A, Piquard A, Famà F, Pidoto RR. LigaSure vs clamp-and-tie technique to achieve hemostasis in total thyroidectomy for benign multinodular goiter: a prospective randomized study. *Arch Surg*. 2007;142:150–156.
712. Yao HS, Wang Q, Wang WJ, Ruan CP. Prospective clinical trials of thyroidectomy with LigaSure vs conventional vessel ligation: a systematic review and meta-analysis. *Arch Surg*. 2009;144:1167–1174.
713. Singh P, O'Connell D, Langille M, Dziegielewski P, Allegritto M, Harris J. LigaSure versus conventional hemostasis in thyroid surgery: prospective randomized controlled trial. *J Otolaryngol Head Neck Surg*. 2010;39:378–384.
714. Schiphorst AH, Twigt BA, Elias SG, van Dalen T. Randomized clinical trial of LigaSure versus conventional suture ligation in thyroid surgery. *Head Neck Oncol*. 2012;4:2.
715. Glover AR, Gundara JS, Lee JC, Sywak MS, Delbridge LW, Sidhu SB. Thermal sealing systems with and without tissue divider for total thyroidectomy. *ANZ J Surg*. 2014;84:383–385.
716. Cordon C, Cordon C, Fajardo R, Ramirez J, Herrera MF. A randomized, prospective, parallel group study comparing the Harmonic Scalpel to electrocautery in thyroidectomy. *Surgery*. 2005;137:337–341.
717. Miccoli P, Berti P, Dionigi GL, et al. Randomized controlled trial of harmonic scalpel use during thyroidectomy. *Arch Otolaryngol Head Neck Surg*. 2006;132:1069–1073.
718. Kang SK, Kunanandam T, Clark L. Prospective, case-control study of surgical efficiency of ultrasonic shear ('harmonic scalpel') thyroidectomy compared with conventional thyroidectomy. *J Laryngol Otol*. 2008;122:1194–1196.
719. Koh YW, Park JH, Lee SW, Choi EC. The harmonic scalpel technique without supplementary ligation in total thyroidectomy with central neck dissection: a prospective randomized study. *Ann Surg*. 2008;247:945–949.
720. Lombardi CP, Raffaelli M, Cicchetti A, et al. The use of "harmonic scalpel" versus "knot tying" for conventional "open" thyroidectomy: results of a prospective randomized study. *Langenbecks Arch Surg*. 2008;393:627–631.
721. Duan YF, Xue W, Zhu F, Sun DL. FOCUS harmonic scalpel compared to conventional hemostasis in open total thyroidectomy: a prospective randomized study. *J Otolaryngol Head Neck Surg*. 2013;42:62.
722. Zanghi A, Cavallaro A, Di Vita M, et al. The safety of the Harmonic(R) FOCUS in open thyroidectomy: a prospective, randomized study comparing the Harmonic(R) FOCUS and traditional suture ligation (knot and tie) technique. *Int J Surg*. 2014;12(suppl 1):S132–S135.
723. Sartori PV, De Fina S, Colombo G, et al. Ligasure versus Ultracision in thyroid surgery: a prospective randomized study. *Langenbecks Arch Surg*. 2008;393:655–658.
724. Pons Y, Gauthier J, Ukkola-Pons E, et al. Comparison of LigaSure vessel sealing system, harmonic scalpel, and conventional hemostasis in total thyroidectomy. *Otolaryngol Head Neck Surg*. 2009;141:496–501.
725. Rahbari R, Mathur A, Kitano M, et al. Prospective randomized trial of ligasure versus harmonic hemostasis technique in thyroidectomy. *Ann Surg Oncol*. 2011;18:1023–1027.
726. Dionigi G, Boni L, Rausei S, et al. The safety of energy-based devices in open thyroidectomy: a prospective, randomised study comparing the LigaSure (LF1212) and the Harmonic(R) FOCUS. *Langenbecks Arch Surg*. 2012;397:817–823.
727. Kwak HY, Chae BJ, Park YG, et al. Comparison of surgical outcomes between papillary thyroid cancer patients treated with the Harmonic ACE scalpel and LigaSure Precise instrument during conventional thyroidectomy: a single-blind prospective randomized controlled trial. *J Surg Res*. 2014;187:484–489.
728. Hwang SO, Jung JH, Park HY, Kim WW. A prospective, randomized study between the small Jaw(R) and the harmonic Focus(R) in open thyroidectomy. *Otolaryngol Head Neck Surg*. 2014;150:943–948.
729. Garas G, Okabayashi K, Ashrafian H, et al. Which hemostatic device in thyroid surgery? A network meta-analysis of surgical technologies. *Thyroid*. 2013;23:1138–1150.
730. Contini P, Gooßen K, Grummich K, et al. ENERgized vessel sealing systems versus CONVENTIONAL hemostasis techniques in thyroid surgery—the ENERCON systematic review and network meta-analysis. *Langenbecks Arch Surg*. 2013;398:1039–1056.
731. Lo CY, Kwok KF, Yuen PW. A prospective evaluation of recurrent laryngeal nerve paralysis during thyroidectomy. *Arch Surg*. 2000;135:204–207.
732. Chan WF, Lang BH, Lo CY. The role of intraoperative neuromonitoring of recurrent laryngeal nerve during thyroidectomy: a comparative study on 1000 nerves at risk. *Surgery*. 2006;140:866–872.
733. Shindo M, Chheda NN. Incidence of vocal cord paralysis with and without recurrent laryngeal nerve monitoring during thyroidectomy. *Arch Otolaryngol Head Neck Surg*. 2007;133:481–485.
734. Dralle H, Sekulla C, Lorenz K, et al. Intraoperative monitoring of the recurrent laryngeal nerve in thyroid surgery. *World J Surg*. 2008;32:1358–1366.
735. Alesina PF, Rolfs T, Hommeltenberg S, et al. Intraoperative neuromonitoring does not reduce the incidence of recurrent laryngeal nerve palsy in thyroid reoperations: results of a retrospective comparative analysis. *World J Surg*. 2012;36:1348–1353.
736. Cavicchi O, Caliceti U, Fernandez IJ, et al. Laryngeal neuromonitoring and neurostimulation versus neurostimulation alone in thyroid surgery: a randomized clinical trial. *Head Neck*. 2012;34:141–145.
737. Pisanu A, Porceddu G, Podda M, Cois A, Uccheddu A. Systematic review with meta-analysis of studies comparing intraoperative neuromonitoring of recurrent laryngeal nerves versus visualization alone during thyroidectomy. *J Surg Res*. 2014;188:152–161.
738. Calò PG, Pisano G, Medas F, et al. Identification alone versus intraoperative neuromonitoring of the recurrent laryngeal nerve during thyroid surgery: experience of 2034 consecutive patients. *J Otolaryngol Head Neck Surg*. 2014;43:16.
739. Mirallié É, Caillaud C, Pattou F, et al. Does intraoperative neuromonitoring of recurrent nerves have an impact on the postoperative palsy rate? Results of a prospective multicenter study. *Surgery*. 2018;163:124–129.
740. Henry BM, Graves MJ, Vikse J, et al. The current state of intermittent intraoperative neural monitoring for prevention of recurrent laryngeal nerve injury during thyroidectomy: a PRISMA-compliant systematic review of overlapping meta-analyses. *Langenbecks Arch Surg*. 2017;402:663–673.
741. Rocke DJ, Goldstein DP, de Almeida JR. A cost-utility analysis of recurrent laryngeal nerve monitoring in the setting of total thyroidectomy. *JAMA Otolaryngol Head Neck Surg*. 2016;142:1199–1205.
742. Al-Qurayshi Z, Kandil E, Randolph GW. Cost-effectiveness of intraoperative nerve monitoring in avoidance of bilateral recurrent laryngeal nerve injury in patients undergoing total thyroidectomy. *Br J Surg*. 2017;104:1523–1531.
743. Wong KP, Mak KL, Wong CK, Lang BH. Systematic review and meta-analysis on intra-operative neuro-monitoring in high-risk thyroidectomy. *Int J Surg*. 2017;38:21–30.
744. Wojtczak B, Kaliszewski K, Sutkowski K, Glód M, Barczyński M. The learning curve for intraoperative neuromonitoring of the recurrent laryngeal nerve in thyroid surgery. *Langenbecks Arch Surg*. 2017;402:701–708.
745. Dionigi G, Frattini F. Staged thyroidectomy: time to consider intraoperative neuromonitoring as standard of care. *Thyroid*. 2013;23:906–908.
746. Fontenot TE, Randolph GW, Setton TE, Alsaleh N, Kandil E. Does intraoperative nerve monitoring reliably aid in staging of total thyroidectomies? *Laryngoscope*. 2015;125:2232–2235.
747. Schneider R, Randolph GW, Dionigi G, et al. International neural monitoring study group guideline 2018 part I: staging bilateral thyroid surgery with monitoring loss of signal. *Laryngoscope*. 2018;128(suppl 3):S1–S17.
748. Wu CW, Dionigi G, Barczyński M, et al. International neuromonitoring study group guidelines 2018: Part II: optimal recurrent laryngeal nerve

- management for invasive thyroid cancer-incorporation of surgical, laryngeal, and neural electrophysiologic data. *Laryngoscope*. 2018;128(suppl 3):S18–S27.
749. Stopa M, Barczynski M. Prognostic value of intraoperative neural monitoring of the recurrent laryngeal nerve in thyroid surgery. *Langenbecks Arch Surg*. 2017;402:957–964.
750. Koulouris C, Papavramidis TS, Pliakos I, et al. Intraoperative stimulation neuromonitoring versus intraoperative continuous electromyographic neuromonitoring in total thyroidectomy: identifying laryngeal complications. *Am J Surg*. 2012;204:49–53.
751. Schneider R, Randolph GW, Sekulla C, et al. Continuous intraoperative vagus nerve stimulation for identification of imminent recurrent laryngeal nerve injury. *Head Neck*. 2013;35:1591–1598.
752. Phelan E, Schneider R, Lorenz K, et al. Continuous vagal IONM prevents recurrent laryngeal nerve paralysis by revealing initial EMG changes of impending neuropraxic injury: a prospective, multicenter study. *Laryngoscope*. 2014;124:1498–1505.
753. Dionigi G, Chiang FY, Hui S, et al. Continuous Intraoperative Neuro-monitoring (C-IONM) Technique with the Automatic Periodic Stimulating (APS) Accessory for Conventional and Endoscopic Thyroid Surgery. *Surg Technol Int*. 2015;26:101–114.
754. Kandil E, Mohsin K, Murcy MA, Randolph GW. Continuous vagal monitoring value in prevention of vocal cord paralysis following thyroid surgery. *Laryngoscope*. 2018;128:2429–2432.
755. Marin Arteaga A, Peloni G, Leuchter J, et al. Modification of the surgical strategy for the dissection of the recurrent laryngeal nerve using continuous intraoperative nerve monitoring. *World J Surg*. 2018;42:444–450.
756. Terris DJ, Chaung K, Duke WS. Continuous vagal nerve monitoring is dangerous and should not routinely be done during thyroid surgery. *World J Surg*. 2015;39:2471–2476.
757. Barczynski M, Barczyński M, Konturek A, Stopa M, Honowska A, Nowak W. Randomized controlled trial of visualization versus neuromonitoring of the external branch of the superior laryngeal nerve during thyroidectomy. *World J Surg*. 2012;36:1340–1347.
758. Glover AR, Norlén O, Gundara JS, Morris M, Sidhu SB. Use of the nerve integrity monitor during thyroid surgery aids identification of the external branch of the superior laryngeal nerve. *Ann Surg Oncol*. 2015;22:1768–1773.
759. Kandil E, Mohamed SE, Deniwar A, et al. Electrophysiologic identification and monitoring of the external branch of superior laryngeal nerve during thyroidectomy. *Laryngoscope*. 2015;125:1996–2000.
760. Masuoka H, Miyauchi A, Higashiyama T, et al. Prospective randomized study on injury of the external branch of the superior laryngeal nerve during thyroidectomy comparing intraoperative nerve monitoring and a conventional technique. *Head Neck*. 2015;37:1456–1460.
761. Lo CY, Luk JM, Tam SC. Applicability of intraoperative parathyroid hormone assay during thyroidectomy. *Ann Surg*. 2002;236:564–569.
762. Richards ML, Bingener-Casey J, Pierce D, Strodel WE, Sirinek KR. Intraoperative parathyroid hormone assay: an accurate predictor of symptomatic hypocalcemia following thyroidectomy. *Arch Surg*. 2003;138:632–635.
763. Higgins KM, Mandell DL, Govindaraj S, et al. The role of intraoperative rapid parathyroid hormone monitoring for predicting thyroidectomy-related hypocalcemia. *Arch Otolaryngol Head Neck Surg*. 2004;130:63–67.
764. Quiros RM, Pesce CE, Wilhelm SM, Djuricin G, Prinz RA. Intraoperative parathyroid hormone levels in thyroid surgery are predictive of postoperative hypoparathyroidism and need for vitamin D supplementation. *Am J Surg*. 2005;189:306–309.
765. Di Fabio F, Casella C, Bugari G, Iacobello C, Salerni B. Identification of patients at low risk for thyroidectomy-related hypocalcemia by intraoperative quick PTH. *World J Surg*. 2006;30:1428–1433.
766. McLeod IK, Arciero C, Noordzij JP, et al. The use of rapid parathyroid hormone assay in predicting postoperative hypocalcemia after total or completion thyroidectomy. *Thyroid*. 2006;16:259–265.
767. Barczynski M, Cichon S, Konturek A. Which criterion of intraoperative iPTH assay is the most accurate in prediction of true serum calcium levels after thyroid surgery? *Langenbecks Arch Surg*. 2007;392:693–698.
768. Lang BH, Yih PC, Ng KK. A prospective evaluation of quick intraoperative parathyroid hormone assay at the time of skin closure in predicting clinically relevant hypocalcemia after thyroidectomy. *World J Surg*. 2012;36:1300–1306.
769. Gupta S, Chaudhary P, Durga CK, Naskar D, et al. Validation of intraoperative parathyroid hormone and its decline as early predictors of hypoparathyroidism after total thyroidectomy: a prospective cohort study. *Int J Surg*. 2015;18:150–153.
770. Reddy AC, Chand G, Sabaretnam M, et al. Prospective evaluation of intraoperative quick parathyroid hormone assay as an early predictor of post thyroidectomy hypocalcaemia. *Int J Surg*. 2016;34:103–108.
771. Lee DR, Hinson AM, Siegel ER, Steelman SC, Bodenner DL, Stack BC Jr. Comparison of intraoperative versus postoperative parathyroid hormone levels to predict hypocalcemia earlier after total thyroidectomy. *Otolaryngol Head Neck Surg*. 2015;153:343–349.
772. De Leeuw F, Breuskin I, Abbaci M, et al. Intraoperative near-infrared imaging for parathyroid gland identification by auto-fluorescence: a feasibility study. *World J Surg*. 2016;40:2131–2138.
773. Kim SW, Song SH, Lee HS, et al. Intraoperative real-time localization of normal parathyroid glands with autofluorescence imaging. *J Clin Endocrinol Metab*. 2016;101:4646–4652.
774. McWade MA, Sanders ME, Broome JT, Solórzano CC, Mahadevan-Jansen A. Establishing the clinical utility of autofluorescence spectroscopy for parathyroid detection. *Surgery*. 2016;159:193–202.
775. Vidal Fortuny J, Belfontali V, Sadowski SM, Karenovics W, Guigard S, Triponez F. Parathyroid gland angiography with indocyanine green fluorescence to predict parathyroid function after thyroid surgery. *Br J Surg*. 2016;103:537–543.
776. Zaidi N, Bucak E, Yazici P, et al. The feasibility of indocyanine green fluorescence imaging for identifying and assessing the perfusion of parathyroid glands during total thyroidectomy. *J Surg Oncol*. 2016;113:775–778.
777. Lang BH, Wong CK, Hung HT, Wong KP, Mak KL, Au KB. Indocyanine green fluorescence angiography for quantitative evaluation of in situ parathyroid gland perfusion and function after total thyroidectomy. *Surgery*. 2017;161:87–95.
778. Kahramangil B, Dip F, Benmiloud F, et al. Detection of parathyroid autofluorescence using near-infrared imaging: a multicenter analysis of concordance between different surgeons. *Ann Surg Oncol*. 2018;25:957–962.
779. Kim MJ, Nam KH, Lee SG, et al. Yonsei experience of 5000 gasless transaxillary robotic thyroidectomies. *World J Surg*. 2018;42:393–401.
780. Lang BH, Wong CK, Tsang JS, Wong KP. A systematic review and meta-analysis comparing outcomes between robotic-assisted thyroidectomy and non-robotic endoscopic thyroidectomy. *J Surg Res*. 2014;191:389–398.
781. Choi JY, Lee KE, Chung KW, et al. Endoscopic thyroidectomy via bilateral axillo-breast approach (BABA): review of 512 cases in a single institute. *Surg Endosc*. 2012;26:948–955.
782. Lee KE, Kim E, Koo do H, Choi JY, Kim KH, Youn YK. Robotic thyroidectomy by bilateral axillo-breast approach: review of 1,026 cases and surgical completeness. *Surg Endosc*. 2013;27:2955–2962.
783. Berber E, Bernet V, Fahey TJ 3rd, et al. American Thyroid Association statement on remote-access thyroid surgery. *Thyroid*. 2016;26:331–337.
784. Anuwong A. Transoral endoscopic thyroidectomy vestibular approach: a series of the first 60 human cases. *World J Surg*. 2016;40:491–497.
785. Arviso LC, Johns MM 3rd, Mathison CC, Klein AM. Long-term outcomes of injection laryngoplasty in patients with potentially recoverable vocal fold paralysis. *Laryngoscope*. 2010;120:2237–2240.
786. Adam MA, Speicher P, Pura J, et al. Robotic thyroidectomy for cancer in the US: patterns of use and short-term outcomes. *Ann Surg Oncol*. 2014;21:3859–3864.
787. Lang BH, Ng SH, Lau LL, Cowling BJ, Wong KP. A systematic review and meta-analysis comparing the efficacy and surgical outcomes of total thyroidectomy between harmonic scalpel versus ligasure. *Ann Surg Oncol*. 2013;20:1918–1926.
788. Landry CS, Grubbs EG, Morris GS, et al. Robot assisted transaxillary surgery (RATS) for the removal of thyroid and parathyroid glands. *Surgery*. 2011;149:549–555.
789. Amit M, Binenbaum Y, Cohen JT, Gil Z. Effectiveness of an oxidized cellulose patch hemostatic agent in thyroid surgery: a prospective, randomized, controlled study. *J Am Coll Surg*. 2013;217:221–225.
790. Testini M, Marzaioli R, Lissidini G, et al. The effectiveness of FloSeal matrix hemostatic agent in thyroid surgery: a prospective, randomized, control study. *Langenbecks Arch Surg*. 2009;394:837–842.
791. Docimo G, Tolone S, Conzo G, et al. A Gelatin-Thrombin Matrix Topical Hemostatic Agent (FloSeal) in combination with harmonic scalpel is effective in patients undergoing total thyroidectomy: a prospective, multicenter, single-blind, randomized controlled trial. *Surg Innov*. 2016;23:23–29.

792. Uwiera TC, Uwiera RR, Seikaly H, Harris JR. Tisseel and its effects on wound drainage post-thyroidectomy: prospective, randomized, blinded, controlled study. *J Otolaryngol*. 2005;34:374–378.
793. Snyder SK, Angelos P, Carty SE, et al. Injection of bulking agents for laryngoplasty. *Surgery*. 2018;163:6–8.
794. Jeannon JP, Orabi AA, Bruch GA, Abdalsalam HA, Simo R. Diagnosis of recurrent laryngeal nerve palsy after thyroidectomy: a systematic review. *Int J Clin Pract*. 2009;63:624–629.
795. Papaleontiou M, Hughes DT, Guo C, Banerjee M, Haymart MR. Population-based assessment of complications following surgery for thyroid cancer. *J Clin Endocrinol Metab*. 2017.
796. Kikura M, Suzuki K, Itagaki T, Takada T, Sato S. Age and comorbidity as risk factors for vocal cord paralysis associated with tracheal intubation. *Br J Anaesthesia*. 2007;98:524–530.
797. Gardner GM, Smith MM, Yaremchuk KL, Peterson EL. The cost of vocal fold paralysis after thyroidectomy. *Laryngoscope*. 2013;123:1455–1463.
798. Fundakowski CE, Hales NW, Agrawal N, et al. Surgical management of the recurrent laryngeal nerve in thyroidectomy: American Head and Neck Society Consensus Statement. *Head Neck*. 2018;40:663–675.
799. Hodin R, Clark O, Doherty G, Grant C, Heller K, Weigel R. Voice issues and laryngoscopy in thyroid surgery patients. *Surgery*. 2013;154:46–47.
800. Sinclair CF, Bumpous JM, Haugen BR, et al. Laryngeal examination in thyroid and parathyroid surgery: an American Head and Neck Society consensus statement: AHNS Consensus Statement. *Head Neck*. 2016;38:811–819.
801. Lee CY, Long KL, Eldridge RJ, Davenport DL, Sloan DA. Preoperative laryngoscopy in thyroid surgery: Do patients' subjective voice complaints matter? *Surgery*. 2014;156:1477–1482.
802. Bergenfelz A, Jansson S, Kristofferson A, et al. Complications to thyroid surgery: results as reported in a database from a multicenter audit comprising 3,660 patients. *Langenbecks Arch Surg*. 2008;393:667–673.
803. Maniakas A, Christopoulos A, Bissada E, et al. Perioperative practices in thyroid surgery: an international survey. *Head Neck*. 2017;39:1296–1305.
804. Scott-Coombes, D. The British Association of Endocrine and Thyroid Surgeons – Third National Audit Report.
805. Shaha AR. Editorial: laryngeal evaluation for thyroid surgery: back to the basics. *Surgery*. 2016;159:65–66.
806. Xin J, Liu X, Sun H, Li J, Zhang D, Fu Y. A laryngoscopy-based classification system for perioperative abnormal vocal cord movement in thyroid surgery. *J Int Med Res*. 2014;42:1029–1037.
807. Speyer R, Bogaardt HC, Passos VL, et al. Maximum phonation time: variability and reliability. *J Voice*. 2010;24:281–284.
808. Kempster GB, Gerratt BR, Verdolini Abbott K, Barkmeier-Kraemer J, Hillman RE. Consensus auditory-perceptual evaluation of voice: development of a standardized clinical protocol. *Am J Speech Lang Pathol*. 2009;18:124–132.
809. Jacobson BH, Johnson A, Grywalski C, et al. The Voice Handicap Index (VHI): Development and Validation. *Am J Speech-Lang Pathol*. 1997;6:66–70.
810. Hirano, M, ed. *Clinical Examination of Voice*. New York: Springer Verlag; 1981:81–4.
811. Dejonckere, GRBAS-scaling of pathological voices: reliability, clinical relevance and differentiated correlation with acoustic measurements, especially with cepstral measurements. Proceedings of the 22nd IALP Congress, Hanover, Germany, 1992.
812. Hirano, M. Clinical applications of voice tests, assessment of speech and voice production: research and clinical applications. NIDCD monograph in Proceedings of a conference of the National Institute of Health. 1990. Bethesda, MD.
813. Franch-Arcas G, González-Sánchez C, Aguilera-Molina YY, et al. Is there a case for selective, rather than routine, preoperative laryngoscopy in thyroid surgery? *Gland Surg*. 2015;4:8–18.
814. Lang BH, Wong CK, Tsang RK, Wong KP, Wong BY. Evaluating the cost-effectiveness of laryngeal examination after elective total thyroidectomy. *Ann Surg Oncol*. 2014;21:3548–3556.
815. Kay-Rivest E, Mitmaker E, Payne RJ, et al. Preoperative vocal cord paralysis and its association with malignant thyroid disease and other pathological features. *J Otolaryngol Head Neck Surg*. 2015;44:35.
816. Wang CC, Wang CP, Tsai TL, et al. The basis of preoperative vocal fold paralysis in a series of patients undergoing thyroid surgery: the preponderance of benign thyroid disease. *Thyroid*. 2011;21:867–872.
817. Cheng SP, Lee JJ, Liu TP, Lee KS, Liu CL. Preoperative ultrasonography assessment of vocal cord movement during thyroid and parathyroid surgery. *World J Surg*. 2012;36:2509–2515.
818. Green KM, de Carpentier JP. Are pre-operative vocal fold checks necessary? *J Laryngol Otol*. 1999;113:642–644.
819. Rowe-Jones JM, Rosswick RP, Leighton SE. Benign thyroid disease and vocal cord palsy. *Ann R Coll Surg Engl*. 1993;75:241–244.
820. de Pedro Netto I, Fae A, Vartanian JG, et al. Voice and vocal self-assessment after thyroidectomy. *Head Neck*. 2006;28:1106–1114.
821. Musholt TJ, Musholt PB, Garm J, et al. Changes of the speaking and singing voice after thyroid or parathyroid surgery. *Surgery*. 2006;140:978–988.
822. Page C, Zaatar R, Biet A, Strunski V. Subjective voice assessment after thyroid surgery: a prospective study of 395 patients. *Indian J Med Sci*. 2007;61:448–454.
823. Rosato L, Carlevato MT, De Toma G, Avenia N. Recurrent laryngeal nerve damage and phonetic modifications after total thyroidectomy: surgical malpractice only or predictable sequence? *World J Surg*. 2005;29:780–784.
824. Sinagra DL, Montesinos MR, Tacchi VA, et al. Voice changes after thyroidectomy without recurrent laryngeal nerve injury. *J Am Coll Surg*. 2004;199:556–560.
825. Stojadinovic A, Shaha AR, Orlikoff RF, et al. Prospective functional voice assessment in patients undergoing thyroid surgery. *Ann Surg*. 2002;236:823–832.
826. Mendels EJ, Brunings JW, Hamaekers AE, Stokroos RJ, Kremer B, Baijens LW. Adverse laryngeal effects following short-term general anesthesia: a systematic review. *Arch Otolaryngol Head Neck Surg*. 2012;138:257–264.
827. Friedman AD, Burns JA, Heaton JT, Zeitels SM. Early versus late injection medialization for unilateral vocal cord paralysis. *Laryngoscope*. 2010;120:2042–2046.
828. Yung KC, Likhterov I, Courey MS. Effect of temporary vocal fold injection medialization on the rate of permanent medialization laryngoplasty in unilateral vocal fold paralysis patients. *Laryngoscope*. 2011;121:2191–2194.
829. Mattsson P, Frostell A, Björck G, et al. Recovery of voice after reconstruction of the recurrent laryngeal nerve and adjuvant nimodipine. *World J Surg*. 2018;42:632–638.
830. Rosen CA, Smith L, Young V, Krishna P, Muldoon MF, Munin MC. Prospective investigation of nimodipine for acute vocal fold paralysis. *Muscle Nerve*. 2014;50:114–118.
831. Sridharan SS, Rosen CA, Smith LJ, Young VN, Munin MC. Timing of nimodipine therapy for the treatment of vocal fold paralysis. *Laryngoscope*. 2015;125:186–190.
832. Orestes MI, Chhetri DK. Superior laryngeal nerve injury: effects, clinical findings, prognosis, and management options. *Curr Opin Otolaryngol Head Neck Surg*. 2014;22:439–443.
833. Fuller DR, JP, Peregoy BM. *Applied Anatomy & Physiology for Speech-Language Pathology & Audiology*. Baltimore, MD: Wolters Kluwer- Lippincott Williams & Wilkins; 2012.
834. Potenza AS, Araujo Filho VJF, Cernea CR. Injury of the external branch of the superior laryngeal nerve in thyroid surgery. *Gland Surg*. 2017;6:552–562.
835. Mcivor NP, Flint DJ, Gillibrand J, Morton RP. Thyroid surgery and voice-related outcomes. *Aust N Z J Surg*. 2000;70:179–183.
836. Gourin CG and Eisele DW. CHAPTER 39 - *Complications of Thyroid Surgery, in Complications in Head and Neck Surgery*. 2nd ed. Philadelphia, PA: Mosby; 2009:493–515.
837. Cernea CR, Ferraz AR, Furlani J, et al. Identification of the external branch of the superior laryngeal nerve during thyroidectomy. *Am J Surg*. 1992;164:634–639.
838. Cernea CR, Nishio S, Hojaij FC. Identification of the external branch of the superior laryngeal nerve (EBSLN) in large goiters. *Am J Otolaryngol*. 1995;16:307–311.
839. Loré JM Jr, Kokocharov SI, Kaufman S, Richmond A, Sundquist N. Thirty-eight-year evaluation of a surgical technique to protect the external branch of the superior laryngeal nerve during thyroidectomy. *Ann Otol Rhinol Laryngol*. 1998;107:1015–1022.
840. Jansson S, Tisell LE, Hagne I, Sanner E, Stenborg R, Svensson P. Partial superior laryngeal nerve (SLN) lesions before and after thyroid surgery. *World J Surg*. 1988;12:522–527.
841. Barczyński M, Randolph GW, Cernea CR, et al. External branch of the superior laryngeal nerve monitoring during thyroid and parathyroid surgery: International Neural Monitoring Study Group standards guideline statement. *Laryngoscope*. 2013;123(suppl 4):S1–S14.

842. Genther DJ, Kandil EH, Noureldine SI, Tufano RP. Correlation of final evoked potential amplitudes on intraoperative electromyography of the recurrent laryngeal nerve with immediate postoperative vocal fold function after thyroid and parathyroid surgery. *JAMA Otolaryngol Head Neck Surg.* 2014;140:124–128.
843. Gohrbandt AE, Aschoff A, Gohrbandt B, et al. Changes of laryngeal mobility and symptoms following thyroid surgery: 6-month follow-up. *World J Surg.* 2016;40:636–643.
844. Henry LR, Abad JD, Stojadinovic A. The voice, not the nerve, is the functionally relevant endpoint. *J Surg Oncol.* 2012;106:1005–1006.
845. Lorenz K, Abuazab M, Sekulla C, et al. Results of intraoperative neuromonitoring in thyroid surgery and preoperative vocal cord paralysis. *World J Surg.* 2014;38:582–591.
846. Melin M, Schwarz K, Pearson MD, Lammers BJ, Goretzki PE. Postoperative vocal cord dysfunction despite normal intraoperative neuromonitoring: an unexpected complication with the risk of bilateral palsy. *World J Surg.* 2014;38:2597–2602.
847. Shonka DC Jr, Terris DJ. The American Thyroid Association Guidelines on Voice Assessment—Have We Done Enough? *JAMA Otolaryngol Head Neck Surg.* 2016;142:115–116.
848. Stopa M, Barczyński M. Prognostic value of intraoperative neural monitoring of the recurrent laryngeal nerve in thyroid surgery. *Langenbecks Arch Surg.* 2017;402:957–964.
849. Vicente DA, Solomon NP, Avital I, et al. Voice outcomes after total thyroidectomy, partial thyroidectomy, or non-neck surgery using a prospective multifactorial assessment. *J Am Coll Surg.* 2014;219:152–163.
850. Martinez ARM, Martins MP, Moreira AL, et al. Electrophysiology of cranial nerve testing: cranial nerves IX and X. *J Clin Neurophysiol.* 2018;35:48–58.
851. Sinagra DL, Montesinos MR, Tacchi VA, et al. Voice changes after thyroidectomy without recurrent laryngeal nerve injury. *J Am Coll Surg.* 2004; 199: 556–560.
852. Kaneko M, Hitomi T, Takekawa T, Tsuji T, Kishimoto Y, Hirano S. Effects of voice therapy on laryngeal motor units during phonation in chronic superior laryngeal nerve paresis dysphonia. *J Voice.* 2018;32:729–733.
853. Steurer M, Passler C, Denk DM, Schneider B, Niederle B, Bigenzahn W. Advantages of recurrent laryngeal nerve identification in thyroidectomy and parathyroidectomy and the importance of preoperative and postoperative laryngoscopic examination in more than 1000 nerves at risk. *Laryngoscope.* 2002;112:124–133.
854. Bergenfelz A, Salem AF, Jacobsson H, et al. Risk of recurrent laryngeal nerve palsy in patients undergoing thyroidectomy with and without intraoperative nerve monitoring. *Br J Surg.* 2016;103:1828–1838.
855. Xing M. Molecular pathogenesis and mechanisms of thyroid cancer. *Nat Rev Cancer.* 2013;13:184–199.
856. Peiling Yang S, Ngeow J. Familial non-medullary thyroid cancer: unraveling the genetic maze. *Endocr Relat Cancer.* 2016;23:R577–R595.
857. Loh KC. Familial nonmedullary thyroid carcinoma: a meta-review of case series. *Thyroid.* 1997;7:107–113.
858. Vriens MR, Suh I, Moses W, Kebebew E. Clinical features and genetic predisposition to hereditary nonmedullary thyroid cancer. *Thyroid.* 2009;19:1343–1349.
859. Moses W, Weng J, Kebebew E. Prevalence, clinicopathologic features, and somatic genetic mutation profile in familial versus sporadic nonmedullary thyroid cancer. *Thyroid.* 2011;21:367–371.
860. Robson ME, Bradbury AR, Arun B, et al. American Society of Clinical Oncology Policy Statement Update: Genetic and Genomic Testing for Cancer Susceptibility. *J Clin Oncol.* 2015;33:3660–3667.
861. Kurian AW, Hare EE, Mills MA, et al. Clinical evaluation of a multiple-gene sequencing panel for hereditary cancer risk assessment. *J Clin Oncol.* 2014;32:2001–2009.
862. Tung N, Battelli C, Allen B, et al. Frequency of mutations in individuals with breast cancer referred for BRCA1 and BRCA2 testing using next-generation sequencing with a 25-gene panel. *Cancer.* 2015;121:25–33.
863. Plon SE, Cooper HP, Parks B, et al. Genetic testing and cancer risk management recommendations by physicians for at-risk relatives. *Genet Med.* 2011;13:148–154.
864. Charkes ND. On the prevalence of familial nonmedullary thyroid cancer in multiply affected kindreds. *Thyroid.* 2006;16:181–186.
865. Nixon JJ, Suárez C, Simo R, et al. The impact of family history on non-medullary thyroid cancer. *Eur J Surg Oncol.* 2016;42:1455–1463.
866. He H, Bronisz A, Liyanarachchi S, et al. SRGAP1 is a candidate gene for papillary thyroid carcinoma susceptibility. *J Clin Endocrinol Metab.* 2013;98:E973–E980.
867. Ngan ES, Lang BH, Liu T, et al. A germline mutation (A339 V) in thyroid transcription factor-1 (TTF-1/NKX2.1) in patients with multinodular goiter and papillary thyroid carcinoma. *J Natl Cancer Inst.* 2009;101:162–175.
868. Pereira JS, da Silva JG, Tomaz RA, et al. Identification of a novel germline FOXE1 variant in patients with familial non-medullary thyroid carcinoma (FNMT). *Endocrine.* 2015;49:204–214.
869. Capezzone M, Cantara S, Marchisotta S, et al. Short telomeres, telomerase reverse transcriptase gene amplification, and increased telomerase activity in the blood of familial papillary thyroid cancer patients. *J Clin Endocrinol Metab.* 2008;93:3950–3957.
870. Liu C, Yu Y, Yin G, et al. C14orf93 (RTFC) is identified as a novel susceptibility gene for familial nonmedullary thyroid cancer. *Biochem Biophys Res Commun.* 2017;482:590–596.
871. Canzian F, Amati P, Harach HR, et al. A gene predisposing to familial thyroid tumors with cell oxyphilia maps to chromosome 19p13.2. *Am J Hum Genet.* 1998;63:1743–1748.
872. McKay JD, Lesueur F, Jonard L, et al. Localization of a susceptibility gene for familial nonmedullary thyroid carcinoma to chromosome 2q21. *Am J Hum Genet.* 2001;69:440–446.
873. Malchoff CD, Sarfarazi M, Tendler B, et al. Papillary thyroid carcinoma associated with papillary renal neoplasia: genetic linkage analysis of a distinct heritable tumor syndrome. *J Clin Endocrinol Metab.* 2000;85:1758–1764.
874. Bignell GR, Canzian F, Shayeghi M, et al. Familial nontoxic multinodular thyroid goiter locus maps to chromosome 14q but does not account for familial nonmedullary thyroid cancer. *Am J Hum Genet.* 1997;61:1123–1130.
875. Cavaco BM, Batista PF, Sobrinho LG, Leite V. Mapping a new familial thyroid epithelial neoplasia susceptibility locus to chromosome 8p23.1-p22 by high-density single-nucleotide polymorphism genome-wide linkage analysis. *J Clin Endocrinol Metab.* 2008;93:4426–4430.
876. Rosario PW, Mineiro Filho AF, Prates BS, Silva LC, Lacerda RX, Calsolari MR. Ultrasonographic screening for thyroid cancer in siblings of patients with apparently sporadic papillary carcinoma. *Thyroid.* 2012;22:805–808.
877. Uchino S, Noguchi S, Yamashita H, et al. Detection of asymptomatic differentiated thyroid carcinoma by neck ultrasonographic screening for familial nonmedullary thyroid carcinoma. *World J Surg.* 2004;28:1099–1102.
878. Maxwell EL, Hall FT, Freeman JL. Familial non-medullary thyroid cancer: a matched-case control study. *Laryngoscope.* 2004;114:2182–2186.
879. Robenshtok E, Tzvetov G, Grozinsky-Glasberg S, et al. Clinical characteristics and outcome of familial nonmedullary thyroid cancer: a retrospective controlled study. *Thyroid.* 2011;21:43–48.
880. Wang X, Cheng W, Li J, et al. Endocrine tumours: familial nonmedullary thyroid carcinoma is a more aggressive disease: a systematic review and meta-analysis. *Eur J Endocrinol.* 2015;172:R253–R262.
881. Hillenbrand A, Varhaug JE, Brauckhoff M, et al. Familial nonmedullary thyroid carcinoma—clinical relevance and prognosis. A European multicenter study. ESES Vienna presentation. *Langenbecks Arch Surg.* 2010;395:851–858.
882. Capezzone M, Marchisotta S, Cantara S, et al. Familial non-medullary thyroid carcinoma displays the features of clinical anticipation suggestive of a distinct biological entity. *Endocr Relat Cancer.* 2008;15:1075–1081.
883. Klubo-Gwiedzinska J, Yang L, Merkel R, et al. Results of screening in familial non-medullary thyroid cancer. *Thyroid.* 2017;27:1017–1024.
884. Bauer AJ. Clinical behavior and genetics of nonsyndromic, familial non-medullary thyroid cancer. *Front Horm Res.* 2013;41:141–148.
885. Perrier ND, van Heerden JA, Goellner JR, et al. Thyroid cancer in patients with familial adenomatous polyposis. *World J Surg.* 1998;22:738–742.
886. Cetta F, Ugolini G, Martellucci J, Gotti G. Screening for thyroid cancer in patients with familial adenomatous polyposis. *Ann Surg.* 2015;261:e13–e14.
887. Jarrar AM, Milas M, Mitchell J, et al. Screening for thyroid cancer in patients with familial adenomatous polyposis. *Ann Surg.* 2011;253:515–521.
888. Herraiz M, Barbesino G, Faquin W J, et al. Prevalence of thyroid cancer in familial adenomatous polyposis syndrome and the role of screening ultrasound examinations. *Clin Gastroenterol Hepatol.* 2007;5:367–373.
889. Bulow S, Holm NV, Mellemegaard A. Papillary thyroid carcinoma in Danish patients with familial adenomatous polyposis. *Int J Colorectal Dis.* 1988;3:29–31.
890. Bulow C, Bulow S. Is screening for thyroid carcinoma indicated in familial adenomatous polyposis? The Leeds Castle Polyposis Group. *Int J Colorectal Dis.* 1997;12:240–242.

891. Plail RO, Bussey HJ, Glazer G, Thomson JP. Adenomatous polyposis: an association with carcinoma of the thyroid. *Br J Surg*. 1987;74:377–380.
892. Giardiello FM, Offerhaus GJ, Lee DH, et al. Increased risk of thyroid and pancreatic carcinoma in familial adenomatous polyposis. *Gut*. 1993;34:1394–1396.
893. Tomoda C, Miyauchi A, Uruno T, et al. Cribriform-morular variant of papillary thyroid carcinoma: clue to early detection of familial adenomatous polyposis-associated colon cancer. *World J Surg*. 2004;28:886–889.
894. Nelen MR, Padberg GW, Peeters EA, et al. Localization of the gene for Cowden disease to chromosome 10q22–23. *Nat Genet*. 1996;13:114–116.
895. Pilarski R, Eng C. Will the real Cowden syndrome please stand up (again)? Expanding mutational and clinical spectra of the PTEN hamartoma tumour syndrome. *J Med Genet*. 2004;41:323–326.
896. Pilarski R, Burt R, Kohlman W, Pho L, Shannon KM, Swisher E. Cowden syndrome and the PTEN hamartoma tumor syndrome: systematic review and revised diagnostic criteria. *J Natl Cancer Inst*. 2013;105:1607–1616.
897. Marsh DJ, Coulon V, Lunetta KL, et al. Mutation spectrum and genotype-phenotype analyses in Cowden disease and Bannayan-Zonana syndrome, two hamartoma syndromes with germline PTEN mutation. *Hum Mol Genet*. 1998;7:507–515.
898. Zhou XP, Waite KA, Pilarski R, et al. Germline PTEN promoter mutations and deletions in Cowden/Bannayan-Riley-Ruvalcaba syndrome result in aberrant PTEN protein and dysregulation of the phosphoinositide-3-kinase/Akt pathway. *Am J Hum Genet*. 2003;73:404–411.
899. Tan MH, Mester J, Peterson C, et al. A clinical scoring system for selection of patients for PTEN mutation testing is proposed on the basis of a prospective study of 3042 probands. *Am J Hum Genet*. 2011;88:42–56.
900. Ngeow J, Mester J, Rybicki LA, Ni Y, Milas M, Eng C. Incidence and clinical characteristics of thyroid cancer in prospective series of individuals with Cowden and Cowden-like syndrome characterized by germline PTEN, SDH, or KLLN alterations. *J Clin Endocrinol Metab*. 2011;96:E2063–E2071.
901. Tan MH, Mester JL, Ngeow J, Rybicki LA, Orloff MS, Eng C. Lifetime cancer risks in individuals with germline PTEN mutations. *Clin Cancer Res*. 2012;18:400–407.
902. Stratakis CA, Kirschner LS, Carney JA. Clinical and molecular features of the Carney complex: diagnostic criteria and recommendations for patient evaluation. *J Clin Endocrinol Metab*. 2001;86:4041–4046.
903. Bertherat J, Horvath A, Groussin L, et al. Mutations in regulatory subunit type 1a of cyclic adenosine 5'-monophosphate-dependent protein kinase (PRKAR1A): phenotype analysis in 353 patients and 80 different genotypes. *J Clin Endocrinol Metabolism*. 2009;94:2085–2091.
904. Stratakis CA, Carney JA, Lin JP, et al. Carney complex, a familial multiple neoplasia and lentiginosis syndrome. Analysis of 11 kindreds and linkage to the short arm of chromosome 2. *J Clin Invest*. 1996;97:699–705.
905. Stratakis CA, Courcoutsakis NA, Abati A, et al. Thyroid gland abnormalities in patients with the syndrome of spotty skin pigmentation, myxomas, endocrine overactivity, and schwannomas (Carney complex). *J Clin Endocrinol Metab*. 1997;82:2037–2043.
906. Yu CE, Oshima J, Fu YH, et al. Positional cloning of the Werner's syndrome gene. *Science*. 1996;272:258–262.
907. Lauper JM, Krause A, Vaughan TL, Monnat RJ Jr. Spectrum and risk of neoplasia in Werner syndrome: a systematic review. *PLoS One*. 2013;8:e59709.
908. Ishikawa Y, Sugano H, Matsumoto T, Furuichi Y, Miller RW, Goto M. Unusual features of thyroid carcinomas in Japanese patients with Werner syndrome and possible genotype-phenotype relations to cell type and race. *Cancer*. 1999;85:1345–1352.
909. Foulkes WD, Priest JR, Duchaine TF. DICER1: mutations, microRNAs and mechanisms. *Nat Rev Cancer*. 2014;14:662–672.
910. de Kock L, Sabbaghian N, Druker H, et al. Germ-line and somatic DICER1 mutations in pineoblastoma. *Acta Neuropathol*. 2014;128:583–595.
911. van Engelen K, Villani A, Wasserman JD, et al. DICER1 syndrome: approach to testing and management at a large pediatric tertiary care center. *Pediatr Blood Cancer*. 2018;65.
912. Rio Frio T, Bahubeshi A, Kanellopoulou C, et al. DICER1 mutations in familial multinodular goiter with and without ovarian Sertoli-Leydig cell tumors. *JAMA*. 2011;305:68–77.
913. Slade I, Bacchelli C, Davies H, et al. DICER1 syndrome: clarifying the diagnosis, clinical features and management implications of a pleiotropic tumour predisposition syndrome. *J Med Genet*. 2011;48:273–278.
914. Rath SR, Bartley A, Charles A, et al. Multinodular goiter in children: an important pointer to a germline DICER1 mutation. *J Clin Endocrinol Metab*. 2014;99:1947–1948.
915. Rutter MM, Jha P, Schultz KA, et al. DICER1 mutations and differentiated thyroid carcinoma: evidence of a direct association. *J Clin Endocrinol Metab*. 2016;101:1–5.
916. Boyce AM and Collins MT. Fibrous Dysplasia/McCune-Albright Syndrome. In: *GeneReviews(R)*, Pagon RA, et al, eds. Seattle, WA: University of Washington, 1993.
917. Siolek M, Siolek M, Cybulski C, Gasior-Perczak D, et al. CHEK2 mutations and the risk of papillary thyroid cancer. *Int J Cancer*. 2015;137:548–552.
918. Verdy M, Weber AM, Roy CC, Morin CL, Cadotte M, Brochu P. Hirschsprung's disease in a family with multiple endocrine neoplasia type 2. *J Pediatr Gastroenterol Nutr*. 1982;1:603–607.
919. Decker RA, Peacock ML. Occurrence of MEN 2a in familial Hirschsprung's disease: a new indication for genetic testing of the RET proto-oncogene. *J Pediatr Surg*. 1998;33:207–214.
920. Sijmons RH, Hofstra RM, Wijburg FA, et al. Oncological implications of RET gene mutations in Hirschsprung's disease. *Gut*. 1998;43:542–547.
921. Brauckhoff M, Machens A, Hess S, et al. Premonitory symptoms preceding metastatic medullary thyroid cancer in MEN 2B: an exploratory analysis. *Surgery*. 2008;144:1044–1050.
922. Wray CJ, Rich TA, Waguespack SG, Lee JE, Perrier ND, Evans DB. Failure to recognize multiple endocrine neoplasia 2B: more common than we think? *Ann Surg Oncol*. 2008;15:293–301.
923. Elisei R, Romei C, Cosci B, et al. RET genetic screening in patients with medullary thyroid cancer and their relatives: experience with 807 individuals at one center. *J Clin Endocrinol Metab*. 2007;92:4725–4729.
924. Eng C, Mulligan LM, Smith DP, et al. Low frequency of germline mutations in the RET proto-oncogene in patients with apparently sporadic medullary thyroid carcinoma. *Clin Endocrinol (Oxf)*. 1995;43:123–127.
925. Xu JY, Grubbs EG, Waguespack SG, et al. Medullary Thyroid carcinoma associated with germline RETK666N mutation. *Thyroid*. 2016;26:1744–1751.
926. Long KL, Etzel C, Rich T, et al. All in the family? Analyzing the impact of family history in addition to genotype on medullary thyroid carcinoma aggressiveness in MEN2A patients. *Fam Cancer*. 2017;16:283–289.
927. Verhaert N, Vander Poorten V, Delaere P, Bex M, Debruyne F. Levothyroxine replacement therapy after thyroid surgery. *B-ENT*. 2006;2:129–133.
928. Said M, Chiu V, Haigh PI. Hypothyroidism after hemithyroidectomy. *World J Surg*. 2013;37:2839–2844.
929. McHenry CR, Slusarczyk SJ. Hypothyroidism following hemithyroidectomy: incidence, risk factors, and management. *Surgery*. 2000;128:994–998.
930. Park S, Jeon MJ, Song E, et al. Clinical features of early and late postoperative hypothyroidism after lobectomy. *J Clin Endocrinol Metab*. 2017;102:1317–1324.
931. Haymart MR, Glinberg SL, Liu J, Sippel RS, Jaume JC, Chen H. Higher serum TSH in thyroid cancer patients occurs independent of age and correlates with extrathyroidal extension. *Clin Endocrinol (Oxf)*. 2009;71:434–439.
932. Chambers AJ, Pasiaka JL, Temple WJ. Improvement in the accuracy of reporting key prognostic and anatomic findings during thyroidectomy by using a novel Web-based synoptic operative reporting system. *Surgery*. 2009;146:1090–1098.
933. Iyer NG, Nixon IJ, Palmer F, Ganly I, Patel SG, Shaha AR. Electronic synoptic operative reporting for thyroid surgery using an electronic data management system: potential for prospective multicenter data collection. *Ann Surg Oncol*. 2011;18:762–766.
934. McLaughlin EJ, Brant JA, Bur AM, et al. Safety of outpatient thyroidectomy: review of the American College of Surgeons National Surgical Quality Improvement Program. *Laryngoscope*. 2018;40:192–202.
935. Lee DJ, Chin CJ, Hong CJ, Perera S, Witterick IJ. Outpatient versus inpatient thyroidectomy: a systematic review and meta-analysis. *Head Neck*. 2018;40:192–202.
936. Snyder SK, Hamid KS, Roberson CR, et al. Outpatient thyroidectomy is safe and reasonable: experience with more than 1,000 planned outpatient procedures. *J Am Coll Surg*. 2010;210:575–582. 582–4.
937. Tuggle CT, Roman S, Udelsman R, Sosa JA. Same-day thyroidectomy: a review of practice patterns and outcomes for 1,168 procedures in New York State. *Ann Surg Oncol*. 2011;18:1035–1040.
938. Jackson BA, Shelton AJ. Pilot study evaluating topical onion extract as treatment for postsurgical scars. *Dermatol Surg*. 1999;25:267–269.
939. Baumann LS, Spencer J. The effects of topical vitamin E on the cosmetic appearance of scars. *Dermatol Surg*. 1999;25:311–315.
940. Chung VQ, Kelley L, Marra D, Jiang SB. Onion extract gel versus petrolatum emollient on new surgical scars: prospective double-blinded study. *Dermatol Surg*. 2006;32:193–197.

941. Morganroth P, Wilmot AC, Miller C. JAAD online. Over-the-counter scar products for postsurgical patients: disparities between online advertised benefits and evidence regarding efficacy. *J Am Acad Dermatol*. 2009;61:e31–e47.
942. Di Donna V, Santoro MG, de Waure C, et al. A new strategy to estimate levothyroxine requirement after total thyroidectomy for benign thyroid disease. *Thyroid*. 2014;24:1759–1764.
943. Sawin CT, Geller A, Wolf PA, et al. Low serum thyrotropin concentrations as a risk factor for atrial fibrillation in older persons. *N Engl J Med*. 1994;331:1249–1252.
944. Kim MK, Yun KJ, Kim MH, et al. The effects of thyrotropin-suppressing therapy on bone metabolism in patients with well-differentiated thyroid carcinoma. *Bone*. 2015;71:101–105.
945. Dowell D, Haegerich TM. Using the CDC guideline and tools for opioid prescribing in patients with chronic pain. *Am Fam Physician*. 2016;93:970–972.
946. Brummett CM, Waljee JF, Goesling J, et al. New persistent opioid use after minor and major surgical procedures in US adults. *JAMA Surg*. 2017;152:e170504.
947. Howard R, Fry B, Gunaseelan V, et al. Association of opioid prescribing with opioid consumption after surgery in Michigan. *JAMA Surg*. 2019;154:e184234.
948. Tharakan T, Jiang S, Fastenberg J, et al. Postoperative pain control and opioid usage patterns among patients undergoing thyroidectomy and parathyroidectomy. *Otolaryngol Head Neck Surg*. 2019;160:394–401.
949. Shindo M, Lim J, Leon E, Moneta L, Li R, Quintanilla-Dieck L. Opioid prescribing practice and needs in thyroid and parathyroid surgery. *JAMA Otolaryngol Head Neck Surg*. 2018;144:1098–1103.
950. Mutlu V, Ince I. Preemptive intravenous ibuprofen application reduces pain and opioid consumption following thyroid surgery. *Am J Otolaryngol*. 2019;40:70–73.
951. Lou I, Chennell TB, Schaefer SC, et al. Optimizing outpatient pain management after thyroid and parathyroid surgery: a two-institution experience. *Ann Surg Oncol*. 2017;24:1951–1957.
952. Dehal A, Abbas A, Hussain F, Johna S. Risk factors for neck hematoma after thyroid or parathyroid surgery: ten-year analysis of the nationwide inpatient sample database. *Perm J*. 2015;19:22–28.
953. Dehal A, Al-temimi MH, Abbas AM, et al. Impact of surgeon volume on incidence of neck hematoma after thyroid and parathyroid surgery: ten years' analysis of nationwide in-patient sample database. *Am Surg*. 2014;80:948–952.
954. Rosato L, Avenia N, Bernante P, et al. Complications of thyroid surgery: analysis of a multicentric study on 14,934 patients operated on in Italy over 5 years. *World J Surg*. 2004;28:271–276.
955. Weiss A, Lee KC, Brumund KT, Chang DC, Bouvet M. Risk factors for hematoma after thyroidectomy: results from the nationwide inpatient sample. *Surgery*. 2014;156:399–404.
956. Liu J, Li Z, Liu S, Wang X, Xu Z, Tang P. Risk factors for and occurrence of postoperative cervical hematoma after thyroid surgery: a single-institution study based on 5156 cases from the past 2 years. *Head Neck*. 2016;38:216–219.
957. Milone M, Musella M, Conzo G, et al. Thyroidectomy in high body mass index patients: A single center experience. *Int J Surg*. 2016;28(suppl 1):S38–S41.
958. Finel JB, Mucci S, Branger F, et al. Thyroidectomy in patients with a high BMI: a safe surgery? *Eur J Endocrinol*. 2014;171:99–105.
959. Shaha AR, Jaffe BM. Practical management of post-thyroidectomy hematoma. *J Surg Oncol*. 1994;57:235–238.
960. Chiang FY, Wang LF, Huang YF, Lee KW, Kuo WR. Recurrent laryngeal nerve palsy after thyroidectomy with routine identification of the recurrent laryngeal nerve. *Surgery*. 2005;137:342–347.
961. Müller PE, Jakoby R, Heinert G, Spelsberg F. Surgery for recurrent goitre: its complications and their risk factors. *Eur J Surg*. 2001;167:816–821.
962. More Y, Shnyder Y, Girod DA, et al. Factors influencing morbidity after surgical management of malignant thyroid disease. *Ann Otol Rhinol Laryngol*. 2013;122:398–403.
963. Randolph GW, Shin JJ, Grillo HC, et al. The surgical management of goiter: Part II. Surgical treatment and results. *Laryngoscope*. 2011;121:68–76.
964. Zambudio AR, Rodríguez J, Riquelme J, Soria T, Canteras M, Parrilla P. Prospective study of postoperative complications after total thyroidectomy for multinodular goiters by surgeons with experience in endocrine surgery. *Ann Surg*. 2004;240:18–25.
965. Qiao N, Wu LF, Gao W, et al. Anatomic characteristics, identification, and protection of the nonrecurrent laryngeal nerve during thyroidectomy. *Otolaryngol Head Neck Surg*. 2017;157:210–216.
966. Dzodic R, Markovic I, Santrac N, et al. Recurrent laryngeal nerve liberations and reconstructions: a single institution experience. *World J Surg*. 2016;40:644–651.
967. Lee SW, Park KN, Oh SK, Jung CH, Mok JO, Kim CH. Long-term efficacy of primary intraoperative recurrent laryngeal nerve reinnervation in the management of thyroidectomy-related unilateral vocal fold paralysis. *Acta Otolaryngol*. 2014;134:1179–1184.
968. Hong JW, Roh TS, Yoo HS, et al. Outcome with immediate direct anastomosis of recurrent laryngeal nerves injured during thyroidectomy. *Laryngoscope*. 2014;124:1402–1408.
969. Miyachi A, Inoue H, Tomoda C, et al. Improvement in phonation after reconstruction of the recurrent laryngeal nerve in patients with thyroid cancer invading the nerve. *Surgery*. 2009;146:1056–1062.
970. Hydman J, Björck G, Persson JK, Zedenius J, Mattsson P. Diagnosis and prognosis of iatrogenic injury of the recurrent laryngeal nerve. *Ann Otol Rhinol Laryngol*. 2009;118:506–511.
971. Orloff LA, Wiseman SM, Bernet VJ, et al. American Thyroid Association Statement on postoperative hypoparathyroidism: diagnosis, prevention, and management in adults. *Thyroid*. 2018;28:830–841.
972. Arer IM, Kus M, Akkapulu N, et al. Prophylactic oral calcium supplementation therapy to prevent early post thyroidectomy hypocalcemia and evaluation of postoperative parathyroid hormone levels to detect hypocalcemia: A prospective randomized study. *Int J Surg*. 2017;38:9–14.
973. Sabour S, Manders E, Steward DL. The role of rapid PACU parathyroid hormone in reducing post-thyroidectomy hypocalcemia. *Otolaryngol Head Neck Surg*. 2009;141:727–729.
974. Wiseman JE, Mossanen M, Ituarte PH, Bath JM, Yeh MW. An algorithm informed by the parathyroid hormone level reduces hypocalcemic complications of thyroidectomy. *World J Surg*. 2010;34:532–537.
975. Demeester-Mirkine N, Hooghe L, Van Geertruyden J, De Maertelaer V. Hypocalcemia after thyroidectomy. *Arch Surg*. 1992;127:854–858.
976. Thomusch O, Machens A, Sekulla C, Ukkat J, Brauckhoff M, Dralle H. The impact of surgical technique on postoperative hypoparathyroidism in bilateral thyroid surgery: a multivariate analysis of 5846 consecutive patients. *Surgery*. 2003;133:180–185.
977. McHenry CR, Speroff T, Wentworth D, Murphy T. Risk factors for postthyroidectomy hypocalcemia. *Surgery*. 1994;116:641–647.
978. Cho JN, Park WS, Min SY. Predictors and risk factors of hypoparathyroidism after total thyroidectomy. *Int J Surg*. 2016;34:47–52.
979. Asari R, Passler C, Kaczirek K, Scheuba C, Niederle B. Hypoparathyroidism after total thyroidectomy: a prospective study. *Arch Surg*. 2008;143:132–137.
980. Docimo G, Ruggiero R, Casalino G, Del Genio G, Docimo L, Tolone S. Risk factors for postoperative hypocalcemia. *Updates Surg*. 2017;69:255–260.
981. Giordano D, Valcavi R, Thompson GB, et al. Complications of central neck dissection in patients with papillary thyroid carcinoma: results of a study on 1087 patients and review of the literature. *Thyroid*. 2012;22:911–917.
982. Stack BC Jr, Bimston DN, Bodenner DL, et al. American Association of Clinical Endocrinologists and American College of endocrinology disease state clinical review: postoperative hypoparathyroidism—definitions and management. *Endocr Pract*. 2015;21:674–685.
983. Diaz-Soto G, Mora-Porta M, Nicolau J, Perea V, Halperin I, Puig-Domingo M. Efficacy and safety of long term treatment of unresponsive hypoparathyroidism using multipulse subcutaneous infusion of teriparatide. *Horm Metab Res*. 2012;44:708–710.
984. Shah M, Bancos I, Thompson GB, et al. Teriparatide Therapy and reduced postoperative hospitalization for postsurgical hypoparathyroidism. *JAMA Otolaryngol Head Neck Surg*. 2015;141:822–827.
985. Bures C, Klatt T, Gilhofer M, et al. A prospective study on surgical-site infections in thyroid operation. *Surgery*. 2014;155:675–681.
986. Gosnell JE, Campbell P, Sidhu S, Sywak M, Reeve TS, Delbridge LW. Inadvertent tracheal perforation during thyroidectomy. *Br J Surg*. 2006;93:55–56.
987. Ozer MT, Demirbas S, Harlak A, Ersoz N, Eryilmaz M, Cetiner S. A rare complication after thyroidectomy: perforation of the oesophagus: a case report. *Acta Chir Belg*. 2009;109:527–530.
988. Lee SW, Cho SH, Lee JD, Lee JY, Kim SC, Koh YW. Bilateral pneumothorax and pneumomediastinum following total thyroidectomy with central neck dissection. *Clin Exp Otorhinolaryngol*. 2008;1:49–51.

989. Koeppen M, Scott B, Morabito J, Fiegel M, Eckle T. Pneumomediastinum and bilateral pneumothoraces causing respiratory failure after thyroid surgery. *Case Rep Anesthesiol*. 2017;2017:8206970.
990. Ito Y, Miyauchi A, Inoue H, et al. An observational trial for papillary thyroid microcarcinoma in Japanese patients. *World J Surg*. 2010;34:28–35.
991. Ito Y, Miyauchi A, Kihara M, Higashiyama T, Kobayashi K, Miya A. Patient age is significantly related to the progression of papillary microcarcinoma of the thyroid under observation. *Thyroid*. 2014;24:27–34.
992. Fukuoka O, Sugitani I, Ebina A, Toda K, Kawabata K, Yamada K. Natural history of asymptomatic papillary thyroid microcarcinoma: time-dependent changes in calcification and vascularity during active surveillance. *World J Surg*. 2016;40:529–537.
993. Ito Y, Miyauchi A, Oda H. Low-risk papillary microcarcinoma of the thyroid: a review of active surveillance trials. *Eur J Surg Oncol*. 2018;44:307–315.
994. Oh HS, Ha J, Kim HI, et al. Active surveillance of low-risk papillary thyroid microcarcinoma: a multi-center cohort study in Korea. *Thyroid*. 2018;28:1587–1594.
995. Tuttle RM, Fagin JA, Minkowitz G, et al. Natural history and tumor volume kinetics of papillary thyroid cancers during active surveillance. *JAMA Otolaryngol Head Neck Surg*. 2017;143:1015–1020.
996. Brito JP, Ito Y, Miyauchi A, Tuttle RM. A clinical framework to facilitate risk stratification when considering an active surveillance alternative to immediate biopsy and surgery in papillary microcarcinoma. *Thyroid*. 2016;26:144–149.
997. Venkatesh S, Pasternak JD, Beninato T, et al. Cost-effectiveness of active surveillance versus hemithyroidectomy for micropapillary thyroid cancer. *Surgery*. 2017;161:116–126.
998. Lang BH, Lo CY, Chan WF, Lam KY, Wan KY. Staging systems for papillary thyroid carcinoma: a review and comparison. *Ann Surg*. 2007;245:366–378.
999. Tuttle RM, Morris LF, Haugen B, et al, eds. *AJCC cancer staging manual*. New York: Springer International Publishing, 2017.
1000. Pontius LN, Oyekunle TO, Thomas SM, et al. Projecting survival in papillary thyroid cancer: a comparison of the Seventh and Eighth Editions of the American Joint Commission on Cancer/Union for International Cancer Control Staging Systems in Two Contemporary National Patient Cohorts. *Thyroid*. 2017;27:1408–1416.
1001. Adam MA, Thomas S, Roman SA, Hyslop T, Sosa JA. Rethinking the current American Joint Committee on cancer TNM staging system for medullary thyroid cancer. *JAMA Surg*. 2017;152:869–876.
1002. Cooper DS, Doherty GM, Haugen BR, et al. Management guidelines for patients with thyroid nodules and differentiated thyroid cancer. *Thyroid*. 2006;16:109–142.
1003. American Thyroid Association Guidelines Taskforce on Thyroid, N, et al. Revised American Thyroid Association management guidelines for patients with thyroid nodules and differentiated thyroid cancer. *Thyroid*. 2009;19:1167–1214.
1004. Lee SG, Lee WK, Lee HS, et al. Practical Performance of the 2015 American Thyroid Association Guidelines for Predicting Tumor Recurrence in Patients with Papillary Thyroid Cancer in South Korea. *Thyroid*. 2017;27:174–181.
1005. Hodak S, Tuttle RM, Maytal G, Nikiforov YE, Randolph G. Changing the cancer diagnosis: the case of follicular variant of papillary thyroid cancer-primum non Nocere and NIFTP. *Thyroid*. 2016;26:869–871.
1006. Xu B, Tallini G, Scognamiglio T, et al. Outcome of large noninvasive follicular thyroid neoplasm with papillary-like nuclear features. *Thyroid*. 2017;27:512–517.
1007. Bongiovanni M, Mermod M, Canberk S, et al. Columnar cell variant of papillary thyroid carcinoma: Cytomorphological characteristics of 11 cases with histological correlation and literature review. *Cancer*. 2017;125:389–397.
1008. Gupta S, Ajise O, Dultz L, et al. Follicular variant of papillary thyroid cancer: encapsulated, nonencapsulated, and diffuse: distinct biologic and clinical entities. *Arch Otolaryngol Head Neck Surg*. 2012;138:227–233.
1009. Shi X, Liu R, Basolo F, et al. Differential clinicopathological risk and prognosis of major papillary thyroid cancer variants. *J Clin Endocrinol Metab*. 2016;101:264–274.
1010. Yu XM, Schneider DF, Levenson G, Chen H, Sippel RS. Follicular variant of papillary thyroid carcinoma is a unique clinical entity: a population-based study of 10,740 cases. *Thyroid*. 2013;23:1263–1268.
1011. Pezzi TA, Sandulache VC, Pezzi CM, et al. Treatment and survival of patients with insular thyroid carcinoma: 508 cases from the National Cancer Data Base. *Head Neck*. 2016;38:906–912.
1012. Kazaure HS, Roman SA, Sosa JA. Aggressive variants of papillary thyroid cancer: incidence, characteristics and predictors of survival among 43,738 patients. *Ann Surg Oncol*. 2012;19:1874–1880.
1013. DeLellis R, Lloyd RV, Heitz PU, Eng C. *WHO/IARC Classification of Tumours*. 3rd ed. Vol. 8. Lyon: IARC Press; 2004.
1014. Liu C, Chen T, Liu Z. Associations between BRAF(V600E) and prognostic factors and poor outcomes in papillary thyroid carcinoma: a meta-analysis. *World J Surg Oncol*. 2016;14:241.
1015. Prescott JD, Sadow PM, Hodin RA, et al. BRAF V600E status adds incremental value to current risk classification systems in predicting papillary thyroid carcinoma recurrence. *Surgery*. 2012;152:984–990.
1016. Niederer-Wüst SM, Jochum W, Förbs D, et al. Impact of clinical risk scores and BRAF V600E mutation status on outcome in papillary thyroid cancer. *Surgery*. 2015;157:119–125.
1017. Song YS, Lim JA, Choi H, et al. Prognostic effects of TERT promoter mutations are enhanced by coexistence with BRAF or RAS mutations and strengthen the risk prediction by the ATA or TNM staging system in differentiated thyroid cancer patients. *Cancer*. 2016;122:1370–1379.
1018. Bullock M, Ren Y, O'Neill C, et al. TERT promoter mutations are a major indicator of recurrence and death due to papillary thyroid carcinomas. *Clin Endocrinol (Oxf)*. 2016;85:283–290.
1019. Nicolson NG, Murtha TD, Dong W, et al. Comprehensive genetic analysis of follicular thyroid carcinoma predicts prognosis independent of histology. *J Clin Endocrinol Metab*. 2018;103:2640–2650.
1020. Aragon Han P, Weng CH, Khawaja HT, et al. MicroRNA expression and association with clinicopathologic features in papillary thyroid cancer: a systematic review. *Thyroid*. 2015;25:1322–1329.
1021. Lang BH, Shek TW, Wan KY. The significance of unrecognized histological high-risk features on response to therapy in papillary thyroid carcinoma measuring 1–4 cm: implications for completion thyroidectomy following lobectomy. *Clin Endocrinol (Oxf)*. 2017;86:236–242.
1022. Jonklaas J, Sarlis NJ, Litofsky D, et al. Outcomes of patients with differentiated thyroid carcinoma following initial therapy. *Thyroid*. 2006;16:1229–1242.
1023. Yang Z, Flores J, Katz S, Nathan CA, Mehta V. Comparison of survival outcomes following postsurgical radioactive iodine versus external beam radiation in Stage IV differentiated thyroid carcinoma. *Thyroid*. 2017;27:944–952.
1024. Fussey JM, Crunkhorn R, Tedla M, Weickert MO, Mehanna H. External beam radiotherapy in differentiated thyroid carcinoma: a systematic review. *Head Neck*. 2016;38(suppl 1):E2297–E2305.
1025. Brierley J, Tsang R, Simpson WJ, Gospodarowicz M, Sutcliffe S, Panzarella T. Medullary thyroid cancer: analyses of survival and prognostic factors and the role of radiation therapy in local control. *Thyroid*. 1996;6:305–310.
1026. Martinez SR, Beal SH, Chen A, Chen SL, Schneider PD. Adjuvant external beam radiation for medullary thyroid carcinoma. *J Surg Oncol*. 2010;102:175–178.
1027. Goffredo P, Robinson TJ, Youngwirth LM, Roman SA, Sosa JA. Intensity-modulated radiation therapy use for the localized treatment of thyroid cancer: Nationwide practice patterns and outcomes. *Endocrine*. 2016;53:761–773.
1028. Urbano TG, Clark CH, Hansen VN, et al. Intensity Modulated Radiotherapy (IMRT) in locally advanced thyroid cancer: acute toxicity results of a phase I study. *Radiother Oncol*. 2007;85:58–63.
1029. Schwartz DL, Lobo MJ, Ang KK, et al. Postoperative external beam radiotherapy for differentiated thyroid cancer: outcomes and morbidity with conformal treatment. *Int J Radiat Oncol Biol Phys*. 2009;74:1083–1091.
1030. Subbiah V, Kreitman RJ, Wainberg ZA, et al. Dabrafenib and trametinib treatment in patients with locally advanced or metastatic BRAF V600-Mutant Anaplastic Thyroid Cancer. *J Clin Oncol*. 2018;36:7–13.
1031. Ferrell BR, Temel JS, Temin S, et al. Integration of palliative care into standard oncology care: American Society of Clinical Oncology Clinical Practice Guideline Update. *J Clin Oncol*. 2017;35:96–112.
1032. Rössing RM, Jentzen W, Nagarajah J, Bockisch A, Görge R. Serum thyroglobulin doubling time in progressive thyroid cancer. *Thyroid*. 2016;26:1712–1718.
1033. Giovannella L, Trimboli P, Verburg FA, et al. Thyroglobulin levels and thyroglobulin doubling time independently predict a positive 18F-FDG PET/CT scan in patients with biochemical recurrence of differentiated thyroid carcinoma. *Eur J Nucl Med Mol Imaging*. 2013;40:874–880.
1034. Miyauchi A, Kudo T, Miya A, et al. Prognostic impact of serum thyroglobulin doubling-time under thyrotropin suppression in patients with papillary thyroid carcinoma who underwent total thyroidectomy. *Thyroid*. 2011;21:707–716.



1035. Mazzaferri EL, Jhiang SM. Long-term impact of initial surgical and medical therapy on papillary and follicular thyroid cancer. *Am J Med.* 1994;97:418–428.
1036. Park S, Kim WG, Song E, et al. Dynamic risk stratification for predicting recurrence in patients with differentiated thyroid cancer treated without radioactive iodine remnant ablation therapy. *Thyroid.* 2017;27:524–530.
1037. Rondeau G, Fish S, Hann LE, Fagin JA, Tuttle RM. Ultrasonographically detected small thyroid bed nodules identified after total thyroidectomy for differentiated thyroid cancer seldom show clinically significant structural progression. *Thyroid.* 2011;21:845–853.
1038. Urken ML, Milas M, Randolph GW, et al. Management of recurrent and persistent metastatic lymph nodes in well-differentiated thyroid cancer: a multifactorial decision-making guide for the Thyroid Cancer Care Collaborative. *Head Neck.* 2015;37:605–614.
1039. Kebebew E, Ituarte PH, Siperstein AE, Duh QY, Clark OH. Medullary thyroid carcinoma: clinical characteristics, treatment, prognostic factors, and a comparison of staging systems. *Cancer.* 2000;88:1139–1148.
1040. Ríos A, Rodríguez JM, Acosta JM, et al. Prognostic value of histological and immunohistochemical characteristics for predicting the recurrence of medullary thyroid carcinoma. *Ann Surg Oncol.* 2010;17:2444–2451.
1041. Kuo EJ, Sho S, Li N, Zanocco KA, Yeh MW, Livhits MJ. Risk factors associated with reoperation and disease-specific mortality in patients with medullary thyroid carcinoma. *JAMA Surg.* 2018;153:52–59.
1042. Laure Giraudet A, Al Ghulzan A, Aupérin A, et al. Progression of medullary thyroid carcinoma: assessment with calcitonin and carcinoembryonic antigen doubling times. *Eur J Endocrinol.* 2008;158:239–246.
1043. Gawlik T, d'Amico A, Szpak-Ulcok S, et al. The prognostic value of tumor markers doubling times in medullary thyroid carcinoma: preliminary report. *Thyroid Res.* 2010;3:10.
1044. Miccoli P, Frustaci G, Fosso A, Miccoli M, Materazzi G. Surgery for recurrent goiter: complication rate and role of the thyroid-stimulating hormone-suppressive therapy after the first operation. *Langenbecks Arch Surg.* 2015;400:253–258.
1045. Tan YY, Kebebew E, Reiff E, et al. Does routine consultation of thyroid fine-needle aspiration cytology change surgical management? *J Am Coll Surg.* 2007;205:8–12.
1046. McCoy KL, Yim JH, Tublin ME, Burmeister LA, Ogilvie JB, Carty SE. Same-day ultrasound guidance in reoperation for locally recurrent papillary thyroid cancer. *Surgery.* 2007;142:965–972.
1047. Stulak JM, Grant CS, Farley DR, et al. Value of preoperative ultrasonography in the surgical management of initial and reoperative papillary thyroid cancer. *Arch Surg.* 2006;141:489–494.
1048. Lesnik D, Cunnane ME, Zurakowski D, et al. Papillary thyroid carcinoma nodal surgery directed by a preoperative radiographic map utilizing CT scan and ultrasound in all primary and reoperative patients. *Head Neck.* 2014;36:191–202.
1049. Mihailovic J, Prvulovic M, Ivkovic M, Markoski B, Martinov D. MRI versus (1)(3)(1)I whole-body scintigraphy for the detection of lymph node recurrences in differentiated thyroid carcinoma. *AJR Am J Roentgenol.* 2010;195:1197–1203.
1050. Nascimento C, Borget I, Al Ghulzan A, et al. Postoperative fluorine-18-fluorodeoxyglucose positron emission tomography/computed tomography: an important imaging modality in patients with aggressive histology of differentiated thyroid cancer. *Thyroid.* 2015;25:437–444.
1051. Lefevre JH, Tresallet C, Leenhardt L, Jublanc C, Chigot JP, Menegaux F. Reoperative surgery for thyroid disease. *Langenbecks Arch Surg.* 2007;392:685–691.
1052. Farrag TY, Agrawal N, Sheth S, et al. Algorithm for safe and effective reoperative thyroid bed surgery for recurrent/persistent papillary thyroid carcinoma. *Head Neck.* 2007;29:1069–1074.
1053. Schuff KG, Weber SM, Givi B, Samuels MH, Andersen PE, Cohen JJ. Efficacy of nodal dissection for treatment of persistent/recurrent papillary thyroid cancer. *Laryngoscope.* 2008;118:768–775.
1054. Ondik MP, Dezfoli S, Lipinski L, Ruggiero F, Goldenberg D. Secondary central compartment surgery for thyroid cancer. *Laryngoscope.* 2009;119:1947–1950.
1055. Roh JL, Kim JM, Park CI. Central compartment reoperation for recurrent/persistent differentiated thyroid cancer: patterns of recurrence, morbidity, and prediction of postoperative hypocalcemia. *Ann Surg Oncol.* 2011;18:1312–1318.
1056. Shah MD, Harris LD, Nassif RG, et al. Efficacy and safety of central compartment neck dissection for recurrent thyroid carcinoma. *Arch Otolaryngol Head Neck Surg.* 2012;138:33–37.
1057. Ondik MP, McGinn J, Ruggiero F, Goldenberg D. Unintentional parathyroidectomy and hypoparathyroidism in secondary central compartment surgery for thyroid cancer. *Head Neck.* 2010;32:462–466.
1058. Lamartina L, Borget I, Mirghani H, et al. Surgery for neck recurrence of differentiated thyroid cancer: outcomes and risk factors. *J Clin Endocrinol Metab.* 2017;102:1020–1031.
1059. Onkendi EO, McKenzie TJ, Richards ML, et al. Reoperative experience with papillary thyroid cancer. *World J Surg.* 2014;38:645–652.
1060. Tufano RP, Bishop J, Wu G. Reoperative central compartment dissection for patients with recurrent/persistent papillary thyroid cancer: efficacy, safety, and the association of the BRAF mutation. *Laryngoscope.* 2012;122:1634–1640.
1061. Sturgeon C, Corvera C, Clark OH. The missing thyroid. *J Am Coll Surg.* 2005;201:841–846.
1062. Bates MF, Lamas MR, Randle RW, et al. Back so soon? Is early recurrence of papillary thyroid cancer really just persistent disease? *Surgery.* 2018;163:118–123.
1063. Salari B, Ren Y, Kamani D, Randolph GW. Revision neural monitored surgery for recurrent thyroid cancer: safety and thyroglobulin response. *Laryngoscope.* 2016;126:1020–1025.
1064. Chuang YC, Huang SM. Protective effect of intraoperative nerve monitoring against recurrent laryngeal nerve injury during re-exploration of the thyroid. *World J Surg Oncol.* 2013;11:94.
1065. Barczyński M, Konturek A, Pragacz K, Papier A, Stopa M, Nowak W. Intraoperative nerve monitoring can reduce prevalence of recurrent laryngeal nerve injury in thyroid reoperations: results of a retrospective cohort study. *World J Surg.* 2014;38:599–606.
1066. Gardner JW. *Self-Renewal; the Individual and the Innovative Society.* 1st ed. New York: Harper & Row; 1964. xvi, 141 p.

## APPENDIX A

In the construction of these guidelines, all authors disclosed all potential COI at the start of the project and every 6 months thereafter. Conflict of Interest (COI) was defined to be present when the author or a related party had a relevant financial relationship with a financially interested entity during any portion of the writing process or within 36 months prior. In each case, the nature of the financial relationship (such as consultant fees, honoraria, research support, employment, salaries, and gifts) and the dollar amount was documented, including but not limited to:

1. Performance of any work for the sponsor or any commercial entity with a product or class of products discussed in the manuscript (eg, Pharmaceutical Company, Medical Supply Company, etc.)
2. Compensated or uncompensated service for any commercial entity related to or involved with the content and material, which includes gifts, salaries, honoraria, or consulting fees.
3. Owning stocks, stock options, or other forms of ownership in the sponsor or in any commercial entity that would appear to affect the conduct or outcome of the text.